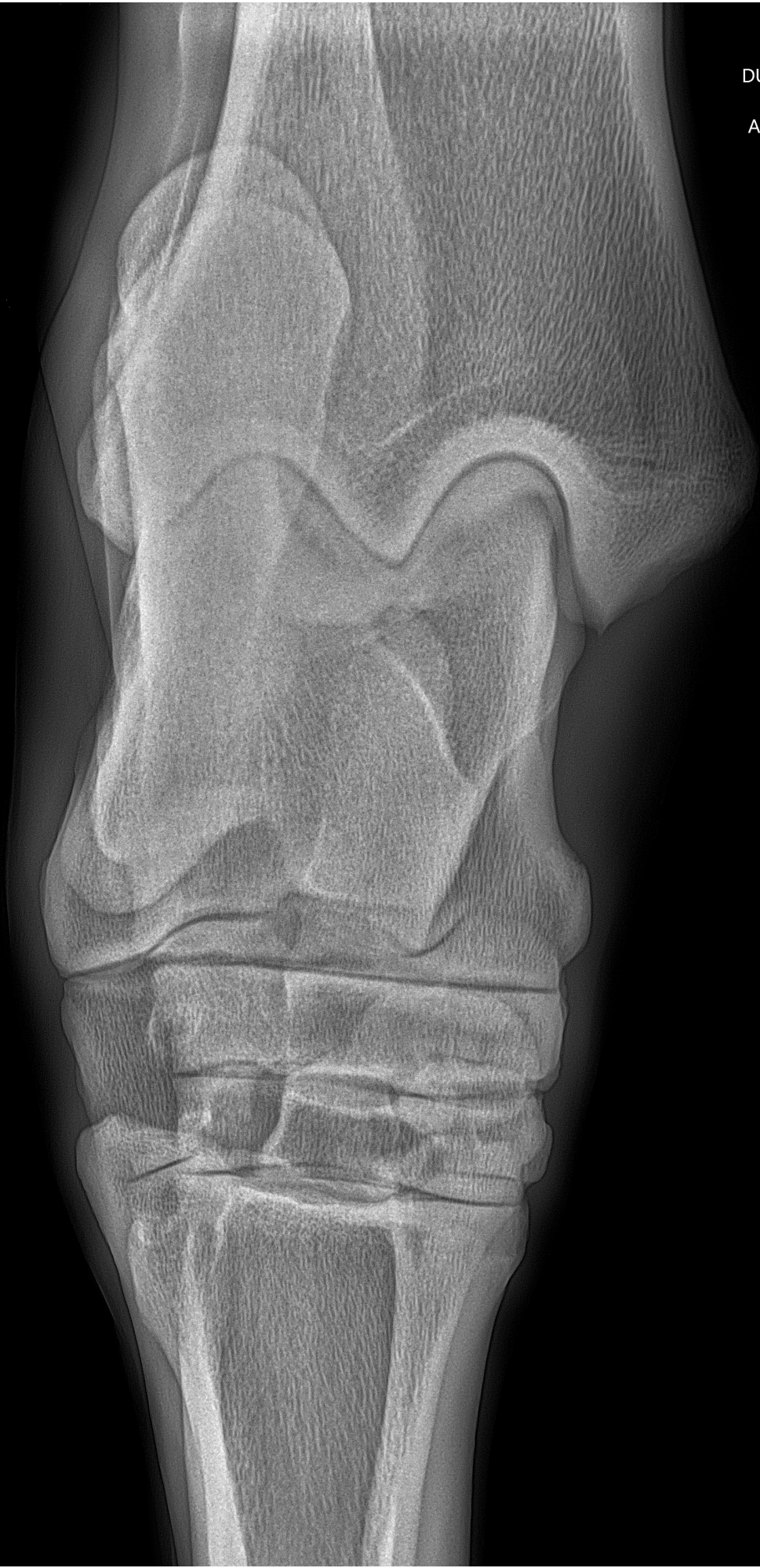

MC vet  
Anatomy: Tarse  
View: DP  
Lat: PD

Vet Rec:  
DULAC, KAPRICE HG  
Cheval  
Acq Dt: 30/03/2026  
Acq Tm: 14:06

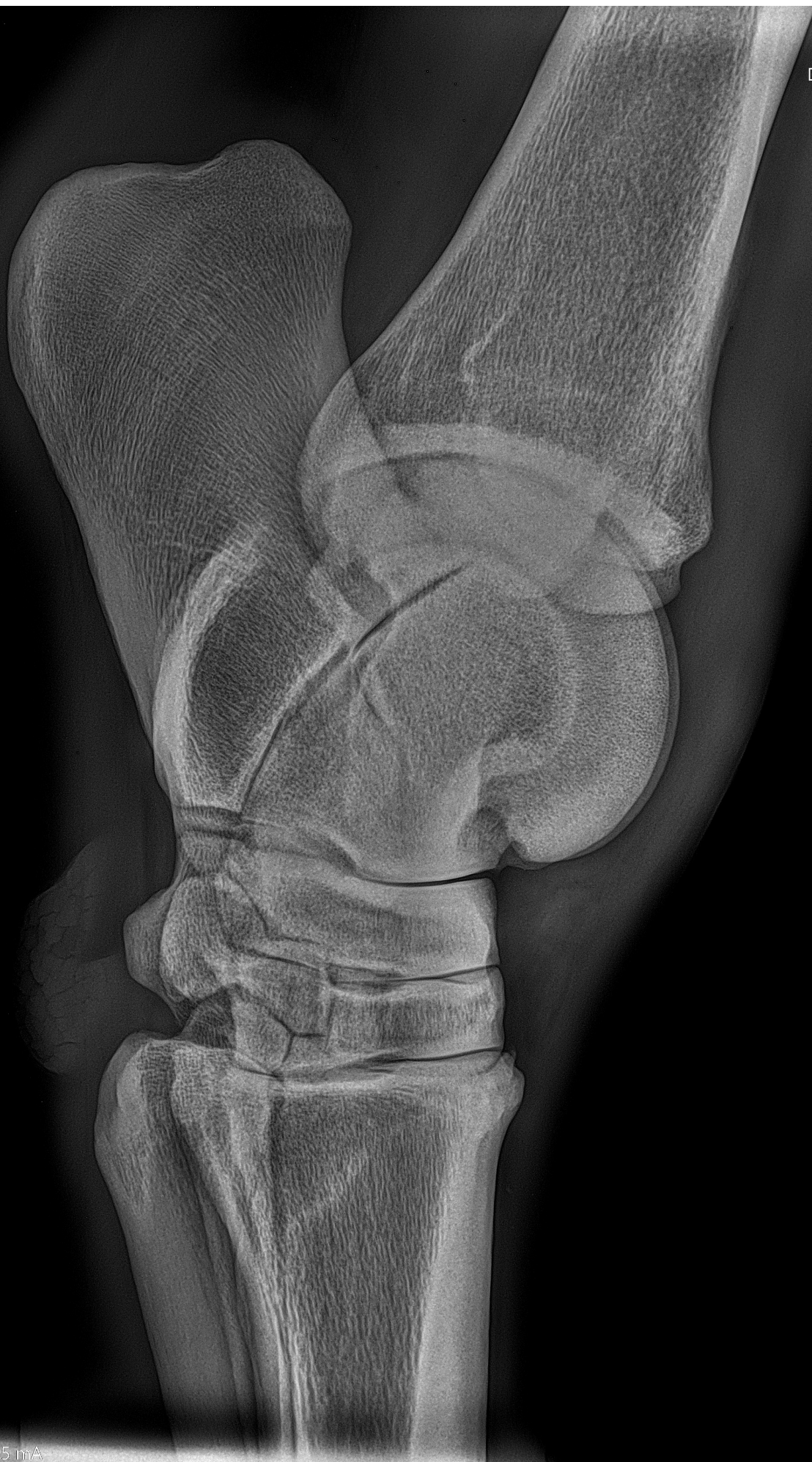

70 kVp 2,5 mAs 15 mA

DX

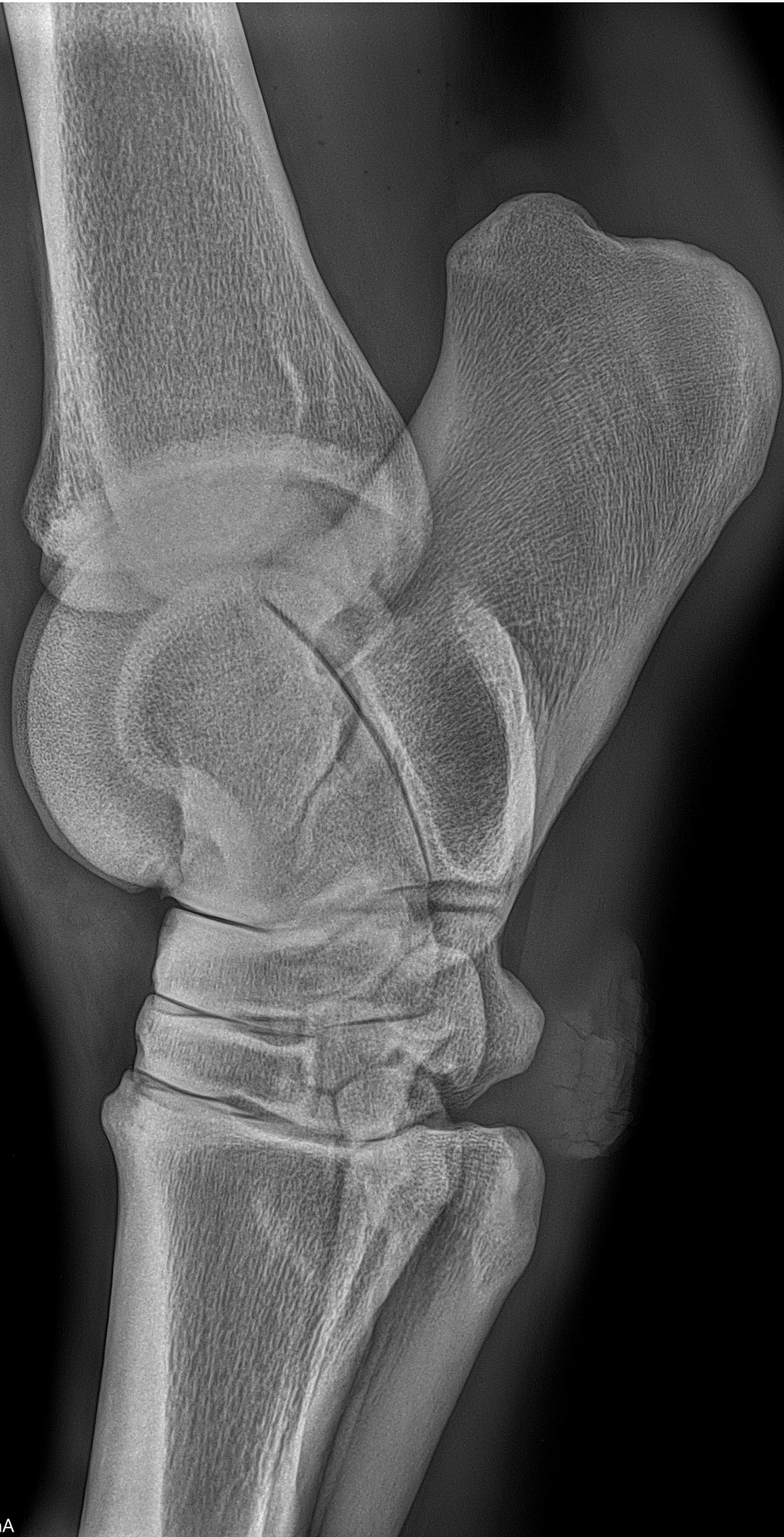
MC vet  
Anatomy: Tarse  
View: Latéral  
Lat: PD

Vet Rec:  
DULAC, KAPRICE HG  
Cheval  
Acq Dt: 30/03/2026  
Acq Tm: 14:07



MC vet  
Anatomy: Tarse  
View: Latéral  
Lat: PG

Vet Rec:  
DULAC, KAPRICE HG  
Cheval  
Acq Dt: 30/03/2026  
Acq Tm: 14:08

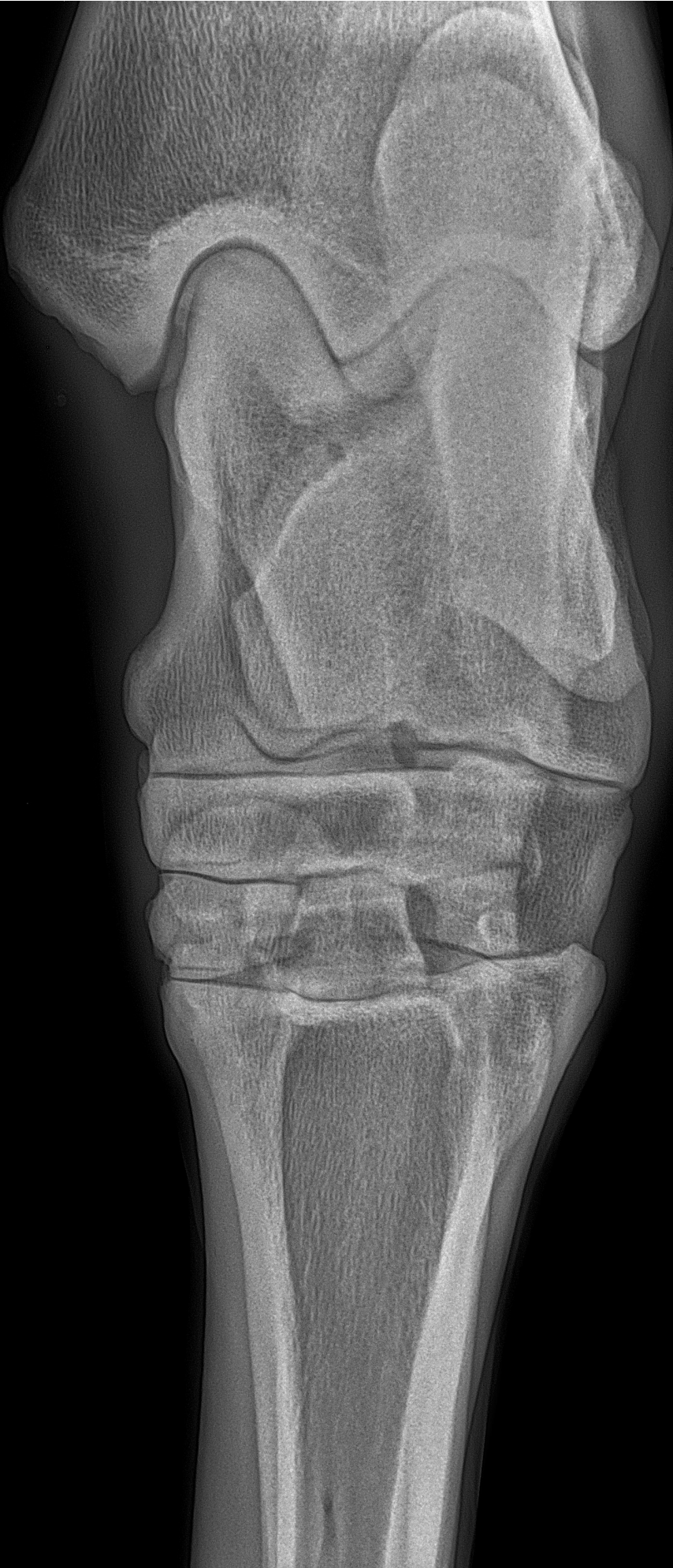

70 kVp 2,5 mAs 15 mA

DX

MC vet  
Anatomy: Tarse  
View: DP  
Lat: PG

Vet Rec:  
DULAC, KAPRICE HG  
Cheval  
Acq Dt: 30/03/2026  
Acq Tm: 14:09



70 kVp 2,5 mAs 15 mA

DX