

ADRENALECTOMY

1. An adrenalectomy specimen weighing X g is received. The specimen measures XXX cm in total // accompanied by periglandular adipose tissue measuring XXX cm.
2. Externally, the specimen shows no remarkable features // shows a nodular / multinodular appearance.
3. The specimen is inked.
4. On serial sectioning, an adrenal gland measuring XXX cm is identified, containing a neoplastic lesion measuring XXX cm located in the centre / periphery of the specimen and situated X cm from the surgical margin, infiltrating / not infiltrating the periadrenal adipose tissue / inked margin.
5. The lesion has poorly / well-defined borders, without a capsule / pseudoencapsulated / non-encapsulated. The cut surface is homogeneous / heterogeneous, with haemorrhagic / necrotic / cystic areas comprising X% of the total tumour volume.
6. In the remainder of the specimen, residual adrenal parenchyma measuring X cm in thickness is identified, with the cortex / medulla showing an X relationship to the lesion.
7. Representative sections are submitted as follows:

1st Example (Adrenalectomy with adrenal adenoma)


- A1: lateral margin.
- A2: contralateral margin.
- A3–A4: one complete section of the lesion (with adrenal gland).
- A5: section of periglandular adipose tissue / 3 nodular formations.

2nd Example (Adrenalectomy for pheochromocytoma)

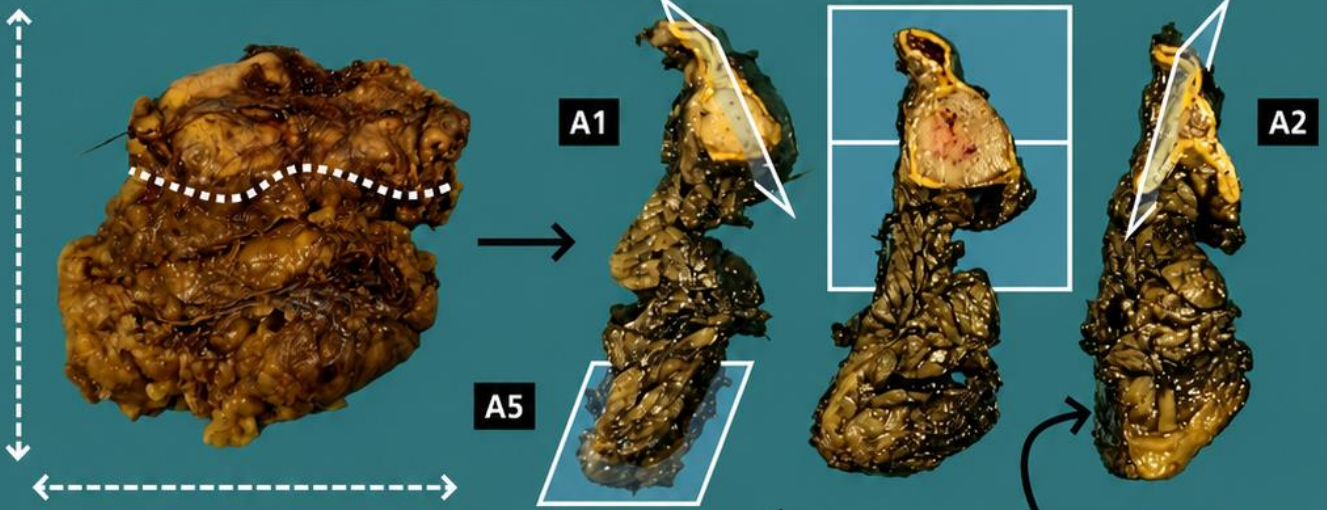
- A1: lateral margin of the specimen.
- A2: contralateral margin of the specimen.
- A3 – A5: one complete section.
- A6 – A7: second complete section of the lesion.

TO CONSIDER

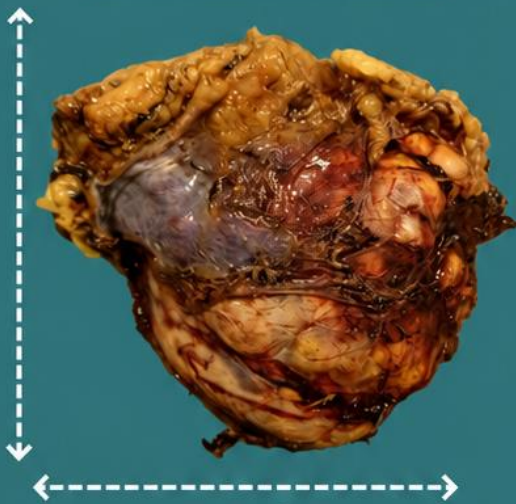
- Excision of the adrenal gland for neoplastic lesions, generally identified by radiological imaging studies.
- Review the clinical history to confirm the diagnostic suspicion (incidentaloma vs primary tumour vs metastatic lesion). Neuroblastomas should follow a different protocol.
- Weigh (specimens weighing <50 g are usually benign), measure, and describe the external surface of the specimen, indicating the presence of peripheral adipose or soft tissue.
- Ink the entire specimen.
- Serially section, measure the lesion, and describe its morphology. Indicate the relationship with the non-neoplastic adrenal parenchyma (the cortex is yellowish and the medulla greyish) and whether capsular invasion is present.
- Submit representative sections:
 - Include all resection margins.
 - At least one section per centimetre of the greatest dimension of the specimen.
 - Sample any areas suspicious for necrosis and capsular invasion (if present).
 - If present, include sections of adrenal gland without neoplastic lesions.
 - Search for possible nodular formations (lymph nodes) within the periadrenal adipose tissue.



Suprenalectomy for adenoma



Suprenalectomy for pheochromocytoma


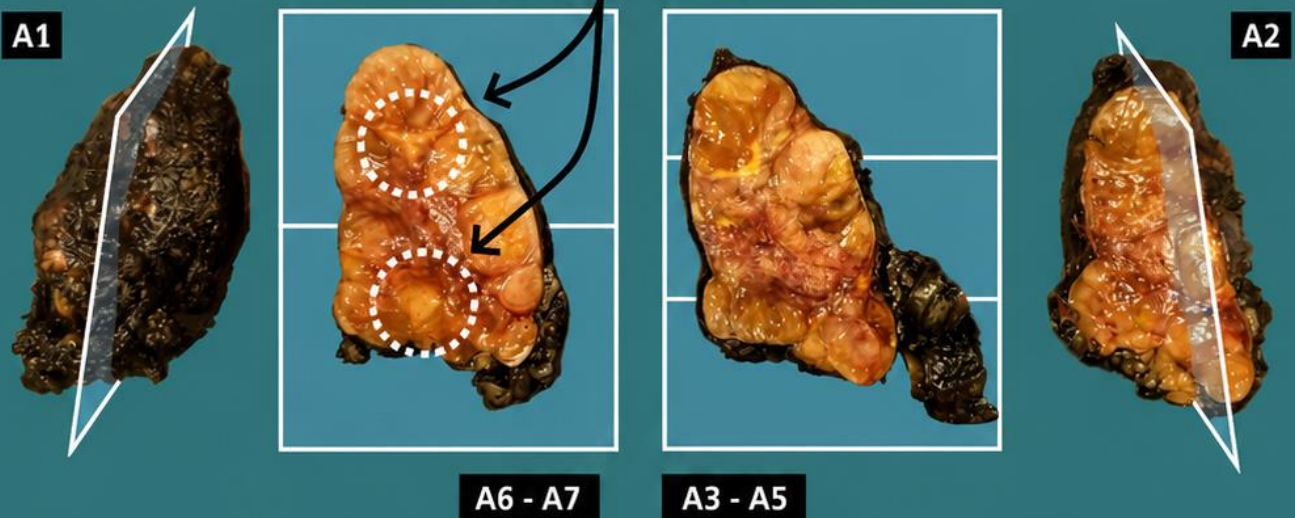


Emilio I. Abecia

Search for lymph nodes

1. Weigh, orient and measure the specimen
2. Describe external surface
3. Examine surgical resection margin
4. Serially section the specimen; identify and measure lesion(s) and state whether there is capsular or peripheral fat infiltration
5. Describe cut surface of the lesion(s)
6. Describe remnant suprarenal gland and/or search for nodular lesions (lymph nodes)
7. Include representative sections

Foci of necrosis



BIBLIOGRAPHY

- Cipriani N., Rose S. (2019). *Adrenal Gland (GU & Renal)*. Gross Pathology Manual (University Of Chicago). Recuperado el 13 de Mayo de 2024: <https://voices.uchicago.edu/grosspathology/gu-renal/adrenal-gland/>
- *Adrenalectomy (Morcellated or Intact Resection) (Genitourinary)*. Gross Manual. UCLA Health. Recuperado el 13 de Mayo de 2024: <https://www.uclahealth.org/sites/default/files/documents/a5/adrenal-021023.pdf?f=349d9a07>
- Mete O., Asa S.L., Davis J.L., Erickson L., Giordano T.J., Thompson L.D.R., Tischler A. (2023). *Adrenal Gland* (v4.3.1.0). College of American Pathologists (CAP). Recuperado el 13 de Mayo de 2024: https://documents.cap.org/documents/Adrenal_4.3.1.0.REL_CAPCP.pdf?_gl=1*1vfxrft*_ga*MTc4Nzk0MDczNC4xNzE0NDczNzAy*_ga_97ZFJSQQ0X*MTcxNDQ3MzcxwMi4xLjEuMTcxNDQ3NDExMy4wLjAuMA
- WHO Classification of Tumours Editorial Board (2017). *WHO Classification of Tumours of Endocrine Organs* (4th ed, vol. 10). International Agency for Research on Cancer. <https://publications.iarc.fr/Book-And-Report-Series/Who-Classification-Of-Tumours/WHO-Classification-Of-Tumours-Of-Endocrine-Organs-2017>
- Lemos, M. B., & Okoye, E. (2019). *Atlas of Surgical Pathology Grossing*. Springer Nature Switzerland AG. <https://link.springer.com/book/10.1007/978-3-030-20839-4>
- Susan C. Lester, French, C. A., & Curtis, S. G. (2010). *Manual of Surgical Pathology: Expert Consult* (ed. 3). Elsevier. <https://www.sciencedirect.com/book/9780323065160/manual-of-surgical-pathology>
- Shameem Shariff. (2019). *Fundamentals of Surgical Pathology* (ed.2). Jaypee Brothers Medical Publishers. <https://www.jaypeedigital.com/book/9789388958967>
- Westra, W. H., Ralph H. Hruban, Timothy H. Phelps, & Christina Iacono. (2003). *Surgical Pathology Dissection: An Illustrated Guide* (ed.2). Springer. <https://link.springer.com/book/10.1007/b97473>

DISCLAIMER

The image and text are provided for illustrative purposes only. The tissue sections submitted and the description provided will depend on the individual specimen characteristics, the clinical diagnostic suspicion, the experience of the dissector, and the institutional guidelines of the laboratory.

This document has been translated from the original Spanish version using AI-based tools. The text may contain typographical errors or inaccurate translations.

