


RADICAL PROSTATECTOMY

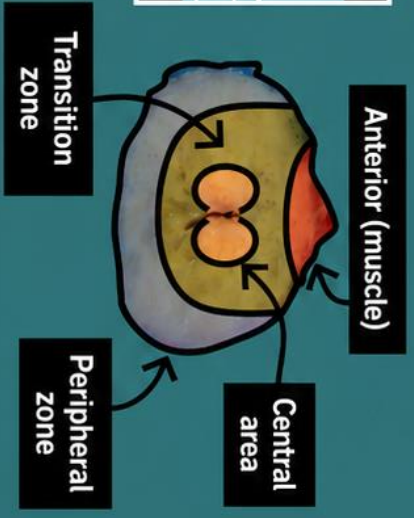
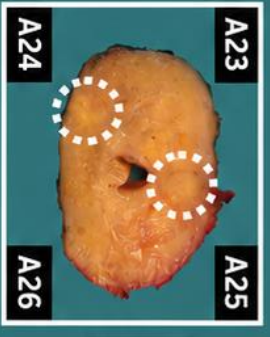

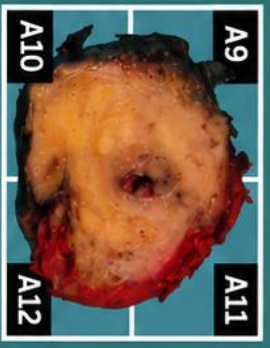


1. Labelled as a radical prostatectomy, a prostate gland weighing XX g and measuring XXX cm is received. The left seminal vesicle measures XXX cm, with a vas deferens measuring X cm; the right seminal vesicle measures XXX cm, with a vas deferens measuring X cm.
2. The specimen is inked with India ink.
3. On serial sectioning, the parenchyma shows alternating solid and microcystic areas without well-defined neoplastic lesions identified / a solid indurated / nodular area is identified at the apex / bladder neck / posterior / anterior / lateral X aspect // a dominant nodule measuring XXX cm in greatest diameter is identified, located in the X region and lying X cm from the surgical margin.
4. Representative sections are submitted as follows:
 - A1 - A4: bladder neck.
 - A5 - A8: apex.
 - A9 - A33: prostate body, from bladder neck to apex.
 - A34: left seminal vesicle.
 - A35: right seminal vesicle.

POINTS TO CONSIDER

- Oncological resection of the prostate gland, which may have been treated with hormonal therapy or chemoradiotherapy.
- Weigh, measure, and orientate the specimen.
- Ink the external surface and separate the bladder neck, apex, and seminal vesicles; subsequently serially section the entire specimen into slices approximately 3–4 mm thick.
- Grossing of prostatectomy specimens is generally performed in a schematic and systematic manner. There is no universal consensus regarding prostate sampling; however, in general terms:
 - Always submit the apex and bladder neck (apical and basal margins) in perpendicular sections.
 - Always submit the base of the seminal vesicles and posterior sections to assess neoplastic infiltration, as this alters staging.
 - If the specimen weighs between 40–45 g, submit the prostate body entirely.
 - If the specimen weighs >45 g, consider submitting the body in alternating sections.
- Even when representative sampling is performed, each selected section should be entirely submitted, ideally in large-format blocks or quadrants with the urethra present in all blocks.
- If the specimen is very large or irregular and quadrant sections do not fit into the cassettes, divide further into eighths (see image).



1. Orient, weigh and measure the specimen, including its anatomical structures
2. Ink the specimen (multiple colours are recommended)
3. Serially section the vesicles and apex to the neck; describe the cut surface and any visible lesions, as well as the distance to surgical margins
4. Include representative sections / entire specimen submission



BIBLIOGRAPHY

- Cipriani N., Rose S. (2019). *Prostate: Prostatectomy (GU & Renal)*. Gross Pathology Manual (University Of Chicago). Recuperado el 13 de Mayo de 2024: <https://voices.uchicago.edu/grosspathology/gu-renal/prostate-prostatectomy/>
- *Radical Prostatectomy (Genitourinary)*. Gross Manual. UCLA Health. Recuperado el 13 de Mayo de 2024: <https://www.uclahealth.org/sites/default/files/documents/e0/radical-prostatectomy-22223.pdf?f=63ba8e87>
- Paner G.P., Srigley J.R., Harik L.R., Amin M.B., Eggener S.E., Huang J., Montironi R., Pettus J.R., Giannico G.A., Sirintrapun S.J., Wheeler T.M., Zhou M. (2023). *Prostate, Resection* (v4.3.0.0). College of American Pathologists (CAP). Recuperado el 13 de Mayo de 2024: https://documents.cap.org/protocols/Prostate_4.3.0.0.REL_CAPCP.pdf?_gl=1*1qgw4n0*_ga*MTc4Nzk0MDczNC4xNzE0NDczNzAy*_ga_97ZFJSQQ0X*MTcxNDQ3MzcxwMi4xLjEuMTcxNDQ3NDExMy4wLjAuMA
- WHO Classification of Tumours Editorial Board (2022). *Urinary and Male Genital Tumours* (5th ed., vol. 8). International Agency for Research on Cancer. <https://publications.iarc.fr/Book-And-Report-Series/Who-Classification-Of-Tumours/Urinary-And-Male-Genital-Tumours-2022>
- Lemos, M. B., & Okoye, E. (2019). *Atlas of Surgical Pathology Grossing*. Springer Nature Switzerland AG. <https://link.springer.com/book/10.1007/978-3-030-20839-4>
- Susan C. Lester, French, C. A., & Curtis, S. G. (2010). *Manual of Surgical Pathology: Expert Consult* (ed. 3). Elsevier. <https://www.sciencedirect.com/book/9780323065160/manual-of-surgical-pathology>
- Shameem Shariff. (2019). *Fundamentals of Surgical Pathology* (ed.2). Jaypee Brothers Medical Publishers. <https://www.jaypeedigital.com/book/9789388958967>
- Westra, W. H., Ralph H. Hruban, Timothy H. Phelps, & Christina Iacson. (2003). *Surgical Pathology Dissection: An Illustrated Guide* (ed.2). Springer. <https://link.springer.com/book/10.1007/b97473>

DISCLAIMER

The image and text are provided for illustrative purposes only. The tissue sections submitted and the description provided will depend on the individual specimen characteristics, the clinical diagnostic suspicion, the experience of the dissector, and the institutional guidelines of the laboratory

. This document has been translated from the original Spanish version using AI-based tools. The text may contain typographical errors or inaccurate translations.

