

TUMORAL CHOLECYSTECTOMY

1. A cholecystectomy specimen measuring XXX cm is received.
2. Externally, it has a greenish / greyish / blackish coloration, with an intact / perforated wall, showing a defect measuring XXX cm // a poorly defined mass / indurated area measuring XXX cm is identified, located at X.
3. The external margin is inked.
4. On opening, a neoplastic lesion measuring XXX cm is identified, located X cm from the infundibulum / cystic duct and appearing / not appearing to infiltrate the wall // the lesion is located X cm from the inked margin.
5. The lesion has a polypoid / exophytic / ulcerative / ulceroinfiltrative appearance, with a brownish / whitish coloration and firm consistency, etc.
6. On sectioning, the lesion appears to infiltrate the muscular / adipose / serosal layer // appears confined to the mucosa, and is located X cm from the inked margin.
7. The biliary content is greenish / blackish, without intraluminal calculi identified // with one / several calculi showing X coloration, X consistency, and measuring XXX cm. The wall measures X mm in thickness.
8. Representative sections are submitted in blocks:

1st Example (Cholecystectomy with a polyp at the fundus):

- A1: infundibular margin.
- A2 and A3: sections of the tumour lesion.
- A4: section of the lesion in relation to the parenchyma.
- A5: section in relation to the deep margin.
- A6: section of mucosa.
- A7: nodular formation compatible with a cystic lymph node.

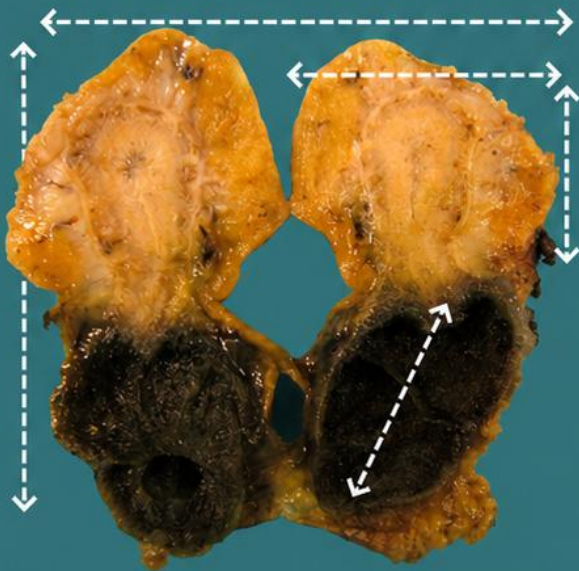
2nd Example (Porcelain gallbladder with malignant lesion):

- A1: infundibular margin.
- A2–A5: one complete section of the tumour lesion.
- A6: section in relation to the serosa.
- A7: section of the lesion in relation to the parenchyma.
- A8: section of mucosa.
- A9: nodular formation compatible with a cystic lymph node.

POINTS TO CONSIDER

- Gallbladder resection performed for a diagnosis or suspicion of malignancy on imaging studies. Frequently identified incidentally in a gallbladder removed for another indication.
- Measure and describe the specimen; indicate possible wall thickening or perforation.
- Ink the margin adjacent to / in contact with the liver and open the gallbladder.
- Localise, measure, and describe the lesion. Measure its distance to the cystic duct and the level of infiltration of surrounding structures.
- Also describe additional non-neoplastic findings within the specimen (cholelithiasis, biliary contents, etc.).
- Submit representative sections:
 - Include the cystic duct margin.
 - Adequately sample the neoplastic lesion (at least one section per centimetre of the greatest dimension of the lesion), including the closest distance to the “margin”.
 - Include at least one section of uninvolved parenchyma (to assess for concomitant pathology).
 - Attempt to identify and submit the pericyclic lymph node, as this corresponds to the sentinel lymph node.

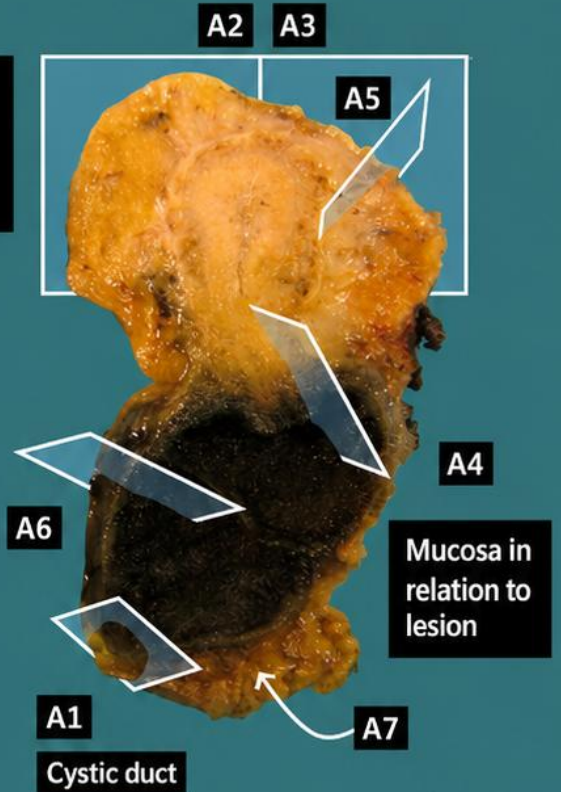




Lesions are commonly present at the vertex

Cholecystectomy specimen with polyp at vertex

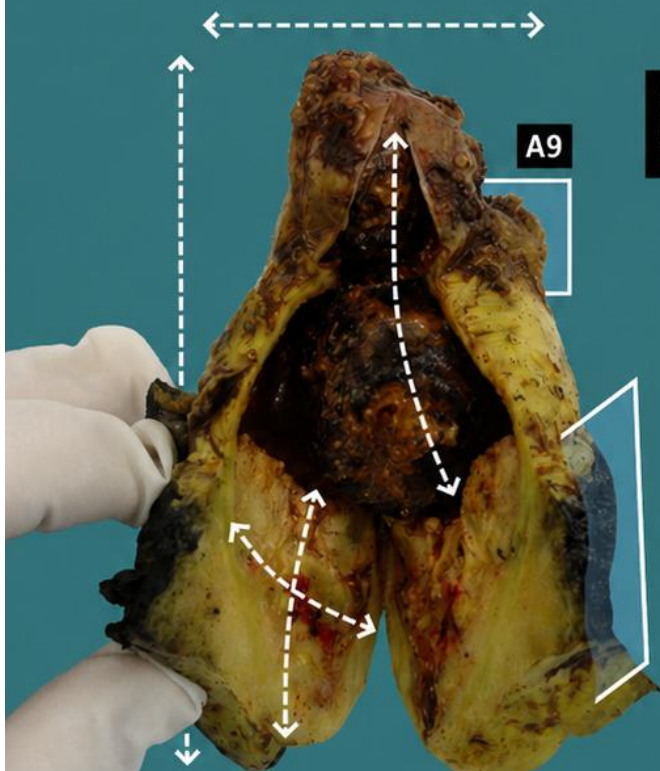
1. Orientate and measure the specimen
2. Describe external surface of the specimen
3. Describe external surface ("hepatic" margin)
4. Open and locate the lesion; state level of infiltration and distance to margins
5. Describe lesion morphologically
6. Describe remaining non-neoplastic surface
7. Examine cystic duct / adipose tissue for lymph nodes
8. Submit representative sections



Mucosa in relation to lesion

Cystic duct

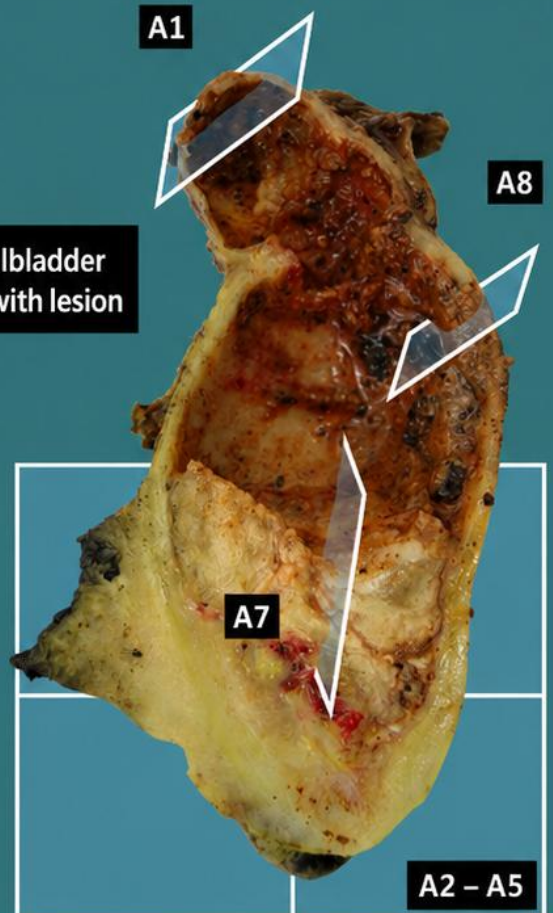
Emilio I. Abecia




Bile-filled gallbladder in porcelain with lesion

A6

A9



A2 - A5



BIBLIOGRAPHY

- Cipriani N., Rose S. (2019). *Gallbladder*. Gross Pathology Manual (University of Chicago). Recuperado el 13 de Mayo de 2024: <https://voices.uchicago.edu/grosspathology/gi-liver/gallbladder/>
- *Cholecystectomy (Neoplastic) (Hepatobiliary)*. Gross Manual. UCLA Health. Recuperado el 13 de Mayo de 2024: <https://www.uclahealth.org/sites/default/files/documents/Cholecystectomy%20%28Neoplastic%29.pdf>
- Burgart L. J., Chopp W. V., MD; Jain D. (2021). *Gallbladder* (v4.2.0.0). College of American Pathologists (CAP). Recuperado el 13 de Mayo de 2024: https://documents.cap.org/protocols/Gallbladder_4.2.0.0.REL_CAPCP.pdf?_gl=1*1lax37z*_ga*MTc4Nzk0MDczNC4xNzE0NDczNzAy*_ga_97ZFJSQQ0X*MTcxNDQ3MzcwMi4xLjEuMTcxNDQ3NDExMy4wLjAuMA
- WHO Classification of Tumours Editorial Board (2019). *Digestive system tumours* (5th ed., vol. 1). International Agency for Research on Cancer. <https://publications.iarc.fr/Book-And-Report-Series/Who-Classification-Of-Tumours/Digestive-System-Tumours-2019>
- Lemos, M. B., & Okoye, E. (2019). *Atlas of Surgical Pathology Grossing*. Springer Nature Switzerland AG. <https://link.springer.com/book/10.1007/978-3-030-20839-4>
- Susan C. Lester, French, C. A., & Curtis, S. G. (2010). *Manual of Surgical Pathology: Expert Consult* (ed. 3). Elsevier. <https://www.sciencedirect.com/book/9780323065160/manual-of-surgical-pathology>
- Shameem Shariff. (2019). *Fundamentals of Surgical Pathology* (ed.2). Jaypee Brothers Medical Publishers. <https://www.jaypeedigital.com/book/9789388958967>
- Westra, W. H., Ralph H. Hruban, Timothy H. Phelps, & Christina Iacson. (2003). *Surgical Pathology Dissection: An Illustrated Guide* (ed.2). Springer. <https://link.springer.com/book/10.1007/b97473>

DISCLAIMER

The image and text are provided for illustrative purposes only. The tissue sections submitted and the description provided will depend on the individual specimen characteristics, the clinical diagnostic suspicion, the experience of the dissector, and the institutional guidelines of the laboratory.

This document has been translated from the original Spanish version using AI-based tools. The text may contain typographical errors or inaccurate translations.

