

NON-TUMORAL NEPHRECTOMY

1. A left / right nephrectomy weighing X g and measuring XXX cm is received, including perirenal adipose tissue / with a segment of ureter / renal vein / renal artery measuring XX cm.
2. Externally, no remarkable features are identified // the capsular surface is intact / torn / nodular / globular / fibrotic // atheromatous plaques measuring X cm are identified in the renal artery / vein // a capsular cystic lesion measuring X cm in diameter is identified, located in X.
3. On opening, the kidney measures XXX cm, with preserved / atrophic parenchyma, with a thickness of X cm, and a pelvicalyceal system without abnormalities / dilated / distorted / atrophic // a cystic / scar-like / lithiasic lesion measuring XXX cm is identified, located in X and showing X characteristics.
4. On opening, the ureter shows no remarkable features // shows a lesion measuring XXX cm in the proximal / middle / distal ureter, with X morphology and appearing to infiltrate up to the X layer on sectioning.
5. On palpation, no hilar nodular formations or adrenal gland are identified // an adrenal gland measuring X cm in diameter is identified // X nodular formations measuring between X and X cm in diameter are identified.
6. Submission of representative sections:

1st Example (Renal transplant):


- A1: section of renal artery.
- A2: section of renal vein.
- A3: ureteric margin.
- A4: representative section of upper renal pole (with simple cysts).
- A5: representative section of mid renal third (with simple cysts).
- A6: representative section of lower renal pole.
- A7: representative section of hilar adipose tissue / renal sinus.
- A8: representative section of ureter.

2nd Example (Nephrectomy with hydronephrosis):

- A1: ureteric margin.
- A2: vascular margins.
- A3: representative section of adrenal gland.
- A4: representative section of ureter.
- A5: representative section of upper renal pole.
- A6: representative section of middle third.
- A7: representative section of lower renal pole.
- A8: section of pelvicalyceal ectasia / dilated renal sinus.

3rd Example (Nephrectomy for polycystic kidney disease):

- A1: vascular margins.
- A2: ureteric margin.
- A3: section of renal sinus.
- A4: representative section of upper renal pole.
- A5: representative section of mid renal third.
- A6: representative section of lower renal pole.
- A7 - A8: additional representative sections of renal cysts.




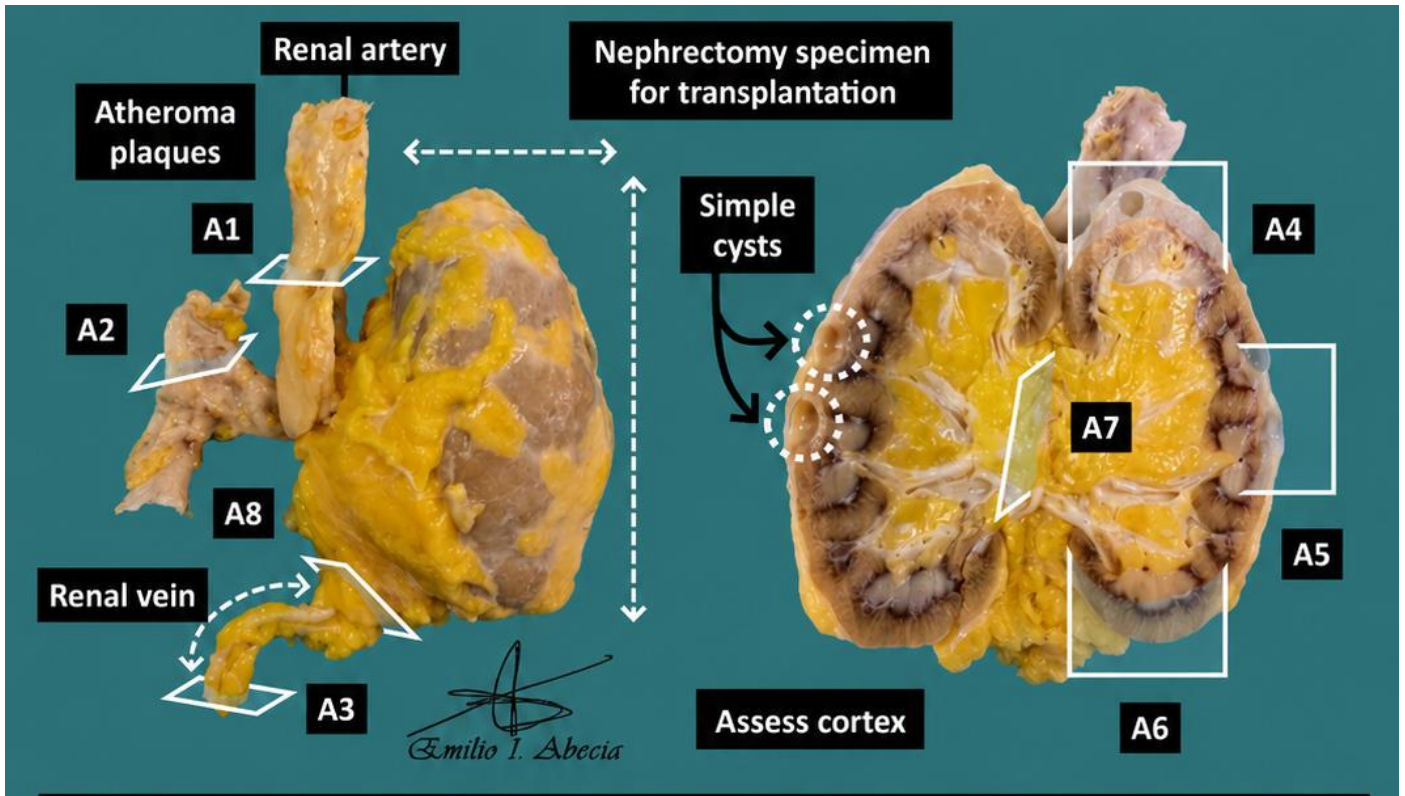
4th Example (Nephrectomy for acute ischaemia following renal vein thrombosis):

- A1: vascular margins.
- A2: ureteric margin.
- A3: section of renal sinus.
- A4: representative section of upper renal pole.
- A5: representative section of mid renal third.
- A6: representative section of lower renal pole.

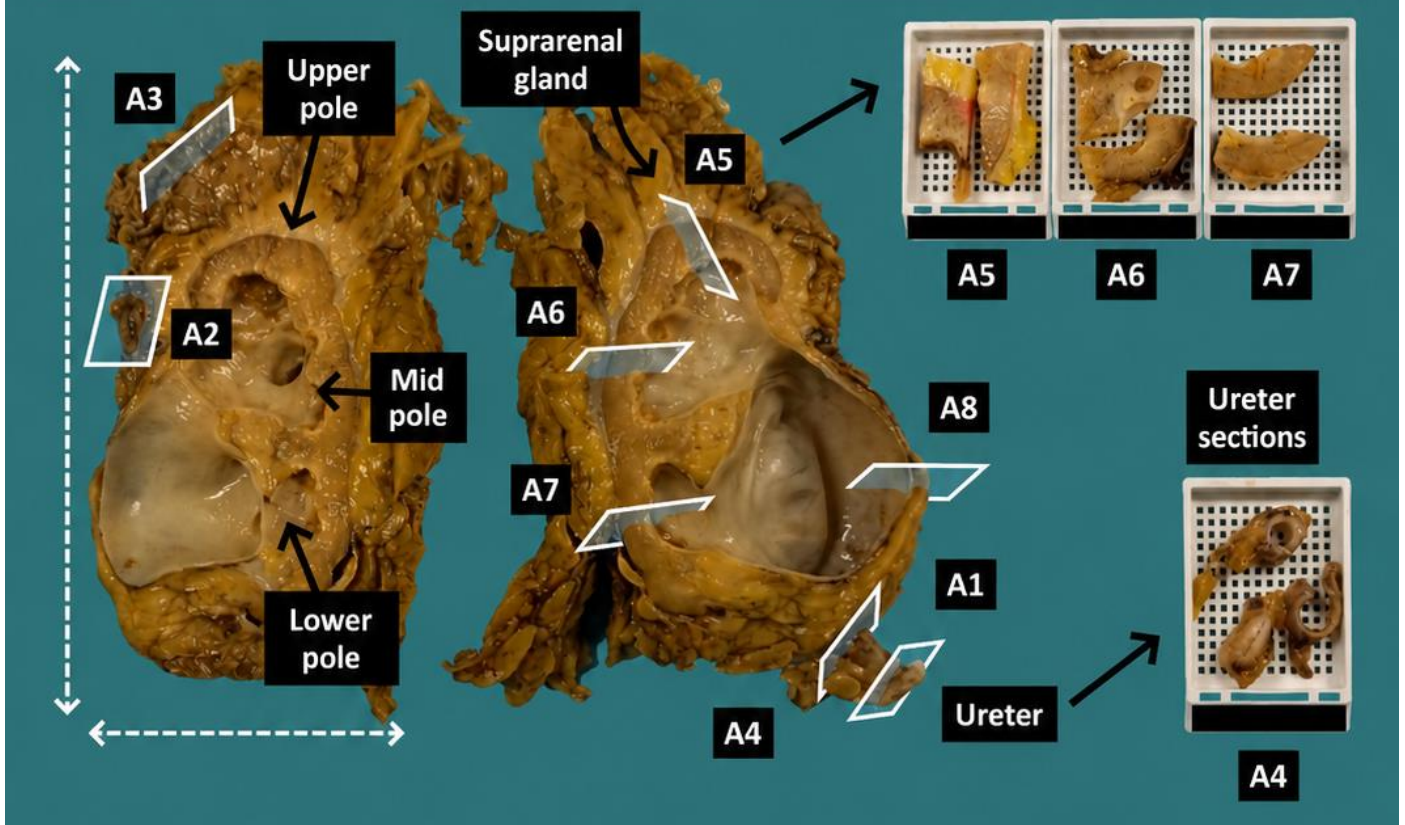
TO CONSIDER

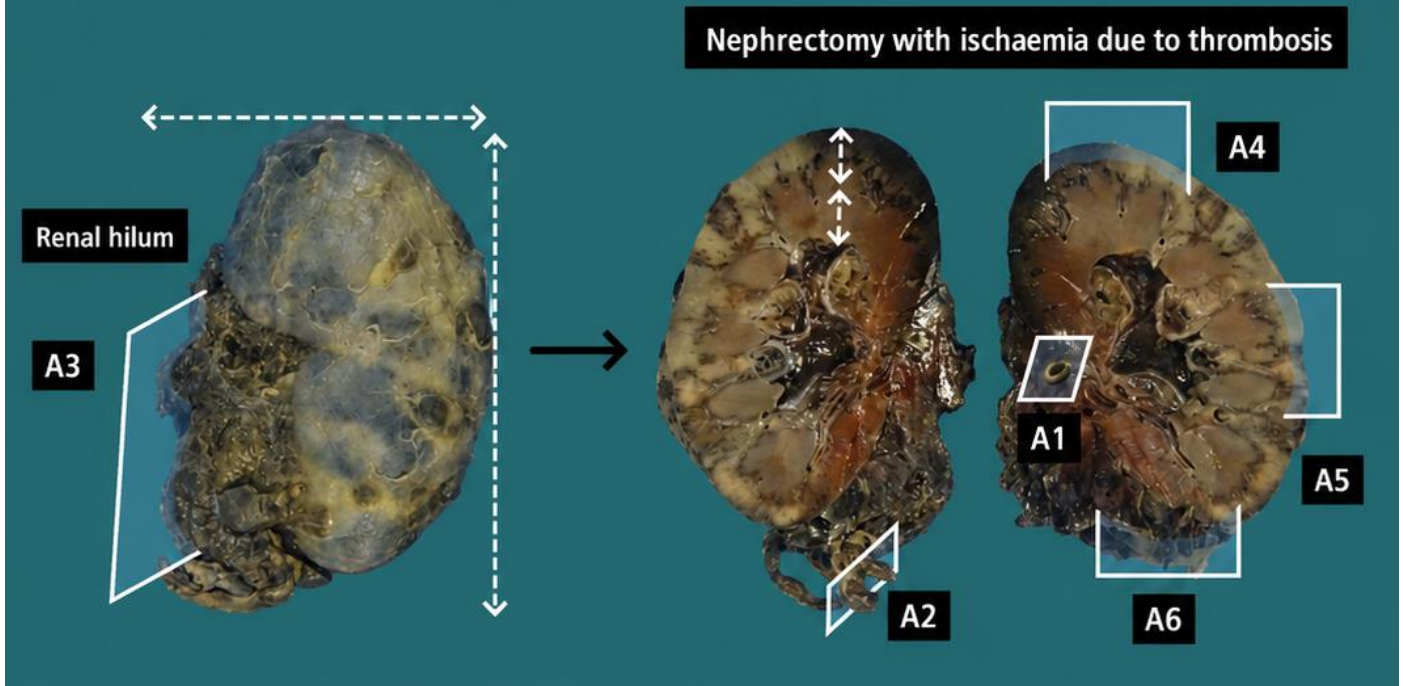
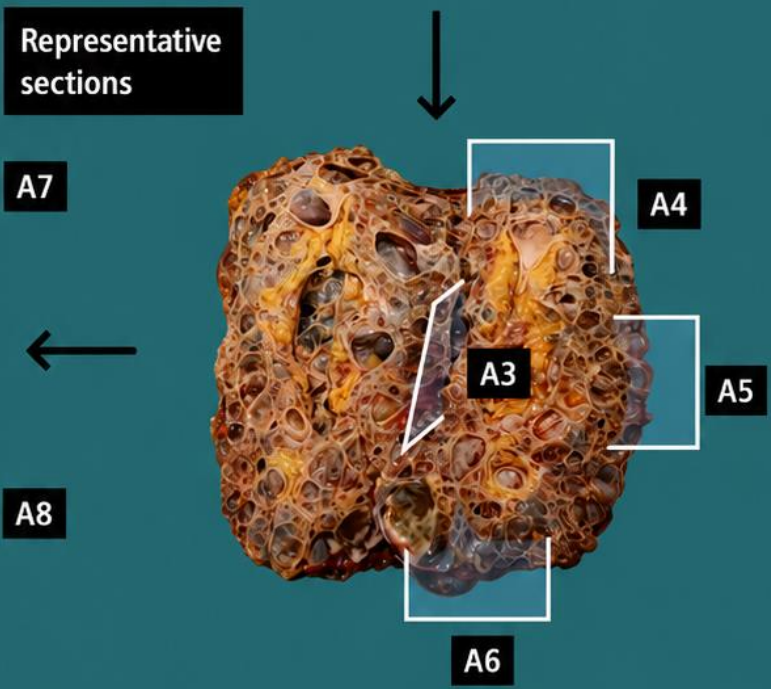
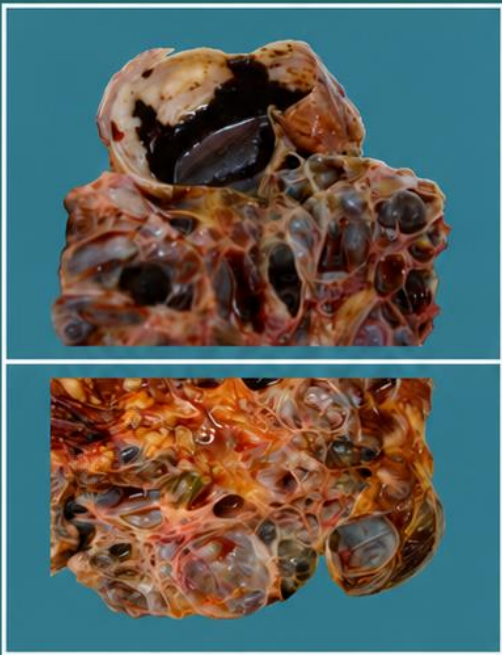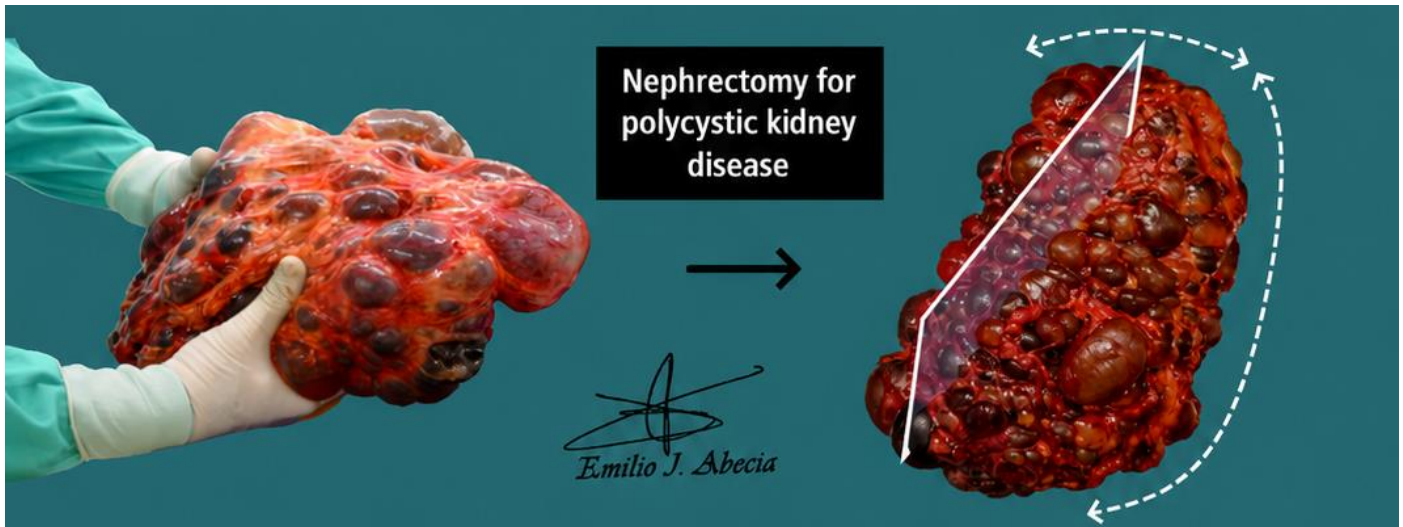
- Renal excision for non-neoplastic pathology, such as transplantation, trauma, ischaemia, mechanical obstruction, nephrolithiasis, cysts, etc.
- Review the clinical history to determine the indication for surgery.
- Weigh, orientate, measure, and describe the external surface of the specimen.
- Open along the longitudinal axis and inspect the parenchyma. Parallel sections are recommended to assess for incidental peripheral lesions (for example: simple cysts).
- Measure the thickness of the residual cortex.
- Palpate the perirenal and hilar adipose tissue in search of adrenal gland or lymph nodes.
- Submit representative sections:
 - Include vascular and ureteric margins.
 - Include representative sections of renal cortex and medulla.
 - Sample any lesions present (simple cysts, dilatation, atrophy, etc.).
 - Include a section of adrenal gland / hilar lymph nodes if present.
 - Include representative sections of ureter, renal vein, or renal artery if present.





1. Weigh, measure and describe specimen, indicating anatomical structures present
2. Describe external surface
3. Open kidney longitudinally and report presence of lesions (cysts, atrophy, calculi, etc.)
4. Open ureter longitudinally and describe any abnormalities
5. Palpate perirenal adipose tissue, looking for enlarged lymph nodes or suprarenal GIT
6. Representative sections of the specimen





BIBLIOGRAPHY

- Cipriani N., Rose S. (2019). *Nephrectomy (Transplant Or Non-Neoplastic) (GU & Renal)*. Gross Pathology Manual (University Of Chicago). Recuperado el 13 de Mayo de 2024: <https://voices.uchicago.edu/grosspathology/gu-renal/nephrectomy-transplant-or-non-neoplastic/>
- Cipriani N., Rose S. (2019). *Kidney (Trauma) (GU & Renal)*. Gross Pathology Manual (University Of Chicago). Recuperado el 13 de Mayo de 2024: <https://voices.uchicago.edu/grosspathology/gu-renal/kidney-trauma/>
- *Nephrectomy (Non Neoplastic)-Pylonephritis, Hydronephrosis, Polycystic Disease, Allograft (Genitourinary)*. Gross Manual. UCLA Health. Recuperado el 13 de Mayo de 2024: <https://www.uclahealth.org/sites/default/files/documents/15/nephrectomy-non-neoplastic-021023.pdf?f=db357762>
- Lemos, M. B., & Okoye, E. (2019). *Atlas of Surgical Pathology Grossing*. Springer Nature Switzerland AG. <https://link.springer.com/book/10.1007/978-3-030-20839-4>
- Susan C. Lester, French, C. A., & Curtis, S. G. (2010). *Manual of Surgical Pathology: Expert Consult* (ed. 3). Elsevier. <https://www.sciencedirect.com/book/9780323065160/manual-of-surgical-pathology>
- Shameem Shariff. (2019). *Fundamentals of Surgical Pathology* (ed.2). Jaypee Brothers Medical Publishers. <https://www.jaypeedigital.com/book/9789388958967>
- Westra, W. H., Ralph H. Hruban, Timothy H. Phelps, & Christina Iacson. (2003). *Surgical Pathology Dissection: An Illustrated Guide* (ed.2). Springer. <https://link.springer.com/book/10.1007/b97473>

DISCLAIMER

The image and text are provided for illustrative purposes only. The tissue sections submitted and the description provided will depend on the individual specimen characteristics, the clinical diagnostic suspicion, the experience of the dissector, and the institutional guidelines of the laboratory.

This document has been translated from the original Spanish version using AI-based tools. The text may contain typographical errors or inaccurate translations.

