


FUNCTIONAL NECK DISSECTION

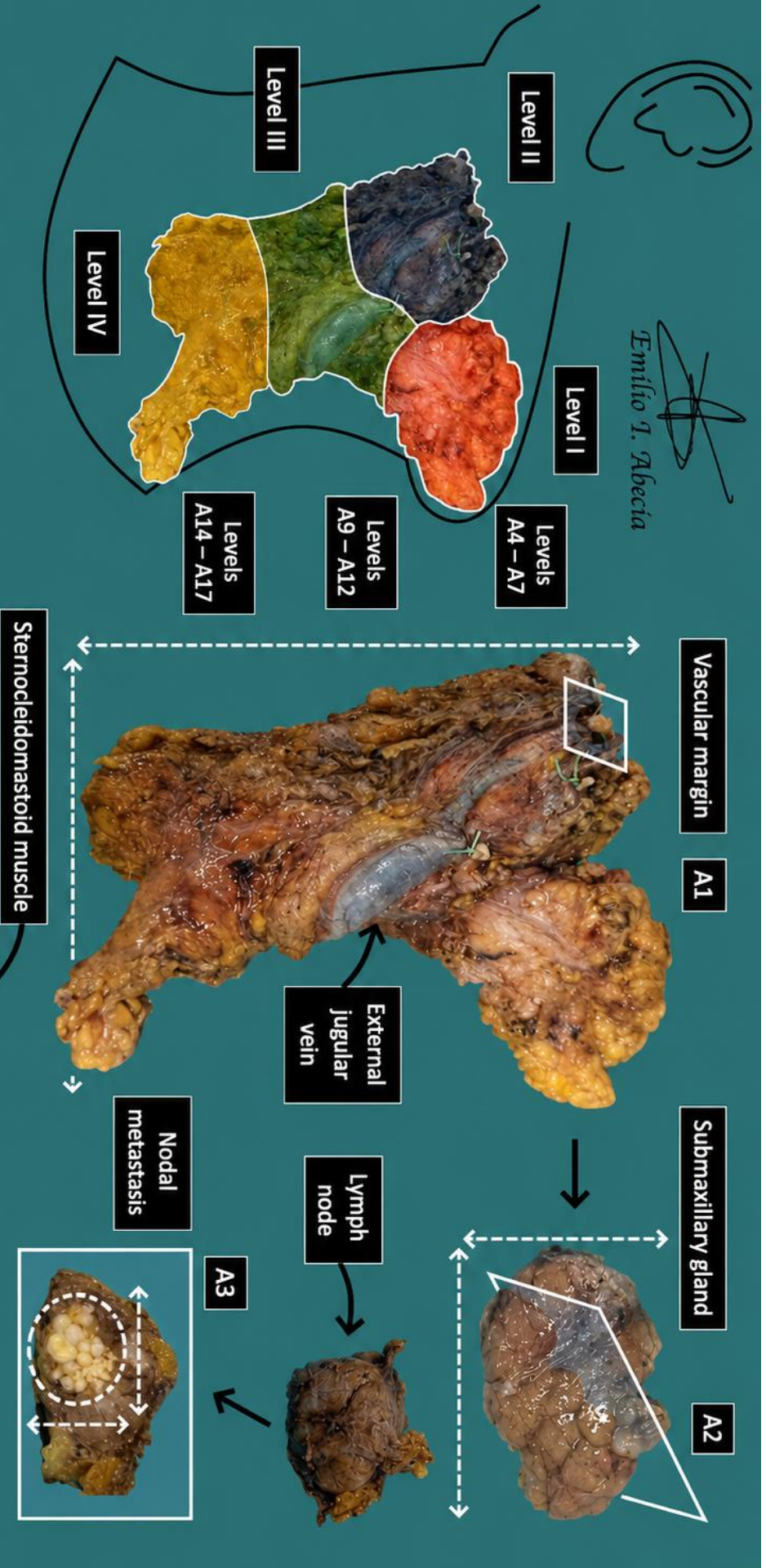
1. A left / right functional neck dissection specimen measuring XXX cm in total is received, without orientation provided / oriented with X indicating the X margin // a multifragmented specimen measuring XXX cm in aggregate is received // including a submandibular gland measuring XXX cm / a vascular structure measuring XXX cm / a muscular fragment measuring XXX cm.
2. Externally, no remarkable features are identified // a superficial lesion measuring X cm is identified, which does not appear to infiltrate / appears to infiltrate the submandibular gland / vascular structure / muscular fragment / etc.
3. On sectioning, the submandibular gland shows unremarkable yellowish parenchyma // shows fatty degeneration / a lesion measuring X cm with X appearance is identified.
4. On inspection and palpation, X nodular formations are identified in the upper third / level X, the largest measuring X cm; in the middle third / level X, X nodular formations are identified, the largest measuring X cm; in the lower third / level X, X nodular formations are identified, the largest measuring X cm.
5. On bisection, no remarkable features are identified // an X nodular formation from the X third / level shows a whitish focus measuring X cm, with macroscopic appearance suggestive of intranodal involvement / extranodal extension, suspicious for malignancy.
6. Representative sections are submitted as follows:
 - A1: margins of vascular structures.
 - A2: representative section of submandibular gland.
 - A3: largest nodular formation from upper third (suggestive of metastasis).
 - A4 – A7: 2 nodular formations per block from upper third / level X.
 - A8: largest nodular formation from middle third.
 - A9 – A12: 4 nodular formations per block from middle third / level X.
 - A13: largest nodular formation from lower third.
 - A14 – A17: 3 nodular formations per block from lower third / level X.

POINTS TO CONSIDER


- Resection of the cervical lymphatic chain, generally performed as part of surgical protocols in the head and neck region or for suspected / confirmed metastatic disease.
- Review the clinical history to determine the indication for surgery.
- Measure and orient the specimen if spatial references are provided. Note that the submandibular gland corresponds to level I (anteroposterior), the sternocleidomastoid muscle represents the superficial margin, and the internal jugular vein represents the deep margin.
- Measure, describe, and isolate all nodular formations identified. Indicate whether sectioning of lymph nodes reveals foci suspicious for metastasis (record size and description).
- Submit representative sections:
 - Include sections from vascular margins and submandibular gland parenchyma.
 - Attempt to isolate at least 20 lymph nodes in total.
 - If the specimen is spatially oriented, attempt to identify lymph node regions and submit them topographically.
 - If the specimen is unoriented or fragmented, isolate nodular formations (lymph nodes) by thirds or indiscriminately.
 - If tumour extension into muscle or vascular structures is identified, submit a couple of representative sections.
 - Submit large lymph nodes in multiple blocks if necessary; if they are grossly metastatic on visual inspection, one or two sections demonstrating infiltration are sufficient.



Emilio I. Abecia



1. Orientate and measure the specimen and its anatomical structures
2. Describe the external surface
3. Section the submaxillary gland and describe its cut surface
4. Palpate the anatomical levels of the neck and isolate nodular lesions (measure the largest diameter)
5. Section the largest lesion and report any additional lesions
6. Include representative sections with the total inclusion of nodular lesions



Emilio I. Abecia Martínez

BIBLIOGRAPHY

- Cipriani N., Rose S. (2019). *Sentinel Lymph Nodes For H&N Squamous Cell Carcinoma*. Gross Pathology Manual (University Of Chicago). Recuperado el 13 de Mayo de 2024: <https://voices.uchicago.edu/grosspathology/head-neck/sentinel-lymph-nodes-for-hn-squamous-cell-carcinoma/>
- Seethala R.R., Shon W., Balzer B.L., Duvvuri U., Gharavi N.M., Lydiatt W. (2023). *Cutaneous Squamous Cell Carcinoma* (v1.0.0.1). College of American Pathologists (CAP). Recuperado el 13 de Mayo de 2024: https://documents.cap.org/protocols/HN.SCC_1.0.0.1.REL_CAPCP.pdf?_gl=1*ow5hb1*_ga*M Tc4Nzk0MDczNC4xNzE0NDczNzAy*_ga_97ZFJSQQ0X*MTcxNDQ3MzcwMi4xLjEuMTcxND Q3NDExMy4wLjAuMA
- WHO Classification of Tumours Editorial Board (2024). *Head and Neck Tumours* (5th ed., vol. 9). International Agency for Research on Cancer. <https://publications.iarc.fr/Book-And-Report-Series/Who-Classification-Of-Tumours/Head-And-Neck-Tumours-2024>
- Cipriani N., Rose S. (2019). *Neck Dissections* (Head & Neck. Gross Pathology Manual (University Of Chicago). Recuperado el 13 de Mayo de 2024: <https://voices.uchicago.edu/grosspathology/head-neck/neck-dissections/>
- *Head and Neck Lymph Node Dissection (Head and Neck)*. Gross Manual. UCLA Health. Recuperado el 13 de Mayo de 2024: <https://www.uclahealth.org/sites/default/files/documents/Head%20and%20Neck%20Lymph%20Node%20Dissection.pdf>
- *Radical Neck Dissection (Standard, Modified, Extended, Regional) (Head and Neck)*. Gross Manual. UCLA Health. Recuperado el 13 de Mayo de 2024: <https://www.uclahealth.org/sites/default/files/documents/Radical%20Neck%20Dissection%204.14.22.pdf>
- Lemos, M. B., & Okoye, E. (2019). *Atlas of Surgical Pathology Grossing*. Springer Nature Switzerland AG. <https://link.springer.com/book/10.1007/978-3-030-20839-4>
- Susan C. Lester, French, C. A., & Curtis, S. G. (2010). *Manual of Surgical Pathology: Expert Consult* (ed. 3). Elsevier. <https://www.sciencedirect.com/book/9780323065160/manual-of-surgical-pathology>
- Shameem Shariff. (2019). *Fundamentals of Surgical Pathology* (ed.2). Jaypee Brothers Medical Publishers. <https://www.jaypeedigital.com/book/9789388958967>
- Westra, W. H., Ralph H. Hruban, Timothy H. Phelps, & Christina Iacono. (2003). *Surgical Pathology Dissection: An Illustrated Guide* (ed.2). Springer. <https://link.springer.com/book/10.1007/b97473>

DISCLAIMER

The image and text are provided for illustrative purposes only. The tissue sections submitted and the description provided will depend on the individual specimen characteristics, the clinical diagnostic suspicion, the experience of the dissector, and the institutional guidelines of the laboratory.

This document has been translated from the original Spanish version using AI-based tools. The text may contain typographical errors or inaccurate translations.

