

## MANDIBULECTOMY / MAXILLECTOMY

1. A segmental / marginal / left / right / upper / lower mandibulectomy / maxillectomy specimen measuring XXX cm is received, oriented by X at X / without orientation provided // showing X teeth measuring XX cm in total / with soft tissue / mucosal patch / skin patch / parotid gland / submandibular gland / functional neck dissection measuring XXX cm.
2. Externally, no lesions are identified // a lesion measuring XXX cm is identified, located X cm from the X margins.
3. The lesion shows an exophytic / irregular / ulcerated / flat appearance, with a brownish / whitish coloration and friable / hard / soft-elastic consistency.
4. The X margin is inked with X ink.
5. The specimen is serially sectioned; the lesion measures X cm in thickness, is located X cm from the X margin, and appears to infiltrate / does not infiltrate bone tissue / tooth X / soft tissue / skin patch / etc.
6. The lesion has a homogeneous / heterogeneous cut surface, with well / poorly defined borders / foci of necrosis / hemorrhage / cavitations / etc.
7. Bone tissue sections are submitted for decalcification in X at X %.
8. Representative sections are submitted as follows:

### 1st Example (Mandibulectomy with Squamous Cell Carcinoma)

- A1 - A3: internal soft tissue margin from posterior to anterior.
- A4 - A6: external soft tissue margin from anterior to posterior.
- A7: posterior soft tissue margin.
- A8: anterior soft tissue margin.
- A9: posterior bony margin.
- A10: anterior bony margin.
- A11 - A14: central mandibular sections from anterior to posterior.

### 2nd Example (Maxillectomy with Ameloblastoma)


- A1: left bony margin.
- A2: right bony margin.
- A3 - A4: one complete section.
- A5 - A6: second complete section.

### 3rd Example (Post-radiotherapy Mandibulectomy)

- A1: anterior soft tissue margin.
- A2: posterior soft tissue margin.
- A3 - A5: internal soft tissue margin from anterior to posterior.
- A6 - A8: external soft tissue margin from anterior to posterior.
- A9: anterior bony margin.
- A10: posterior bony margin.
- A11 - A12: one complete section of the specimen.
- A13 - A14: second complete section of the specimen.
- A15 - A16: third complete section of the specimen.

### 4th Example (Mandibulectomy + Functional Neck Dissection)


- A1: section of submandibular gland.
- A2: anterior soft tissue margin.
- A3: posterior soft tissue margin.
- A4 - A6: external soft tissue margin from posterior to anterior.
- A7 - A9: internal soft tissue margin from posterior to anterior.
- A10: anterior bony margin.
- A11: posterior bony margin.
- A12 - A14: central sections of the mandibulectomy from posterior to anterior.



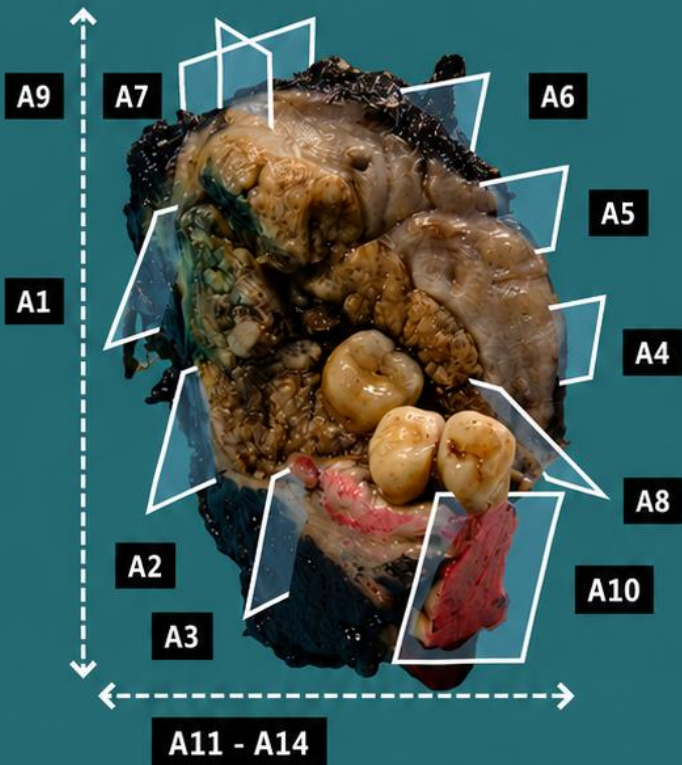
- A15 - A17: 2 nodular formations per block from the upper third.
- A18 - A20: 3 nodular formations per block from the middle third.
- A21 - A23: 3 nodular formations per block from the lower third.

## POINTS TO CONSIDER

- Surgical resections of mandibular-facial bony structures, which may be bulky and include different anatomical components.
- Proper orientation of the specimen is important, guided by markers and osseous and soft tissue anatomical structures.
- Review of the clinical history and radiological studies before specimen handling is recommended in order to determine lesion location, bone infiltration, multifocality, or other associated lesions.
- Orient and measure the specimen, identifying the different anatomical components.
- Macroscopically identify the lesion, attempting to determine whether it involves the anatomical structures present (bone, soft tissues, etc.).
- Ink surgical margins; before sawing the bone, it is recommended to submit one or two sections of the lesion in relation to mucosa / soft tissue (if possible), in order to obtain tumour representation without damage caused by decalcifying chemical agents.
- Serially section the specimen; assess lesion thickness and infiltration of the different components.
- When serially sectioning the bone, confirm that the specimen is adequately fixed. If not, continue fixation in formaldehyde before decalcification. Generally, the more infiltrated / neoplastic the bone tissue is, the shorter the decalcification time required.
- Submit representative sections:
  - Include soft tissue / mucosal margins and bony margins (transverse or perpendicular).
  - As a rule, submit at least one section per centimetre of the greatest dimension of the lesion.
  - Submit non-decalcified sections of the lesion, with better tissue preservation.
  - Include sections of the lesion in relation to bone tissue.
  - Teeth may be decalcified.
  - If prosthetic devices are identified (for example: dental implants), they should not be submitted, as they are unsuitable for histological processing.
  - If a neck dissection is included, submit lymph nodes and sections of the submandibular gland parenchyma.

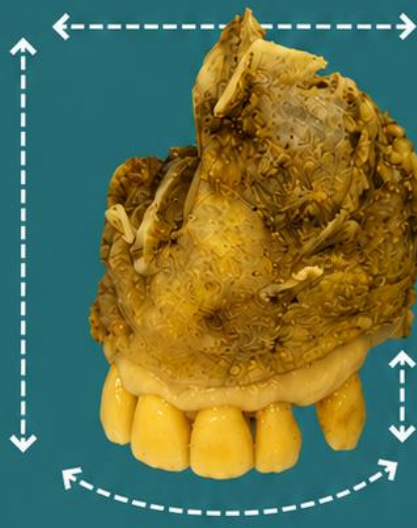


## Mandibulectomy for squamous cell carcinoma

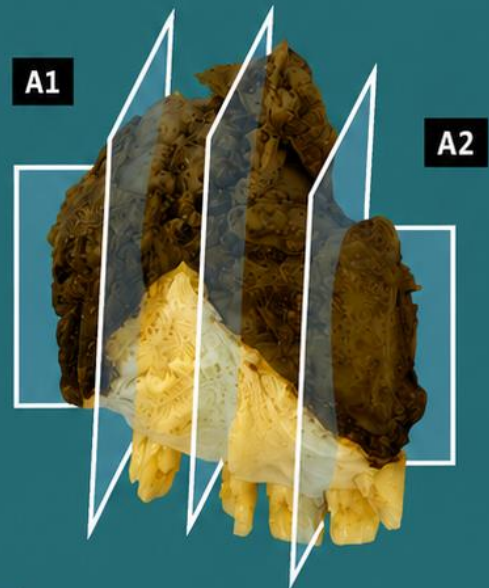


1. Orientate and measure the specimen
2. Measure external lesions (if visible), including distance to the margins
3. Describe external lesions (if visible)
4. Indicate margin(s) / surgical margin(s)
5. Serially section the specimen; measure the thickness and indicate distance to the deep margin and whether bone invasion is present
6. Describe the cut surface
7. Decalcify if required
8. Include representative sections

## Maxillectomy for adenoid cystic carcinoma



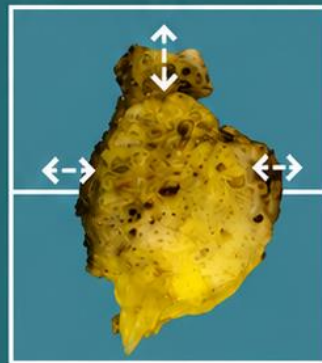
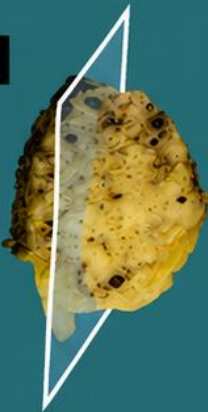
*Emilio I. Abecia*




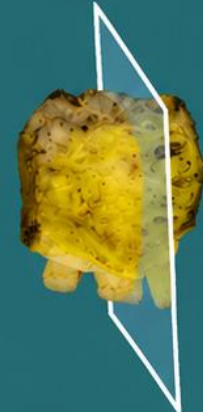
A3 - A4


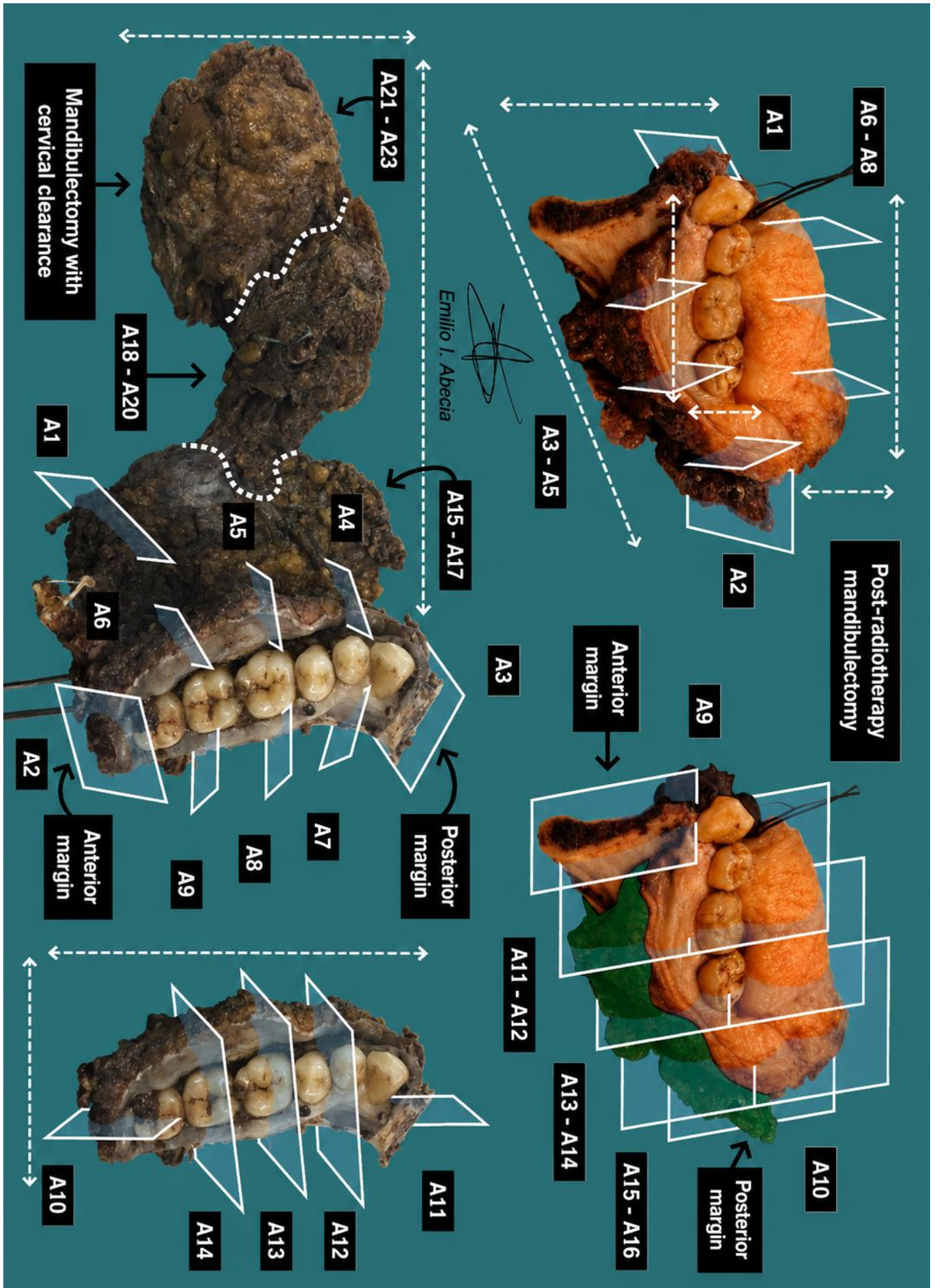
A5 - A6

A1



A2





## BIBLIOGRAPHY

- Cipriani N., Rose S. (2019). *Mandible (Head & Neck)*. Gross Pathology Manual (University Of Chicago). Recuperado el 13 de Mayo de 2024: <https://voices.uchicago.edu/grosspathology/head-neck/mandible/>
- Cipriani N., Rose S. (2019). *Maxilla (Head & Neck)*. Gross Pathology Manual (University Of Chicago). Recuperado el 13 de Mayo de 2024: <https://voices.uchicago.edu/grosspathology/head-neck/maxilla/>
- *Mandibulectomy (Head and Neck)*. Gross Manual. UCLA Health. Recuperado el 13 de Mayo de 2024: <https://www.uclahealth.org/sites/default/files/documents/Mandibulectomy%2002.28.22.pdf>
- *Maxillectomy (Head and Neck)*. Gross Manual. UCLA Health. Recuperado el 13 de Mayo de 2024: <https://www.uclahealth.org/sites/default/files/documents/Maxillectemey.pdf>
- Laurini J.A (2021). *Bone, Resection (v4.1.1.0)*. College of American Pathologists (CAP). Recuperado el 13 de Mayo de 2024: [https://documents.cap.org/protocols/Bone\\_4.1.1.0.REL\\_CAPCP.pdf?\\_gl=1\\*1amiq5\\*\\_ga\\*MTc4Nzk0MDczNC4xNzE0NDczNzAy\\*\\_ga\\_97ZFJSQQ0X\\*MTcxNDQ3MzcwMi4xLjEuMTcxNDQ3NDExMy4wLjAuMA](https://documents.cap.org/protocols/Bone_4.1.1.0.REL_CAPCP.pdf?_gl=1*1amiq5*_ga*MTc4Nzk0MDczNC4xNzE0NDczNzAy*_ga_97ZFJSQQ0X*MTcxNDQ3MzcwMi4xLjEuMTcxNDQ3NDExMy4wLjAuMA)
- Seethala R.R., Shon W., Balzer B.L., Duvvuri U., Gharavi N.M., Lydiatt W. (2023). *Cutaneous Squamous Cell Carcinoma (v1.0.0.1)*. College of American Pathologists (CAP). Recuperado el 13 de Mayo de 2024: [https://documents.cap.org/protocols/HN.SCC\\_1.0.0.1.REL\\_CAPCP.pdf?\\_gl=1\\*ow5hb1\\*\\_ga\\*MTc4Nzk0MDczNC4xNzE0NDczNzAy\\*\\_ga\\_97ZFJSQQ0X\\*MTcxNDQ3MzcwMi4xLjEuMTcxNDQ3NDExMy4wLjAuMA](https://documents.cap.org/protocols/HN.SCC_1.0.0.1.REL_CAPCP.pdf?_gl=1*ow5hb1*_ga*MTc4Nzk0MDczNC4xNzE0NDczNzAy*_ga_97ZFJSQQ0X*MTcxNDQ3MzcwMi4xLjEuMTcxNDQ3NDExMy4wLjAuMA)
- Seethala R.R., Bishop J.A., Faquin W.C., Hui Huang S., Katabi N., Lydiatt W., O'Sullivan B., Patel S., Pettus J.R, Williams L. (2023). *Nasal Cavity and Paranasal Sinuses (v4.2.0.0)*. College of American Pathologists (CAP). Recuperado el 13 de Mayo de 2024: [https://documents.cap.org/protocols/HN.Nasal\\_4.2.0.0.REL\\_CAPCP.pdf?\\_gl=1\\*h2tafb\\*\\_ga\\*MTc4Nzk0MDczNC4xNzE0NDczNzAy\\*\\_ga\\_97ZFJSQQ0X\\*MTcxNDQ3MzcwMi4xLjEuMTcxNDQ3NDExMy4wLjAuMA](https://documents.cap.org/protocols/HN.Nasal_4.2.0.0.REL_CAPCP.pdf?_gl=1*h2tafb*_ga*MTc4Nzk0MDczNC4xNzE0NDczNzAy*_ga_97ZFJSQQ0X*MTcxNDQ3MzcwMi4xLjEuMTcxNDQ3NDExMy4wLjAuMA)
- WHO Classification of Tumours Editorial Board (2024). *Head and Neck Tumours* (5th ed., vol. 9). International Agency for Research on Cancer. <https://publications.iarc.fr/Book-And-Report-Series/Who-Classification-Of-Tumours/Head-And-Neck-Tumours-2024>
- Lemos, M. B., & Okoye, E. (2019). *Atlas of Surgical Pathology Grossing*. Springer Nature Switzerland AG. <https://link.springer.com/book/10.1007/978-3-030-20839-4>
- Susan C. Lester, French, C. A., & Curtis, S. G. (2010). *Manual of Surgical Pathology: Expert Consult* (ed. 3). Elsevier. <https://www.sciencedirect.com/book/9780323065160/manual-of-surgical-pathology>
- Shameem Shariff. (2019). *Fundamentals of Surgical Pathology (ed.2)*. Jaypee Brothers Medical Publishers. <https://www.jaypeedigital.com/book/9789388958967>
- Westra, W. H., Ralph H. Hruban, Timothy H. Phelps, & Christina Iacson. (2003). *Surgical Pathology Dissection: An Illustrated Guide (ed.2)*. Springer. <https://link.springer.com/book/10.1007/b97473>

## DISCLAIMER

The image and text are provided for illustrative purposes only. The tissue sections submitted and the description provided will depend on the individual specimen characteristics, the clinical diagnostic suspicion, the experience of the dissector, and the institutional guidelines of the laboratory.

This document has been translated from the original Spanish version using AI-based tools. The text may contain typographical errors or inaccurate translations.

Emilio I. Abecia Martínez

