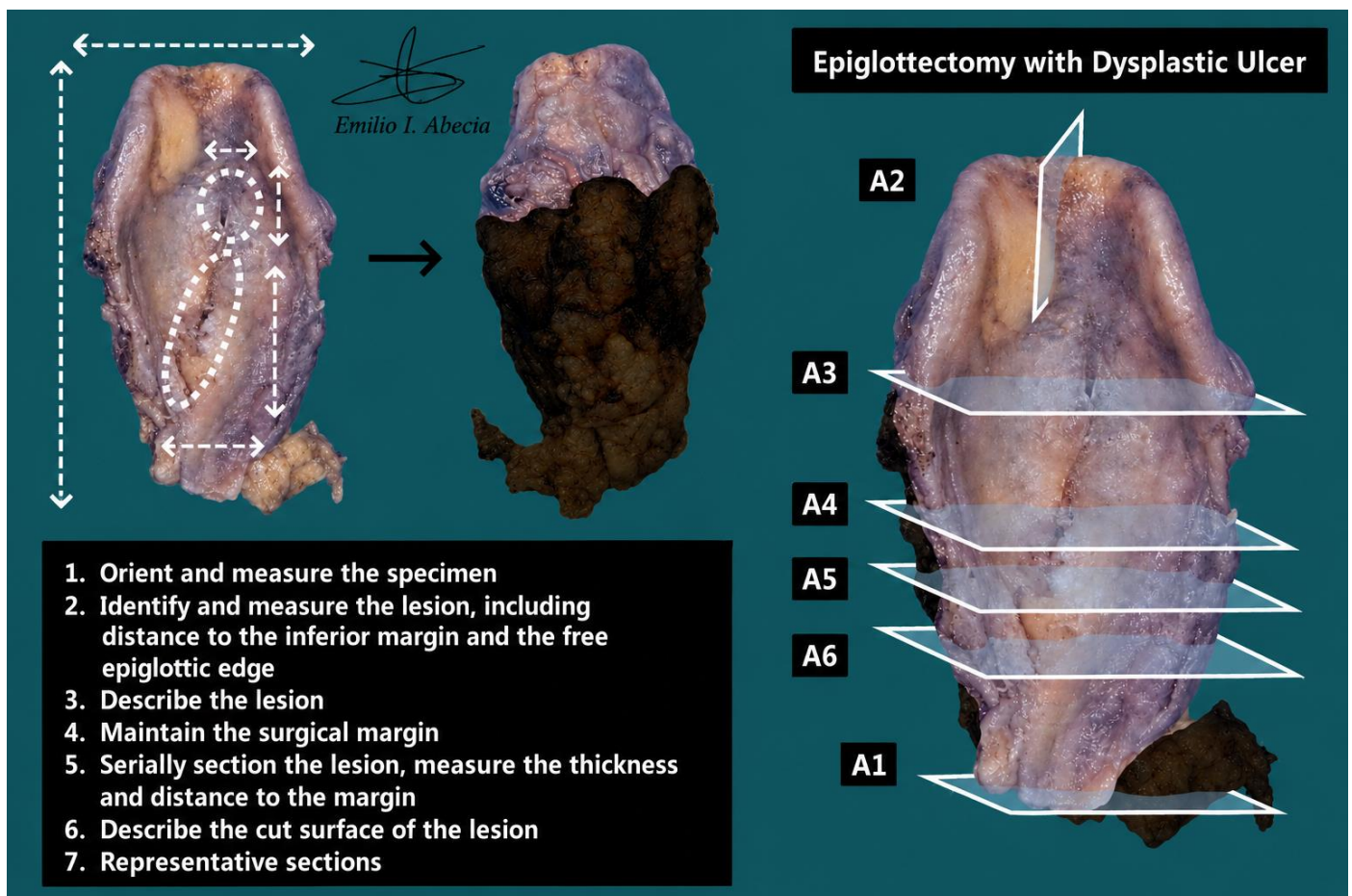


EPIGLOTTECTOMY

1. An epiglottectomy specimen measuring XXX cm is received.
2. Externally, no features are identified // a superficial lesion measuring X cm in diameter is identified, located X cm from the inferior margin and X cm from the free epiglottic edge.
3. The lesion is flat / exophytic / ulcerated, with an indurated / soft-elastic consistency and a brownish / whitish / haemorrhagic / etc. coloration.
4. The soft tissue margin is inked.
5. On sectioning, has a thickness of X cm and is located X cm from the soft tissue margin.
6. The lesion shows a heterogeneous / homogeneous cut surface, brownish / whitish in colour, with well / poorly defined borders and areas of haemorrhage / necrosis comprising X% of the lesion volume.
7. Representative sections are submitted as follows:
 - A1: inferior surgical margin.
 - A2: section from the free epiglottic edge.
 - A3–A6: transverse sections from superior to inferior in relation to the deep margin.

TO CONSIDER

- Epiglottic resections performed for dysplastic lesions / squamous cell carcinomas located in the supraglottic region, with the possibility of avoiding total laryngectomy. Clinical history should be reviewed to confirm the indication for surgery.
- Orient and measure the specimen and lesion(s), including their distance to surgical margins.
- Ink the surgical margin and serially section the specimen; measure lesion thickness, distance to the deep / soft tissue margin, and describe the cut surface.
- Submit sections including:
 - Surgical margins.
 - At least one section per centimetre of the greatest dimension of the lesion.



BIBLIOGRAPHY

- Cipriani N., Rose S. (2019). *Larynx (Head & Neck)*. Gross Pathology Manual (University Of Chicago). Recuperado el 13 de Mayo de 2024: <https://voices.uchicago.edu/grosspathology/head-neck/larynx/>
- UCLA Health. *Laryngectomy (Total & Hemi) (Head and Neck)*. Gross Manual. UCLA Health. Recuperado el 13 de Mayo de 2024: <https://www.uclahealth.org/sites/default/files/documents/LaryngectomyTotalandHemi060519.pdf>
- Seethala R.R., Bishop J.A., Faquin W.C., Hui Huang S., Katabi N., Lydiatt W., O'Sullivan B., Patel S., Pettus J.R., Williams L. (2023). *Larynx* (v4.2.0.0). College of American Pathologists (CAP). Recuperado el 13 de Mayo de 2024: https://documents.cap.org/protocols/HN.Larynx_4.2.0.0.REL_CAPCP.pdf?_gl=1*h2tafb*_ga*MTc4Nzk0MDczNC4xNzE0NDczNzAy*_ga_97ZFJSQQ0X*MTcxNDQ3MzcwMi4xLjEuMTcxNDQ3NDExMy4wLjAuMA
- WHO Classification of Tumours Editorial Board (2024). *Head and Neck Tumours* (5th ed., vol. 9). International Agency for Research on Cancer. <https://publications.iarc.fr/Book-And-Report-Series/Who-Classification-Of-Tumours/Head-And-Neck-Tumours-2024>
- Lemos, M. B., & Okoye, E. (2019). *Atlas of Surgical Pathology Grossing*. Springer Nature Switzerland AG. <https://link.springer.com/book/10.1007/978-3-030-20839-4>
- Susan C. Lester, French, C. A., & Curtis, S. G. (2010). *Manual of Surgical Pathology: Expert Consult* (ed. 3). Elsevier. <https://www.sciencedirect.com/book/9780323065160/manual-of-surgical-pathology>
- Shameem Shariff. (2019). *Fundamentals of Surgical Pathology* (ed.2). Jaypee Brothers Medical Publishers. <https://www.jaypeedigital.com/book/9789388958967>
- Westra, W. H., Ralph H. Hruban, Timothy H. Phelps, & Christina Iacson. (2003). *Surgical Pathology Dissection: An Illustrated Guide* (ed.2). Springer. <https://link.springer.com/book/10.1007/b97473>

DISCLAIMER

The image and text are provided for illustrative purposes only. The tissue sections submitted and the description provided will depend on the individual specimen characteristics, the clinical diagnostic suspicion, the experience of the dissector, and the institutional guidelines of the laboratory.

This document has been translated from the original Spanish version using AI-based tools. The text may contain typographical errors or inaccurate translations.

