

NON-NEOPLASTIC GASTRECTOMY

1. A partial / sleeve / total gastrectomy specimen measuring XXX cm is received // accompanied by greater omentum / lesser omentum / a segment of oesophagus measuring XXX cm.
2. Externally, the serosal surface is unremarkable // the serosa appears congested / ischaemic // a defect measuring XXX cm is identified, located in the X third.
3. On opening, the mucosa shows preserved rugal folds, without other remarkable features // an area of erythematous / atrophic / granular mucosa is identified, located in the upper / middle / lower third // a lesion measuring XXX cm is identified, with X location and characteristics.
4. Representative sections are submitted as follows:

1st Example (Bariatric surgery stomach):


- A1: representative section from the upper third.
- A2: representative section from the middle third.
- A3: representative section from the lower third.
- A4: incidental lesions (if present).


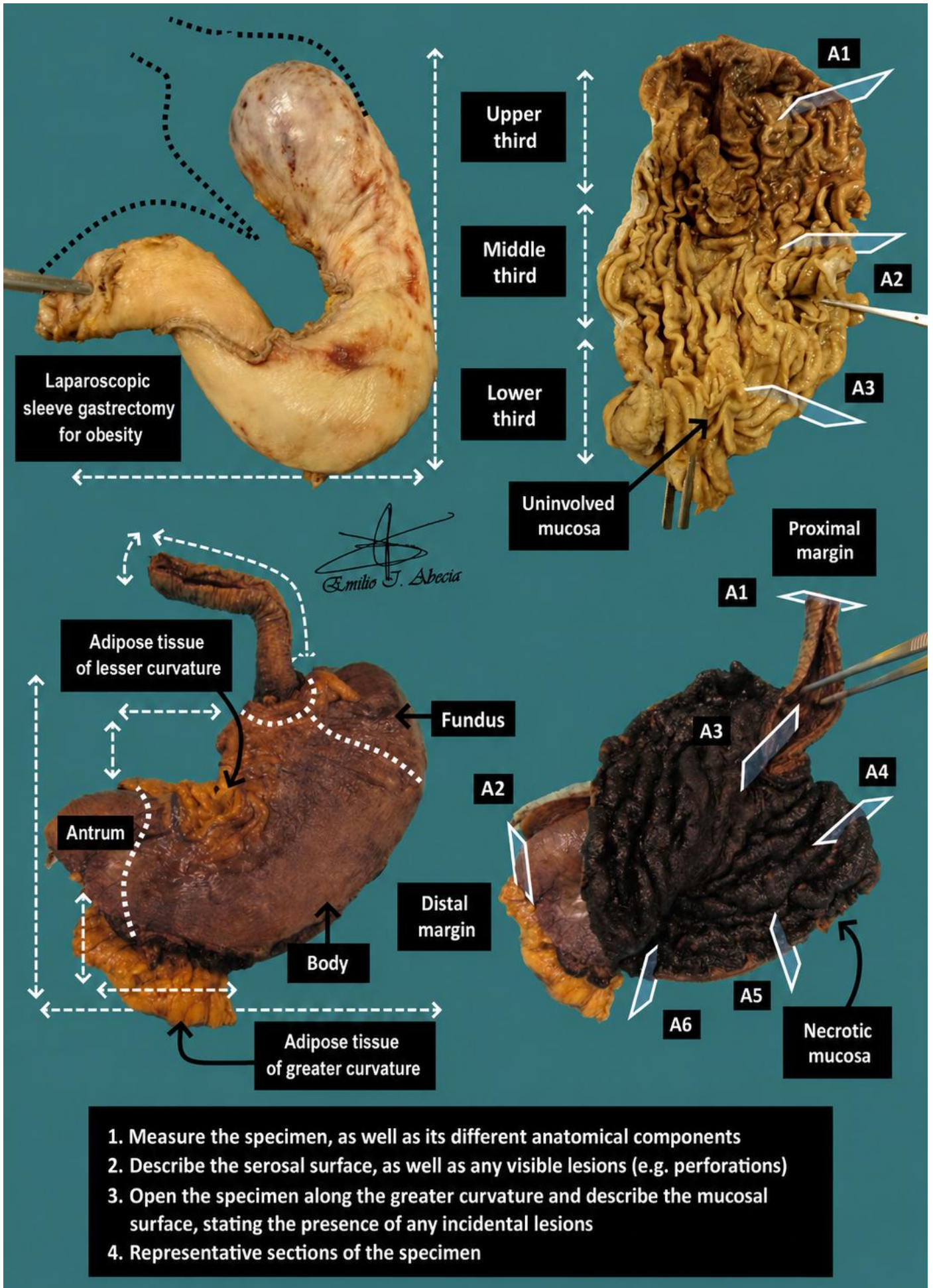
2nd Example (Stomach with caustic necrosis):

- A1: proximal margin.
- A2: distal margin.
- A3: oesophageal section at the gastro-oesophageal junction.
- A4: fundus section.
- A5: body section.
- A6: antral section.
- A7: incidental lesions (if present).

TO CONSIDER

- Most non-neoplastic gastrectomies are performed for bariatric surgery, generally with limited histological and diagnostic significance.
- If performed for another indication (ulcers, perforations, anastomoses, etc.), review of the clinical history is recommended.
- Measure, orientate, and describe the external surface of the specimen.
- Gastrectomy specimens are opened longitudinally along the greater curvature (generally where the staple line is located).
- Describe the internal surface and any incidental findings identified.
- Submit representative sections:
 - Include schematic representation of gastric wall sections.
 - If incidental lesions or alterations are identified, submit a couple of representative sections.





BIBLIOGRAPHY

- Cipriani N., Rose S. (2019). *Stomach (Non-Neoplastic)*. Gross Pathology Manual (University of Chicago). Recuperado el 13 de Mayo de 2024: <https://voices.uchicago.edu/grosspathology/gi-liver/stomach-non-neoplastic/>
- *Sleeve Gastrectomy (Gastrointestinal)*. Gross Manual. UCLA Health. Recuperado el 13 de Mayo de 2024: <https://www.uclahealth.org/sites/default/files/documents/63/sleeve-gastrectomy-2123.pdf?f=9fc56d96>
- Lemos, M. B., & Okoye, E. (2019). *Atlas of Surgical Pathology Grossing*. Springer Nature Switzerland AG. <https://link.springer.com/book/10.1007/978-3-030-20839-4>
- Susan C. Lester, French, C. A., & Curtis, S. G. (2010). *Manual of Surgical Pathology: Expert Consult* (ed. 3). Elsevier. <https://www.sciencedirect.com/book/9780323065160/manual-of-surgical-pathology>
- Shameem Shariff. (2019). *Fundamentals of Surgical Pathology* (ed.2). Jaypee Brothers Medical Publishers. <https://www.jaypeedigital.com/book/9789388958967>
- Westra, W. H., Ralph H. Hruban, Timothy H. Phelps, & Christina Iacono. (2003). *Surgical Pathology Dissection: An Illustrated Guide* (ed.2). Springer. <https://link.springer.com/book/10.1007/b97473>

DISCLAIMER

The image and text are provided for illustrative purposes only. The tissue sections submitted and the description provided will depend on the individual specimen characteristics, the clinical diagnostic suspicion, the experience of the dissector, and the institutional guidelines of the laboratory.

This document has been translated from the original Spanish version using AI-based tools. The text may contain typographical errors or inaccurate translations.

