

HIRSCHSPRUNG DISEASE

1. An intestinal segment measuring X cm in length is received, without orientation provided // oriented with X marking the X margin.
2. Externally, no remarkable features are identified // variability in the thickness of the specimen is recognised, with dilated and stenotic areas measuring X cm in length respectively // a defect measuring XXX cm is identified, located X cm from the nearest margin.
3. On opening and sectioning, no remarkable features are identified // an atrophic / hypertrophic bowel wall is identified, corresponding to the dilated / stenotic area.
4. Representative sections are submitted as follows:

1st Example (Intestinal resection for Hirschsprung disease):

- A1: proximal surgical margin.
- A2: distal surgical margin.
- A3 to A6: longitudinal sections of the specimen, from proximal to distal.

2nd Example (Intestinal resection for Hirschsprung disease):

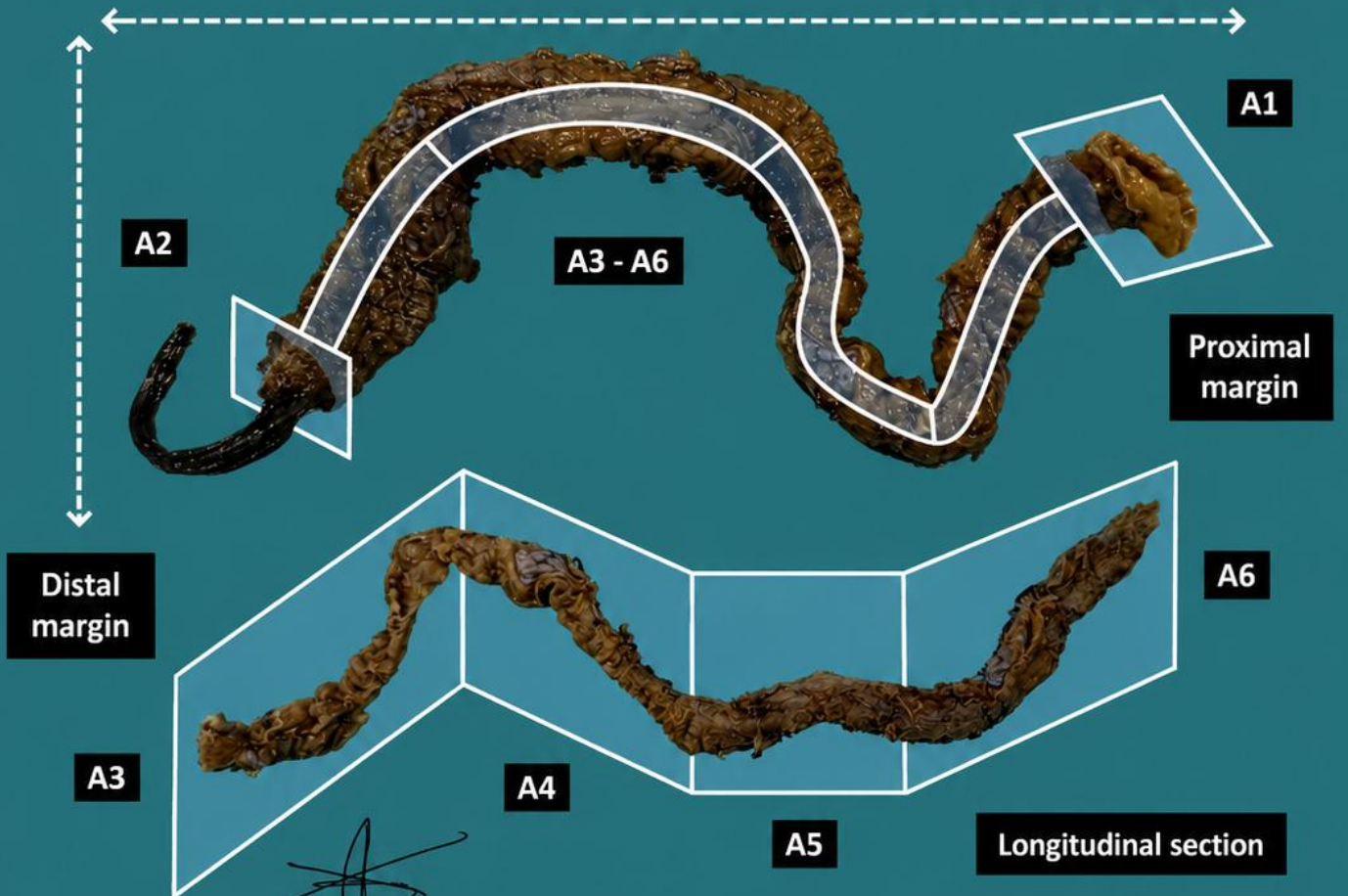

- A1: proximal surgical margin.
- A2: distal surgical margin.
- A3 - A6: one longitudinal section of the specimen, from proximal to distal.

TO CONSIDER

- Paediatric intestinal resections performed for absence of ganglion cells in the colon, generally preceded by intraoperative biopsies to determine the appropriate surgical level of resection.
- Identify the proximal and distal margins using possible surgical markers or anatomical landmarks.
- Measure the specimen and describe the external surface.
- Open longitudinally and describe the internal surface.
- Submit representative sections:
 - Submit the resection ends entirely and circumferentially.
 - As it is important to document the length of the aganglionic segment, the specimen should be submitted longitudinally, indicating the orientation (from proximal to distal or vice versa).
 - Attempt to include at least one complete cross-section.
 - If two sections are submitted in the same block, the most proximal and the most distal sections should be identified with notches or ink.


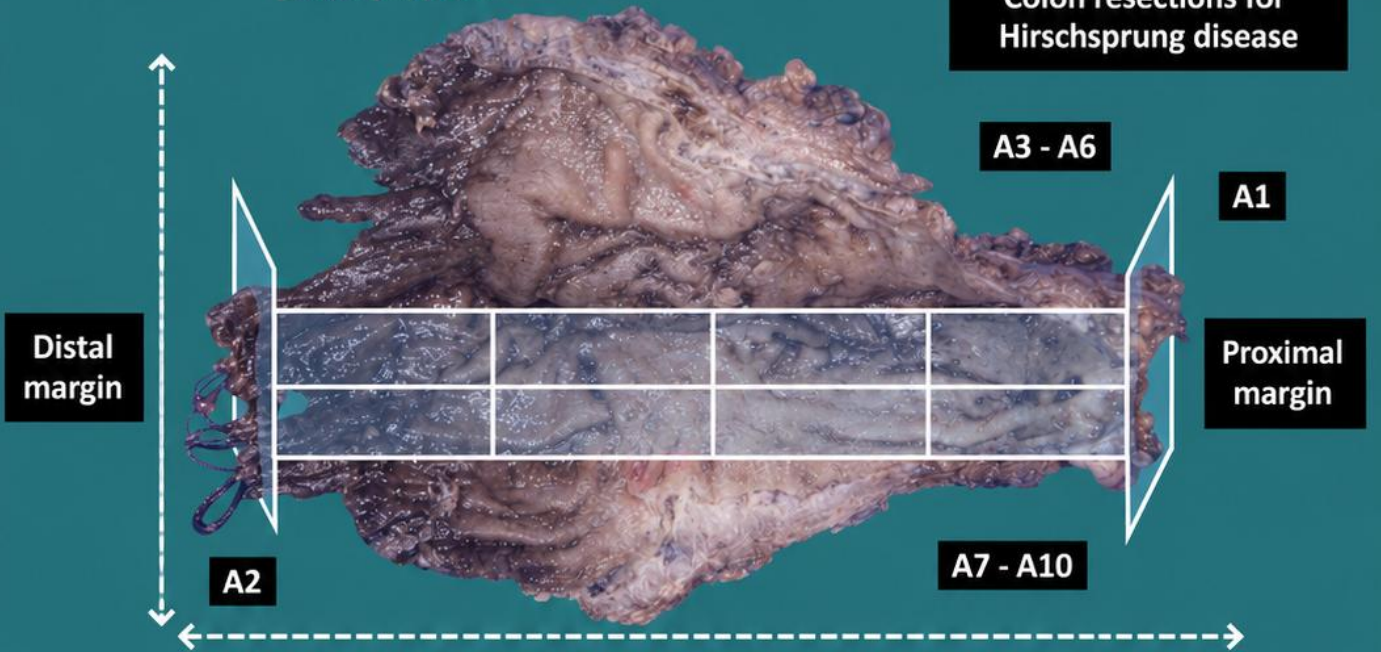


1. Orient and measure the specimen
2. Describe the external surface of the specimen
3. Open the specimen longitudinally and describe any observable abnormalities
4. Representative sections (margins and longitudinal section)



Emilio J. Abecia

Colon resections for Hirschsprung disease



BIBLIOGRAPHY

- Cipriani N., Rose S. (2019). *Hirschsprung Disease*. Gross Pathology Manual (University of Chicago). Recuperado el 13 de Mayo de 2024: <https://voices.uchicago.edu/grosspathology/peds-perinatal/hirschsprung-disease>
- *Hirschsprung Disease (Gastrointestinal)*. Gross Manual. UCLA Health. Recuperado el 13 de Mayo de 2024: <https://www.uclahealth.org/sites/default/files/documents/70/hirschsprung-disease-020223.pdf?f=3837a247>
- Lemos, M. B., & Okoye, E. (2019). *Atlas of Surgical Pathology Grossing*. Springer Nature Switzerland AG. <https://link.springer.com/book/10.1007/978-3-030-20839-4>
- Susan C. Lester, French, C. A., & Curtis, S. G. (2010). *Manual of Surgical Pathology: Expert Consult* (ed. 3). Elsevier. <https://www.sciencedirect.com/book/9780323065160/manual-of-surgical-pathology>
- Shameem Shariff. (2019). *Fundamentals of Surgical Pathology* (ed.2). Jaypee Brothers Medical Publishers. <https://www.jaypeedigital.com/book/9789388958967>
- Westra, W. H., Ralph H. Hruban, Timothy H. Phelps, & Christina Iacson. (2003). *Surgical Pathology Dissection: An Illustrated Guide* (ed.2). Springer. <https://link.springer.com/book/10.1007/b97473>

DISCLAIMER

The image and text are provided for illustrative purposes only. The tissue sections submitted and the description provided will depend on the individual specimen characteristics, the clinical diagnostic suspicion, the experience of the dissector, and the institutional guidelines of the laboratory.

This document has been translated from the original Spanish version using AI-based tools. The text may contain typographical errors or inaccurate translations.

