


DISTAL DIGIT RESECTION

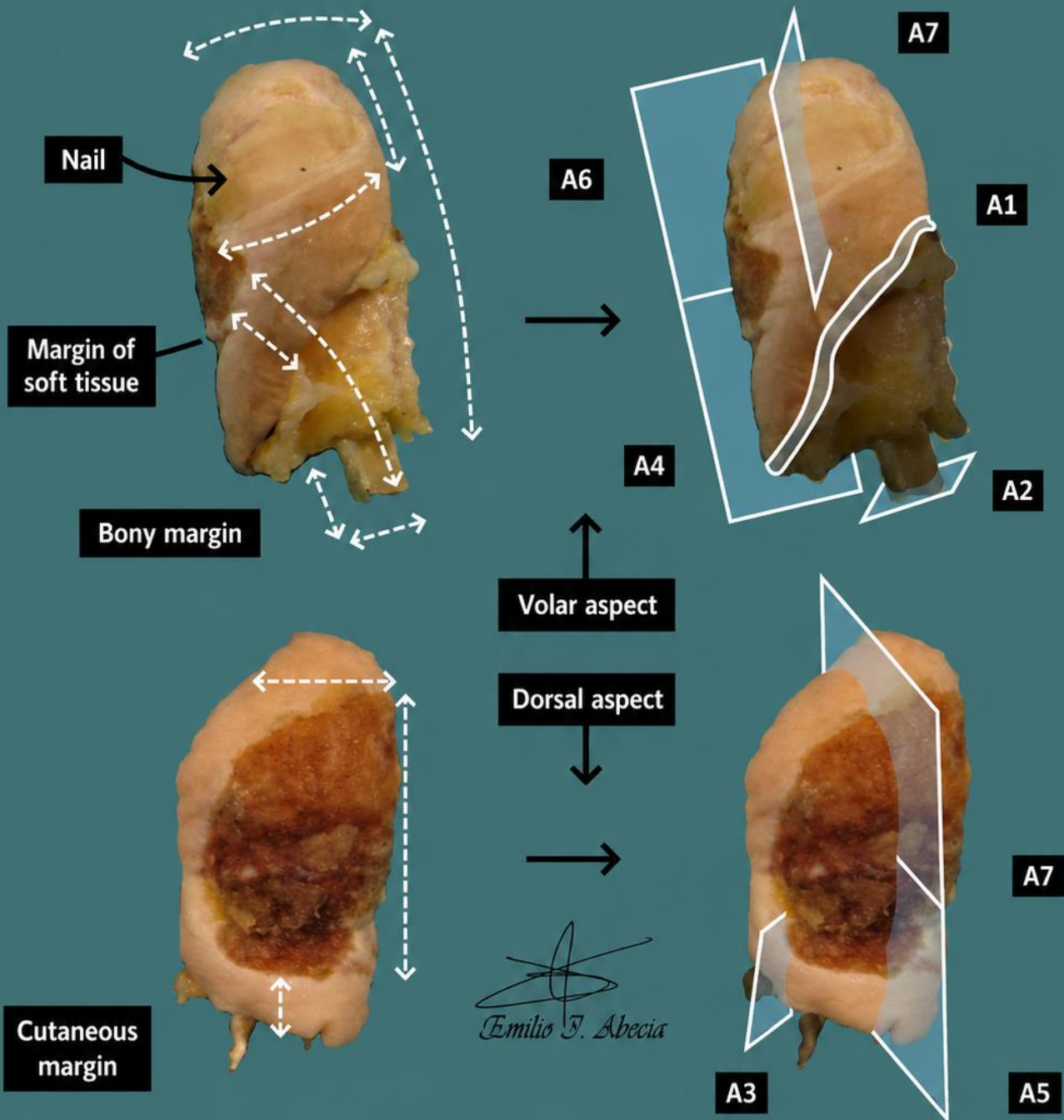
1. A distal resection of the X finger of the right / left hand is received, measuring XXX cm, with nail measuring XXX cm / tendon / soft tissue / vascular pedicle / bone measuring XXX cm.
2. Externally, no remarkable features are identified // a lesion measuring XXX cm is identified on the volar / dorsal aspect, located X cm from the cutaneous margin / bony margin / articular margin / soft tissue margin / etc.
3. The lesion has an ischaemic / flat / raised appearance, with soft / indurated consistency, whitish / brownish coloration, and an ulcerated / crusted / irregular / etc. surface.
4. The surgical margin is inked with India ink.
5. On longitudinal sectioning, the lesion measures X cm in thickness, lies X cm from the soft tissue margin / bony margin, and appears / does not appear to involve the nail / soft tissues / bone tissue / vascular structures / etc.
6. The cut surface is homogeneous / heterogeneous, brown / whitish in colour, with well-defined / poorly defined borders / etc.
7. Bone tissue is decalcified in X at X% (if required) // nail tissue is processed in potassium hydroxide (if required).
8. Representative sections are submitted as follows:
 - A1: radial cutaneous surgical margin.
 - A2: bony margin / tendon.
 - A2: lesion in relation to the surgical margin.
 - A3–A5: sections of the lesion in relation to the cutaneous / soft tissue margin.
 - A6–A7: sections of the lesion in relation to the nail.

TO CONSIDER


- Distal phalangeal amputations (hands or feet) performed for various neoplastic (carcinomas or sarcomas) or traumatic / inflammatory conditions (diabetic foot, gangrene, osteomyelitis, etc.).
- Clinical history review is recommended to determine the surgical indication.
- Orient and measure the anatomical structures present, as well as any identified lesions and their distance to the margins.
- Ink soft tissue / articular / bony margins.
- Section the specimen longitudinally. Localise and measure the lesion, and indicate involvement of anatomical structures.
- Submit representative sections:
 - Submit cutaneous, soft tissue, articular, bony, vascular bundle, etc. resection margins en face (shave sections).
 - Submit representative sections of the lesion in relation to margins and adjacent structures (skin, nail, bone, soft tissue, etc.).
 - As a general rule, include at least one section per centimetre of the greatest dimension of the lesion.
 - For adequate processing, the nail should be treated with substances such as potassium hydroxide.
 - Bone tissue must also be decalcified to allow sectioning with a microtome.



Excision of digit with epidermoid carcinoma



1. Orientate and measure the specimen, including anatomical structures (nail, bone)
2. Measure and describe external lesions (if visible), and distance to margins
3. Describe the morphology of the lesion
4. Ink surgical margin
5. Section the specimen longitudinally; measure lesion thickness, distance to margins (bone and soft tissue), and level of infiltration of structures
6. Describe the cut surface
7. Decalcify bone tissue / process nail unit tissue if required
8. Include representative sections



BIBLIOGRAPHY

- *Bone Resection (Neoplastic) (Bone and Soft Tissue)*. Gross Manual. UCLA Health. Recuperado el 13 de Mayo de 2024: <https://www.uclahealth.org/sites/default/files/documents/75/bone-resection-neoplastic.pdf?f=a54bfeb7>
- Seethala R.R., Shon W., Balzer B.L., Duvvuri U., Gharavi N.M., Lydiatt W. (2023). *Cutaneous Squamous Cell Carcinoma* (v1.0.0.1). College of American Pathologists (CAP). Recuperado el 13 de Mayo de 2024: https://documents.cap.org/protocols/HN.SCC_1.0.0.1.REL_CAPCP.pdf?_gl=1*ow5hb1*_ga*MTc4Nzk0MDczNC4xNzE0NDczNzAy*_ga_97ZFJSQQ0X*MTcxNDQ3MzcxwMi4xLjEuMTcxNDQ3NDExMy4wLjAuMA
- WHO Classification of Tumours Editorial Board (2020). *Soft Tissue and Bone Tumours* (5th ed.; vol. 3). International Agency for Research on Cancer. <https://publications.iarc.fr/Book-And-Report-Series/Who-Classification-Of-Tumours/Soft-Tissue-And-Bone-Tumours-2020>
- Lemos, M. B., & Okoye, E. (2019). *Atlas of Surgical Pathology Grossing*. Springer Nature Switzerland AG. <https://link.springer.com/book/10.1007/978-3-030-20839-4>
- Susan C. Lester, French, C. A., & Curtis, S. G. (2010). *Manual of Surgical Pathology: Expert Consult* (ed. 3). Elsevier. <https://www.sciencedirect.com/book/9780323065160/manual-of-surgical-pathology>
- Shameem Shariff. (2019). *Fundamentals of Surgical Pathology* (ed.2). Jaypee Brothers Medical Publishers. <https://www.jaypeedigital.com/book/9789388958967>
- Westra, W. H., Ralph H. Hruban, Timothy H. Phelps, & Christina Iacson. (2003). *Surgical Pathology Dissection: An Illustrated Guide* (ed.2). Springer. <https://link.springer.com/book/10.1007/b97473>

DISCLAIMER

The image and text are provided for illustrative purposes only. The tissue sections submitted and the description provided will depend on the individual specimen characteristics, the clinical diagnostic suspicion, the experience of the dissector, and the institutional guidelines of the laboratory.

This document has been translated from the original Spanish version using AI-based tools. The text may contain typographical errors or inaccurate translations.

