

TRAUMA / NON-NEOPLASTIC AMPUTATION

1. A resection / amputation specimen of X is received, measuring XXX cm // consisting of a finger / hand / foot / thigh / leg / forearm / arm measuring XXX cm.
2. Externally, no remarkable features are identified // a hemorrhagic / necrotic / ragged surface or capsule / a perforation measuring XX cm is identified // an irregular and disrupted surface involving the skin / parenchyma / capsule / joint / muscle / bone, consistent with traumatic injury, is identified.
3. On serial sectioning, the cut surface is unremarkable // the cut surface shows hemorrhagic / necrotic / fibrinopurulent changes / fragmentation of the bony tissue / X thrombosed vascular structures are identified / etc.
4. Decalcification is performed in X at X%.
5. Representative sections are submitted as follows:

1st Example (Traumatic Foot Amputation):

- A1: surgical margin.
- A2 – A4: representative sections of the specimen.

2nd Example (Traumatic Splenic Capsular Rupture):

- A1: splenic hilar surgical margin.
- A2 – A3: representative sections of the specimen.

3rd Example (Traumatic Finger Amputation):


- A1: distal surgical margin.
- A2 – A3: representative sections of the specimen.

4th Example (Hand Amputation Due to Occupational Accident):

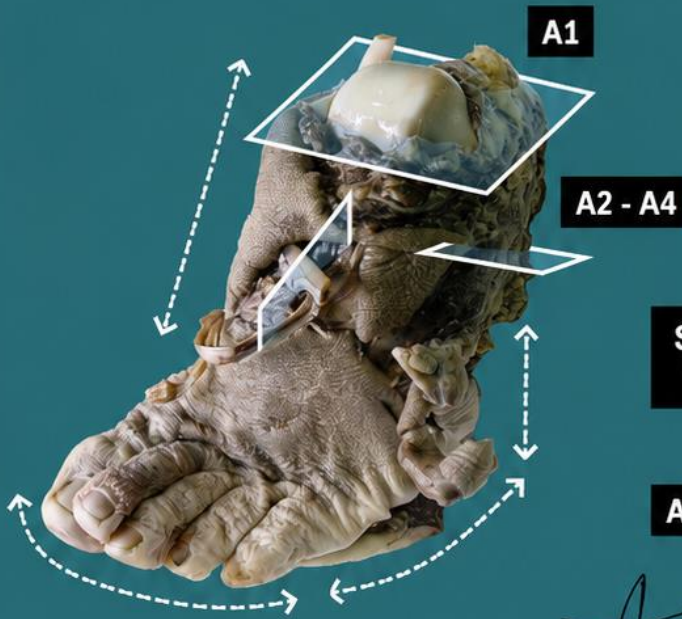
- A1: bony / soft tissue surgical margin.
- A2 – A3: representative sections of the specimen.

TO CONSIDER

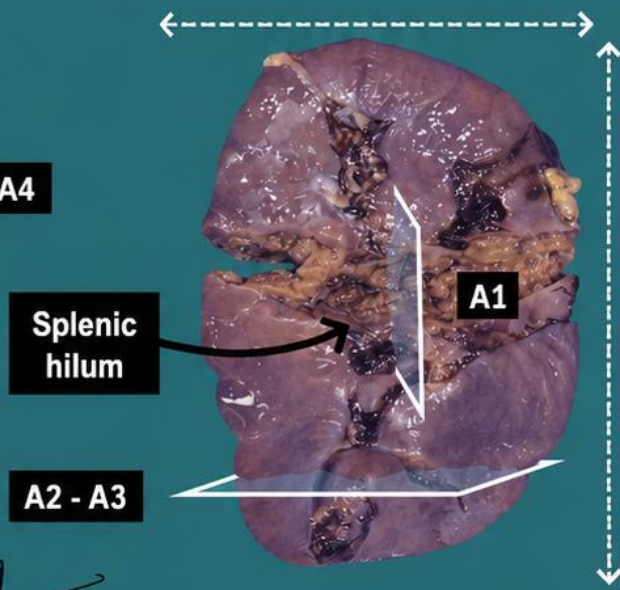
- Resections of internal or external anatomical structures (splenic or hepatic capsular rupture, hand amputations, limb amputations, etc.), generally secondary to traumatic injury.
- These are surgical specimens with limited histological significance, apart from generic and nonspecific findings (hemorrhage, ischaemia, granulation tissue, etc.).
- Document the specimen photographically (important for medicolegal purposes).
- Measure and describe external abnormalities.
- Serially section the specimen and submit a few representative sections:
 - Surgical margins.
 - Representative sections from different areas of bone tissue, vascular structures, skin, soft tissue, etc.
 - If additional abnormalities or incidental findings are identified, submit additional representative sections.
- It may be useful to document the submitted sections using a diagram or directly on the specimen photograph.



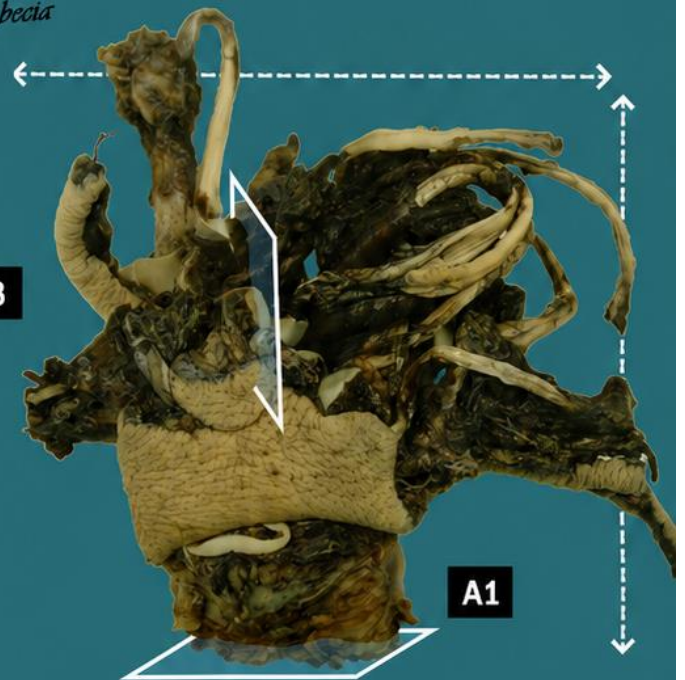
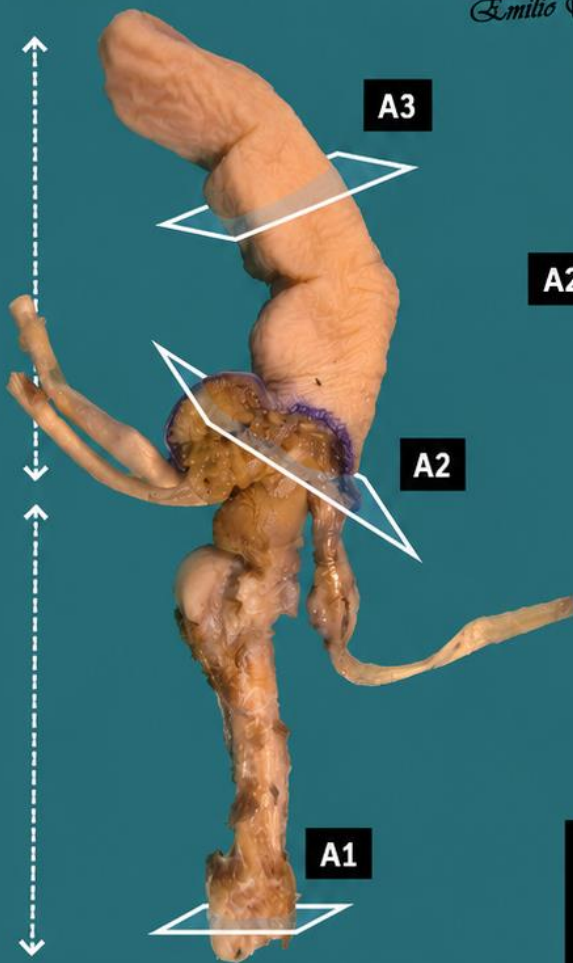
Traumatic amputation of the foot



Splenectomy for capsular rupture




Emilio I. Abecia



Traumatic amputation of a hand due to industrial accident

Traumatic amputation of a finger

1. Measure the specimen and its anatomical components
2. Describe external surface
3. Serial section and describe cut surface, including any abnormalities identified
4. Decalcify if required
5. Inclusions of representative sections



BIBLIOGRAPHY

- Cipriani N., Rose S. (2019). *Limb Amputation (Not Tumor) (Bone & Soft Tissue)*. Gross Pathology Manual (University Of Chicago). Recuperado el 13 de Mayo de 2024: [https://voices.uchicago.edu/grosspathology/bone-soft-tissue/amputation-limb-benign-disease/Lower/Upper Extremity \(Non-Neoplastic\) \(Bone and Soft Tissue\)](https://voices.uchicago.edu/grosspathology/bone-soft-tissue/amputation-limb-benign-disease/Lower/Upper%20Extremity%20(Non-Neoplastic)%20(Bone%20and%20Soft%20Tissue).Gross%20Manual.UCLA%20Health). Gross Manual. UCLA Health. Recuperado el 13 de Mayo de 2024: <https://www.uclahealth.org/sites/default/files/documents/d2/lowerupper-extremity-non-neoplastic-122022.pdf?f=8faabc69>
- Lemos, M. B., & Okoye, E. (2019). *Atlas of Surgical Pathology Grossing*. Springer Nature Switzerland AG. <https://link.springer.com/book/10.1007/978-3-030-20839-4>
- Susan C. Lester, French, C. A., & Curtis, S. G. (2010). *Manual of Surgical Pathology: Expert Consult* (ed. 3). Elsevier. <https://www.sciencedirect.com/book/9780323065160/manual-of-surgical-pathology>
- Shameem Shariff. (2019). *Fundamentals of Surgical Pathology* (ed.2). Jaypee Brothers Medical Publishers. <https://www.jaypeedigital.com/book/9789388958967>
- Westra, W. H., Ralph H. Hruban, Timothy H. Phelps, & Christina Iacson. (2003). *Surgical Pathology Dissection: An Illustrated Guide* (ed.2). Springer. <https://link.springer.com/book/10.1007/b97473>

DISCLAIMER

The image and text are provided for illustrative purposes only. The tissue sections submitted and the description provided will depend on the individual specimen characteristics, the clinical diagnostic suspicion, the experience of the dissector, and the institutional guidelines of the laboratory.

This document has been translated from the original Spanish version using AI-based tools. The text may contain typographical errors or inaccurate translations.

