

## SARCOMA (GENERIC)

1. A specimen designated as X is received, weighing X g and measuring XXX cm // oriented with X at X // accompanied by soft tissue / skeletal muscle / skin ellipse / adipose tissue measuring XXX cm.
2. Externally, no remarkable features are identified // the specimen shows a smooth / irregular / heterogeneous / homogeneous surface, with a cystic / solid appearance and brownish / whitish coloration // the skin ellipse / muscular tissue shows X features.
3. Surgical margin X is inked in X colour.
4. On serial sectioning, the lesion measures XXX cm // the lesion occupies the entire specimen and is in relation to the resection margins // it is located X cm from the X surgical margin // without infiltration / infiltrating the skin ellipse / muscular tissue / etc.
5. The lesion is encapsulated / pseudoencapsulated / encapsulated (capsule thickness measured), with a homogeneous / heterogeneous cut surface, X coloration, and a myxoid / solid / pseudonodular / indurated appearance, etc.
6. No necrosis is identified // foci of necrosis are identified, involving approximately X% of the lesion volume.
7. Representative sections are submitted as follows:

### 1st Example (Sarcoma: Tumourectomy)

- A1: inferior margin, en face.
- A2: superior margin, en face.
- A3–A6: one complete section of the lesion.
- A7–A10: second complete section of the lesion.
- A11–A12: additional sections from myxoid / solid areas.

### 2nd Example (Wide Sarcoma Resection)


- A1: posterior margin, en face.
- A2: anterior margin, en face.
- A4–A8: one complete section of the lesion.
- A9–A14: second complete section of the lesion.
- A15–A16: additional sections from margin X / in relation to muscle / adipose tissue.

### 3rd Example (Chondrosarcoma Resection)

- A1: lateral margin, en face.
- A2: contralateral margin, en face.
- A3–A6: one complete section of the specimen.
- A7–A8: additional sections of the lesion.


### 4th Example (Rhabdomyosarcoma Resection)


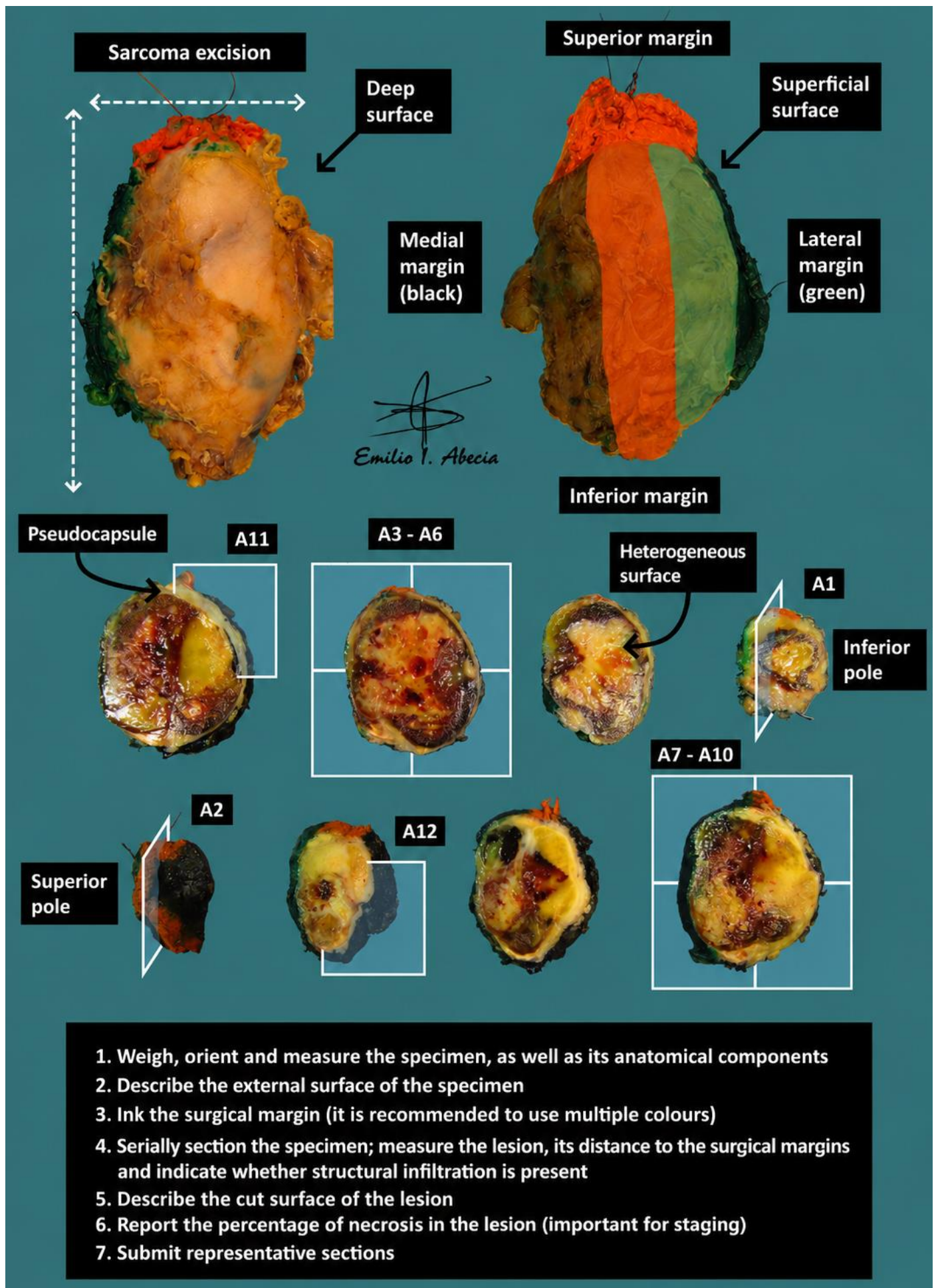
- A1: medial margin, en face.
- A2: lateral margin, en face.
- A3–A8: one complete section of the specimen.
- A9–A10: additional sections from margin X / in relation to muscle / adipose tissue.
- A11–A12: additional sections from margin X / in relation to muscle / adipose tissue.


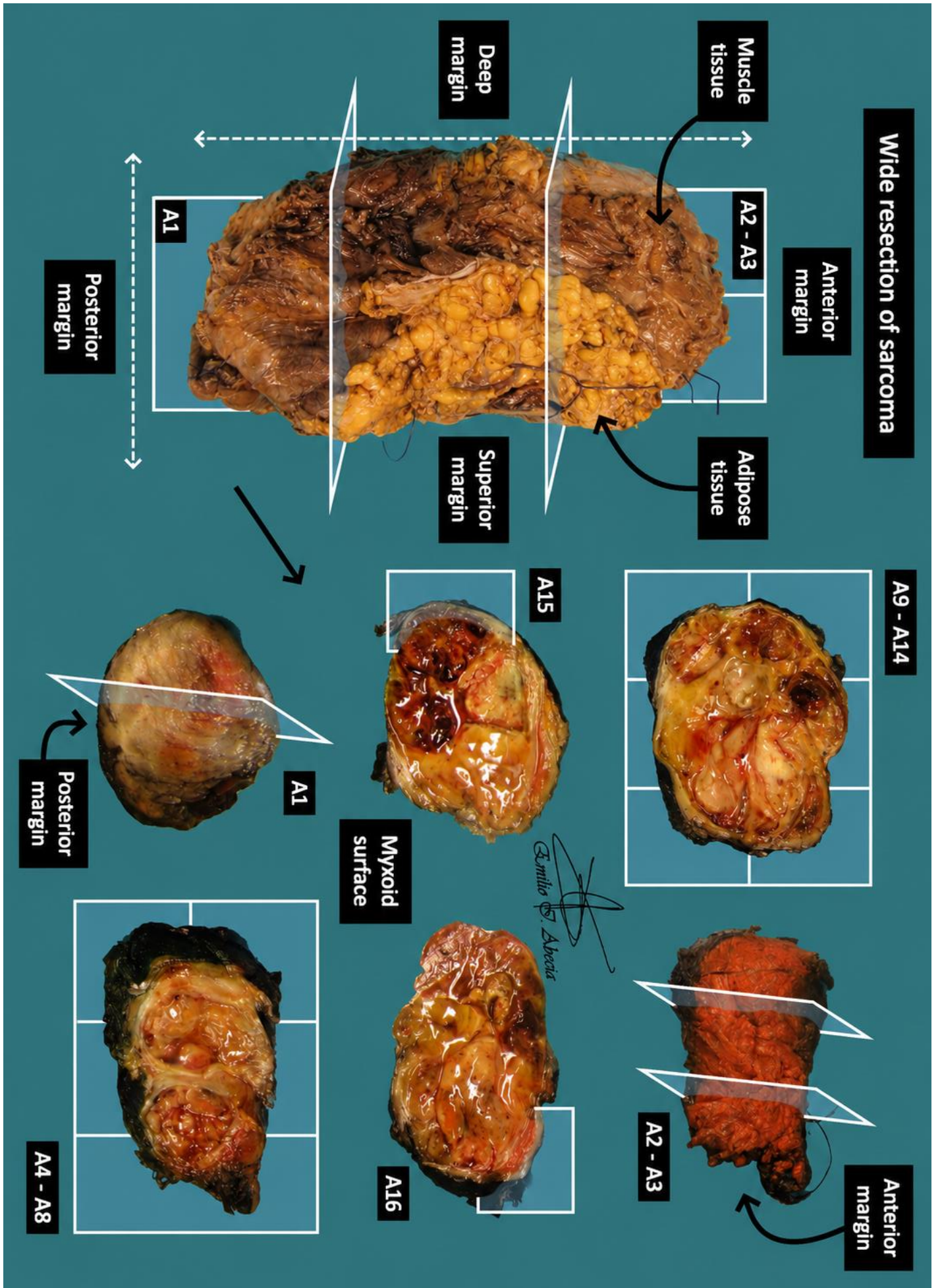


## TO CONSIDER

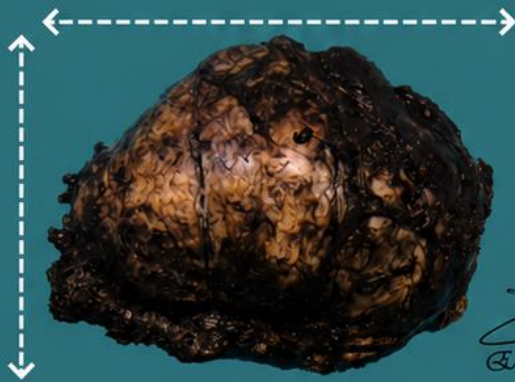
- More or less extensive and complex resections of mesenchymal lesions (connective, fibrous, muscular, adipose tissue, etc.), which may be locally invasive or malignant.
- Review the clinical history to assess imaging findings, infiltration, multifocality, necrotic foci, or whether the specimen has received neoadjuvant therapy.
- Orient, weigh, and measure the specimen. These specimens are often spatially referenced and accompanied by anatomical structures (nerves, skeletal muscle, bone fragments, skin, etc.).
- Describe the external surface and ink the surgical margins.
- Ink the margins and serially section the specimen; indicate lesion size and distance to margins.
- Identify and measure relevant features (foci of necrosis, fibrosis, infiltration of adjacent structures). For staging purposes, it is important to report the percentage of necrosis relative to the total lesion volume.
- Submit representative sections:
  - Include all surgical margins, identifying them topographically during embedding.
  - Be generous with tissue sampling; as a general rule, submit at least one section per centimetre of the greatest dimension of the specimen.
  - Include sections of the lesion in relation to anatomical structures such as muscle fragments, skin, etc.
- It is advisable to document the sampling with a photograph / diagram.
- Consider whether fresh or frozen tissue should be reserved for additional molecular or genetic studies, according to institutional protocol.







**Excision of Chondrosarcoma**

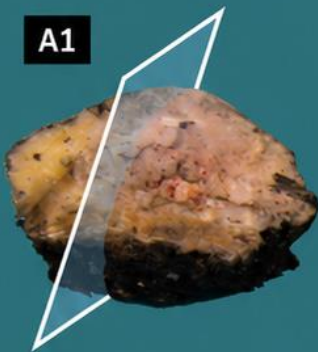


*Emilio I. Abecia*

**Ensure surgical margin (specimen unorientated)**



**A1**

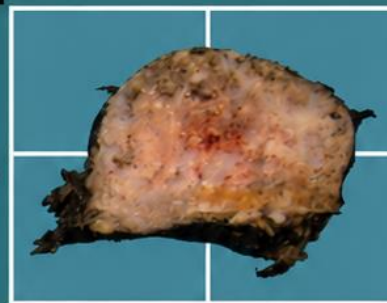


**Lateral margin**

**Cartilaginous areas**

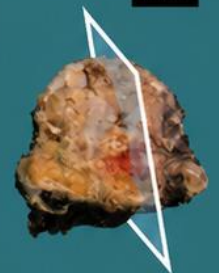


**A7 - A8**

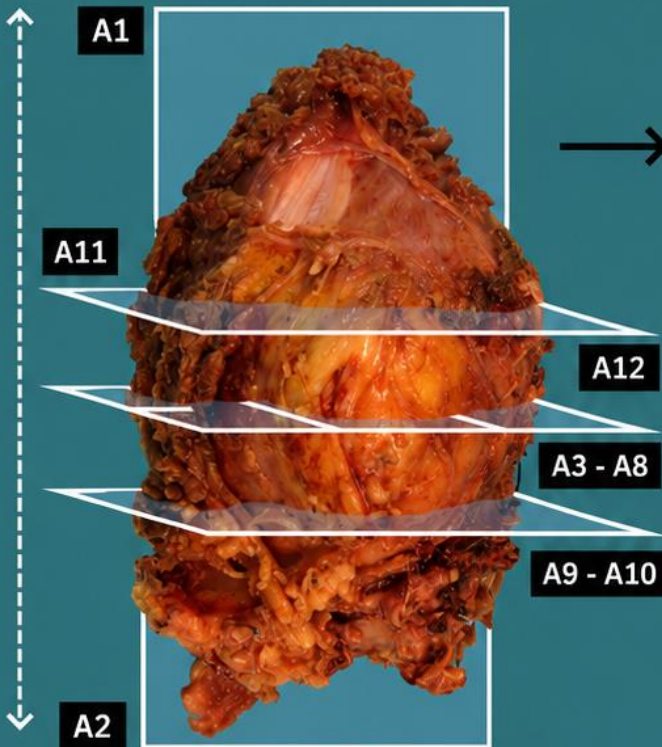


**A3 - A6**


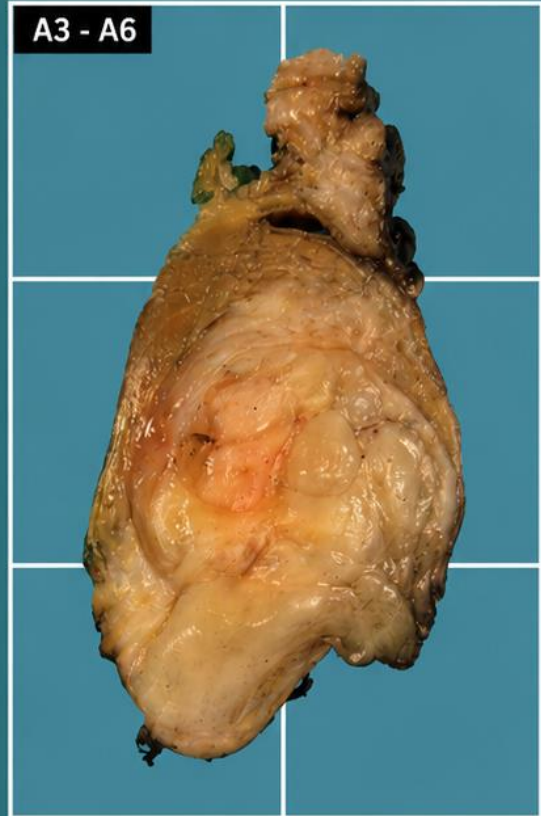
**A2**



**Lateral margin**



**Excision of Rhabdomyosarcoma**



## BIBLIOGRAPHY

- *Soft Tissue Resection (Bone and Soft Tissue)*. Gross Manual. UCLA Health. Recuperado el 13 de Mayo de 2024: <https://www.uclahealth.org/sites/default/files/documents/cc/soft-tissue-resection-122022.pdf?f=98912376>
- Cipriani N., Rose S. (2019). *Soft Tissue Tumor (Bone & Soft Tissue)*. Gross Pathology Manual (University Of Chicago). Recuperado el 13 de Mayo de 2024: <https://voices.uchicago.edu/grosspathology/bone-soft-tissue/soft-tissue-tumor/>
- Laurini J.A (June 2021). *Soft Tissue, Resection (v4.1.0.0)*. College of American Pathologists (CAP). Recuperado el 13 de Mayo de 2024: [https://documents.cap.org/protocols/Soft.Tissue\\_4.1.0.0.REL\\_CAPCP.pdf?\\_gl=1\\*1amiq5\\*\\_ga\\*MTc4Nzk0MDczNC4xNzE0NDczNzAy\\*\\_ga\\_97ZFJSQQ0X\\*MTcxNDQ3MzcxwMi4xLjEuMTcxNDQ3NDExMy4wLjAuMA](https://documents.cap.org/protocols/Soft.Tissue_4.1.0.0.REL_CAPCP.pdf?_gl=1*1amiq5*_ga*MTc4Nzk0MDczNC4xNzE0NDczNzAy*_ga_97ZFJSQQ0X*MTcxNDQ3MzcxwMi4xLjEuMTcxNDQ3NDExMy4wLjAuMA)
- WHO Classification of Tumours Editorial Board (2020). *Soft Tissue and Bone Tumours* (5th ed.; vol. 3). International Agency for Research on Cancer. <https://publications.iarc.fr/Book-And-Report-Series/Who-Classification-Of-Tumours/Soft-Tissue-And-Bone-Tumours-2020>
- Lemos, M. B., & Okoye, E. (2019). *Atlas of Surgical Pathology Grossing*. Springer Nature Switzerland AG. <https://link.springer.com/book/10.1007/978-3-030-20839-4>
- Susan C. Lester, French, C. A., & Curtis, S. G. (2010). *Manual of Surgical Pathology: Expert Consult* (ed. 3). Elsevier. <https://www.sciencedirect.com/book/9780323065160/manual-of-surgical-pathology>
- Shameem Shariff. (2019). *Fundamentals of Surgical Pathology* (ed.2). Jaypee Brothers Medical Publishers. <https://www.jaypeedigital.com/book/9789388958967>
- Westra, W. H., Ralph H. Hruban, Timothy H. Phelps, & Christina Iacson. (2003). *Surgical Pathology Dissection: An Illustrated Guide* (ed.2). Springer. <https://link.springer.com/book/10.1007/b97473>

## DISCLAIMER

The image and text are provided for illustrative purposes only. The tissue sections submitted and the description provided will depend on the individual specimen characteristics, the clinical diagnostic suspicion, the experience of the dissector, and the institutional guidelines of the laboratory.

This document has been translated from the original Spanish version using AI-based tools. The text may contain typographical errors or inaccurate translations.

