

# LIPOMA

1. A specimen weighing X g and measuring XXX cm is received // several fragments measuring XXX cm in aggregate are received // accompanied by a skin ellipse / soft tissue measuring XXX cm.
2. Externally, the specimen shows a yellowish coloration, with a smooth surface and soft consistency, without other features // the skin ellipse / soft tissue shows X characteristics.
3. The surgical margin is inked with India ink.
4. On serial sectioning, the cut surface is smooth and homogeneous, without well-defined lesions // an atypical focus measuring XX cm with X characteristics is identified.
5. Submission of representative sections:

1st Example (Lipoma):

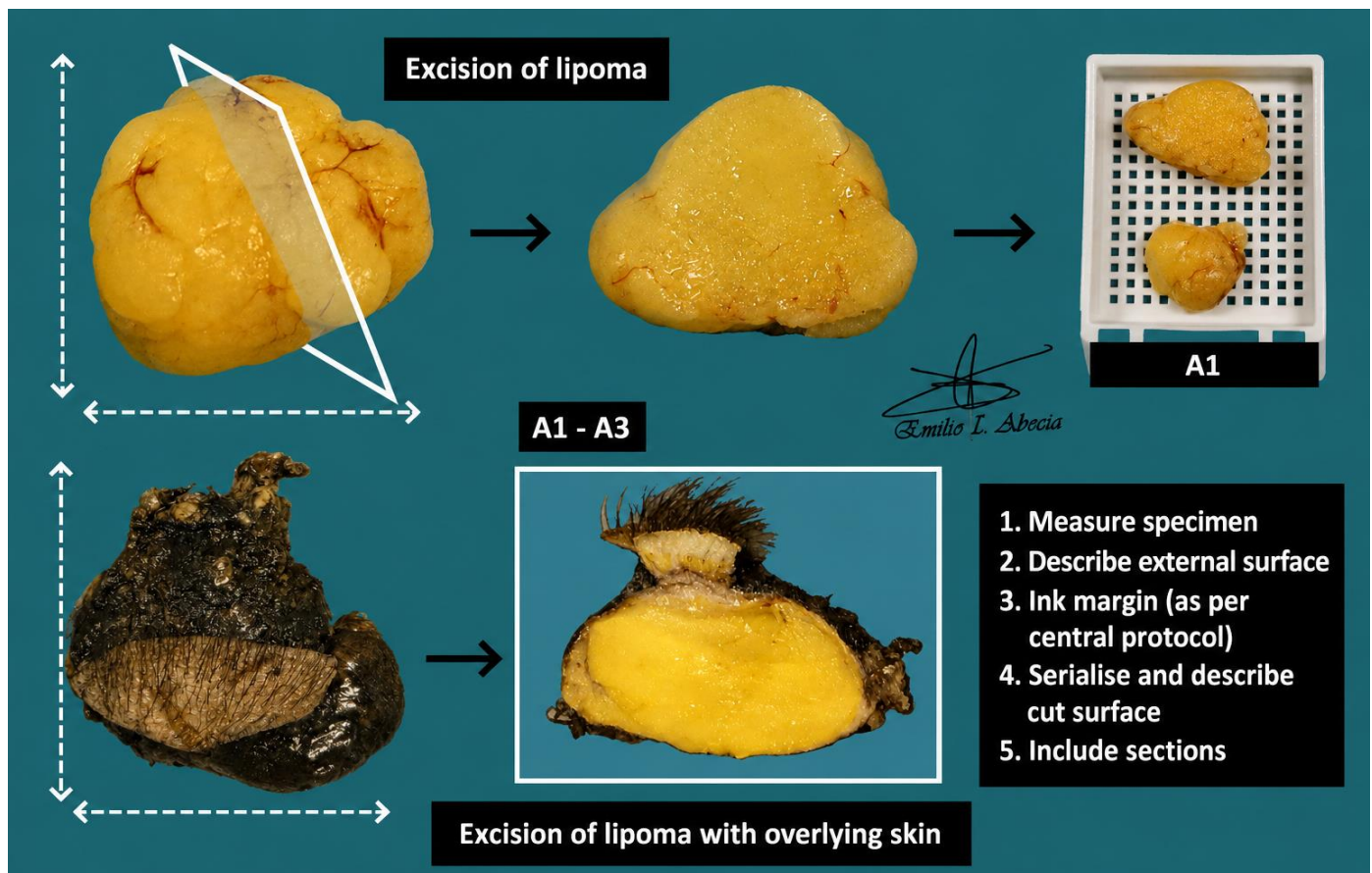
- A1: entirely submitted after bisection.

2nd Example (Lipoma + skin ellipse):

- A1–A3: representative sections submitted.

## TO CONSIDER

- Resection of benign adipocytic lesions, relatively common in routine hospital practice. These lesions usually have limited prognostic significance unless malignant transformation is present.
- Weigh, measure, and describe the external surface.
- Ink the surgical margin. If the specimen is received fragmented, inking is not required.
- Submit representative sections:
  - At least one section of the lesion per centimetre of greatest dimension.
  - If the lesions are small, submit entirely.
  - If atypical / suspicious foci for malignancy are identified, submit additional sections.
  - If present, include sections of adjacent structures (muscle, skin, etc.).



Emilio I. Abecia Martínez

## BIBLIOGRAPHY

- Nicole Cipriani, & Sarah Rose (2019). *Lipoma (Bone & Soft Tissue)*. Gross Pathology Manual (University Of Chicago). Recuperado el 13 de Mayo de 2024: <https://voices.uchicago.edu/grosspathology/bone-soft-tissue/lipoma/>
- *Lipoma (Bone and Soft Tissue)*. Gross Manual. UCLA Health. Recuperado el 13 de Mayo de 2024: <https://www.uclahealth.org/sites/default/files/documents/e7/lipoma-122022.pdf?f=b119e3cd>
- WHO Classification of Tumours Editorial Board (2020). *Soft Tissue and Bone Tumours* (5th ed.; vol. 3). International Agency for Research on Cancer. <https://publications.iarc.fr/Book-And-Report-Series/Who-Classification-Of-Tumours/Soft-Tissue-And-Bone-Tumours-2020>
- Lemos, M. B., & Okoye, E. (2019). *Atlas of Surgical Pathology Grossing*. Springer Nature Switzerland AG. <https://link.springer.com/book/10.1007/978-3-030-20839-4>
- Susan C. Lester, French, C. A., & Curtis, S. G. (2010). *Manual of Surgical Pathology: Expert Consult* (ed. 3). Elsevier. <https://www.sciencedirect.com/book/9780323065160/manual-of-surgical-pathology>
- Shameem Shariff. (2019). *Fundamentals of Surgical Pathology* (ed.2). Jaypee Brothers Medical Publishers. <https://www.jaypeedigital.com/book/9789388958967>
- Westra, W. H., Ralph H. Hruban, Timothy H. Phelps, & Christina Iacson. (2003). *Surgical Pathology Dissection: An Illustrated Guide* (ed.2). Springer. <https://link.springer.com/book/10.1007/b97473>

## DISCLAIMER

The image and text are provided for illustrative purposes only. The tissue sections submitted and the description provided will depend on the individual specimen characteristics, the clinical diagnostic suspicion, the experience of the dissector, and the institutional guidelines of the laboratory.

This document has been translated from the original Spanish version using AI-based tools. The text may contain typographical errors or inaccurate translations.

