

CUTANEOUS CYSTECTOMY

1. A specimen labelled as X, consisting of a cystectomy measuring XXX cm, is received // accompanied by an ellipse of skin measuring XX cm // a cutaneous resection measuring XXX cm is received.
2. Externally, the specimen shows no remarkable features // shows a whitish / brownish cyst capsule with a smooth / irregular and intact / perforated surface.
3. The surgical margin is inked.
4. On sectioning, the cyst shows a smooth internal surface, with a unilocular / multilocular configuration and keratinous / friable / dense contents with brownish / yellowish / etc. coloration // a thickened wall with solid / papillary lesions measuring XX cm is identified.
5. Representative sections are submitted as follows:

1st Example (Simple cystectomy):

- A1 and A2: central sections of the specimen.

2nd Example (Cystectomy with skin ellipse):

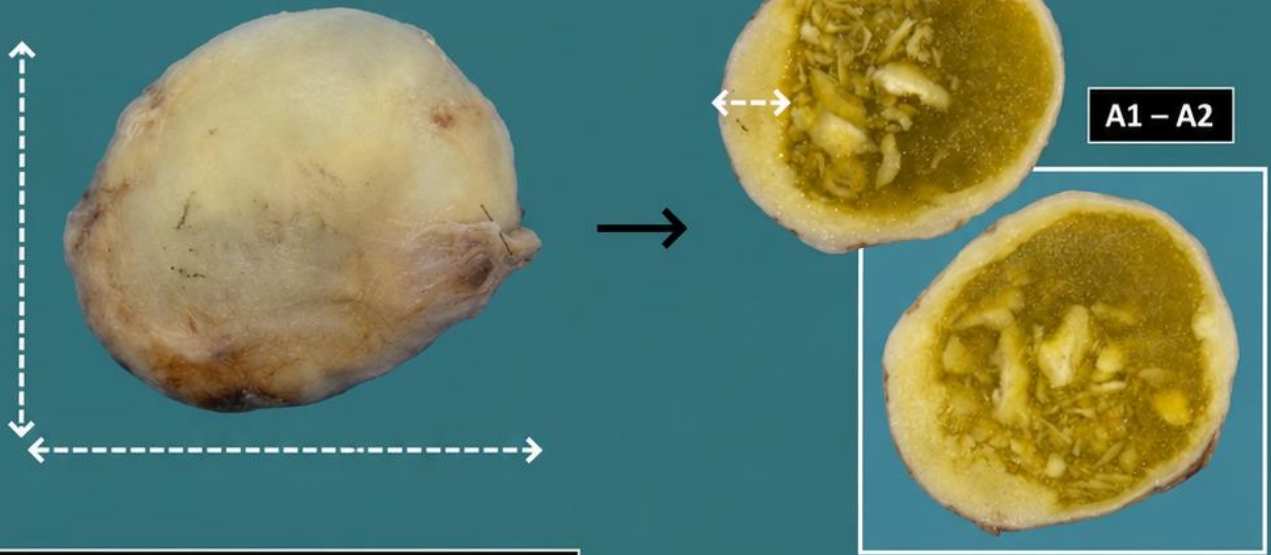
- A1: central section.
- A2: one surgical margin.
- A3: contralateral surgical margin.

TO CONSIDER

- Benign lesions usually excised for cosmetic reasons or due to concern regarding malignant transformation (which is very rare). Therefore, these specimens generally have limited diagnostic significance.
- Measure and describe the specimen.
- Ink the surgical margin according to institutional protocol (optional in non-neoplastic lesions).
- Serially section and describe the cut surface.
- Submit representative sections:
 - Include sections showing the cyst wall.
 - If suspicious solid / papillary lesions are identified, submit them entirely or near-entirely.
 - Attempt to represent the cystic contents.
 - If received with a skin ellipse, include sections in relation to the surgical margin.



Cystectomy specimen




1. Measure the lesion
2. Describe the external surface
3. State the surgical margin
4. Serially section and describe the cut surface
5. Include representative sections

Skin excision with cyst



Skin ellipse

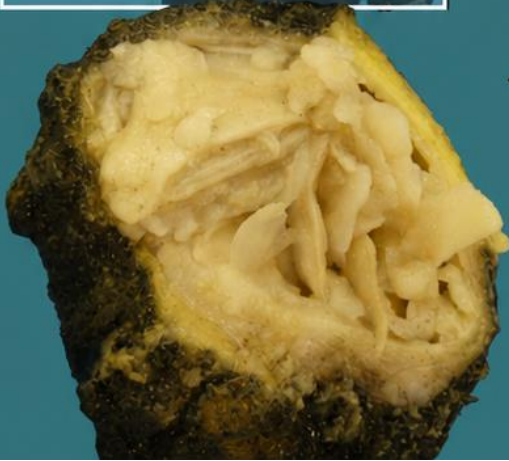


State the surgical margin


A1 - A2

A4

A3



Keratinous content



BIBLIOGRAPHY

- *Skin Excision (Dermatopathology)*. Gross Manual. UCLA Health. Recuperado el 13 de Mayo de 2024: <https://www.uclahealth.org/sites/default/files/documents/0c/skin-excision-12723.pdf?f=9ebd7449>
- Cipriani N., Rose S. (2019). *Skin Excision (Skin)*. Gross Pathology Manual (University Of Chicago). Recuperado el 13 de Mayo de 2024: <https://voices.uchicago.edu/grosspathology/skin/skin-excision/>
- *Orientation Guidelines (Dermatopathology)*. Gross Manual. UCLA Health. Recuperado el 13 de Mayo de 2024: <https://www.uclahealth.org/sites/default/files/documents/Orientation.%20MUST%20READ.pdf>
- Lemos, M. B., & Okoye, E. (2019). *Atlas of Surgical Pathology Grossing*. Springer Nature Switzerland AG. <https://link.springer.com/book/10.1007/978-3-030-20839-4>
- Susan C. Lester, French, C. A., & Curtis, S. G. (2010). *Manual of Surgical Pathology: Expert Consult* (ed. 3). Elsevier. <https://www.sciencedirect.com/book/9780323065160/manual-of-surgical-pathology>
- Shameem Shariff. (2019). *Fundamentals of Surgical Pathology* (ed.2). Jaypee Brothers Medical Publishers. <https://www.jaypeedigital.com/book/9789388958967>
- Westra, W. H., Ralph H. Hruban, Timothy H. Phelps, & Christina Iacson. (2003). *Surgical Pathology Dissection: An Illustrated Guide* (ed.2). Springer. <https://link.springer.com/book/10.1007/b97473>

DISCLAIMER

The image and text are provided for illustrative purposes only. The tissue sections submitted and the description provided will depend on the individual specimen characteristics, the clinical diagnostic suspicion, the experience of the dissector, and the institutional guidelines of the laboratory.

This document has been translated from the original Spanish version using AI-based tools. The text may contain typographical errors or inaccurate translations.

