

LARGE NON-NEOPLASTIC SKIN SPECIMEN

1. Labelled as X, a skin ellipse measuring XXX cm is received, oriented with a suture at the X o'clock position // without orientation provided.
2. Externally, no remarkable features are identified // a superficial lesion measuring XX cm is identified, located X cm from the closest margin // additionally, a secondary lesion measuring XX cm is identified, located X cm from the closest margin.
3. The resection margins are inked (optional in non-neoplastic specimens).
4. On sectioning, the cut surface is unremarkable // a fibrotic cut surface is identified, with firm / soft-elastic consistency, without clearly well-defined lesions // with a lesion measuring XXX cm.
5. The lesion shows an encapsulated / non-encapsulated morphology, with a brownish / whitish coloration and X characteristics.
6. Representative sections are submitted as follows:

1st Example (Fistulectomy):

- A1 – A2: entire specimen submitted.

2nd Example (Hidradenitis Suppurativa):

- A1 – A4: representative sections of the lesion.

3rd Example (Meningocele):

- A1 – A2: representative sections of the specimen.

4th Example (Giant Soft Fibroma):


- A1 – A2: representative sections of the specimen in relation to the margin.


5th Example (Cutaneous Haematoma):

- A1 – A4: entirely submitted specimen (A3 and A4 in relation to the deep margin).


TO CONSIDER

- Cutaneous specimens of variable size excised for infectious, inflammatory (hidradenitis, autoimmune disorders), traumatic (haematomas), malformative, or other non-neoplastic conditions. Clinical information should be reviewed to confirm the surgical indication.
- Measure and orient the specimen. As these are non-neoplastic specimens, exhaustive assessment of the resection margins is not required.
- Identify and describe external lesions.
- Consider inking the surgical margins according to institutional protocol (optional in non-neoplastic specimens).
- Serially section along the short axis and describe any abnormalities present / the cut surface.
- Submit representative sections:
 - Include the alterations that justified the surgical procedure, attempting to correlate them with the surgical margins.
 - If incidental / secondary lesions are present, these should also be submitted.
 - If the specimen contains vesicular lesions, attempt to submit them without sectioning in order to preserve their architecture.






Fistula excision specimen

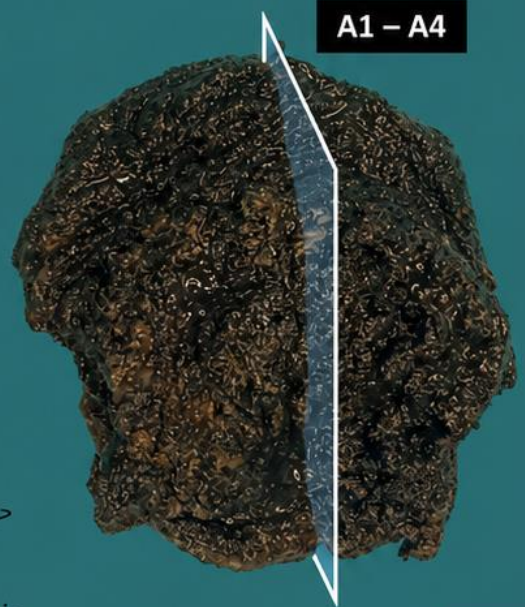

Bisect longitudinally

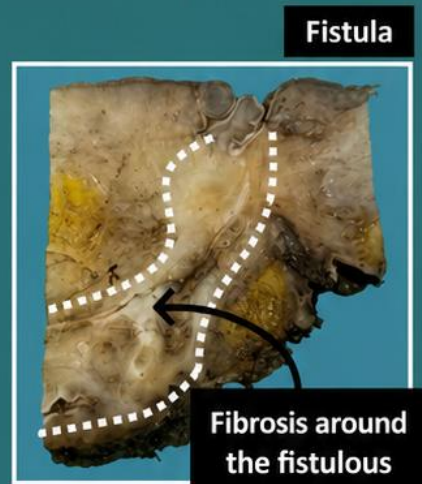
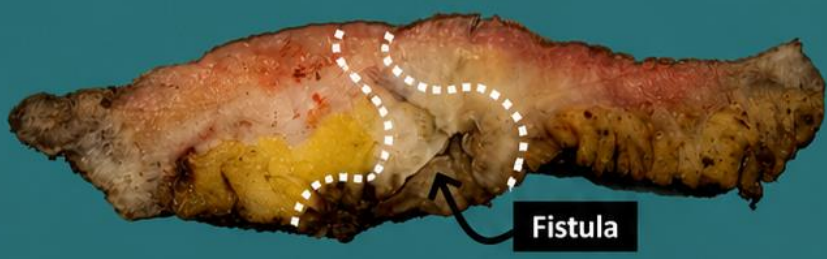
Skin excision for Hidradenitis




Include surgical margin (optional)



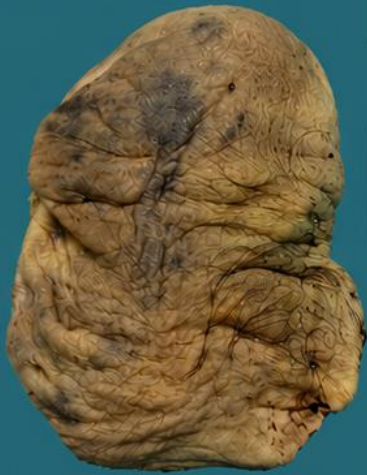Emilio I. Abecia



- 1. Orientate and measure the specimen
- 2. Describe the external surface
- 3. Include surgical margin (optional: non-tumoral)
- 4. Section, localise and measure the lesion
- 5. Describe the cut surface of the lesion
- 6. Take representative sections

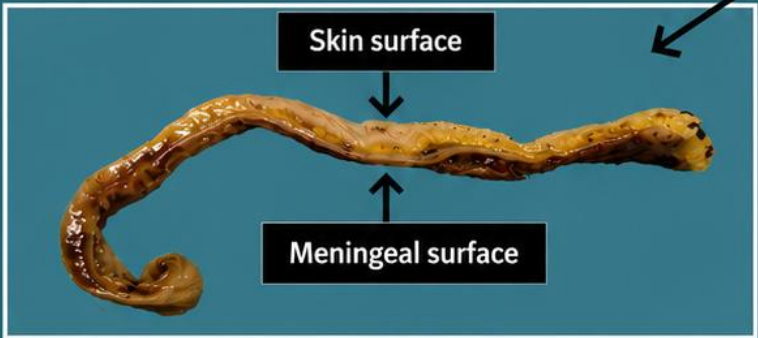
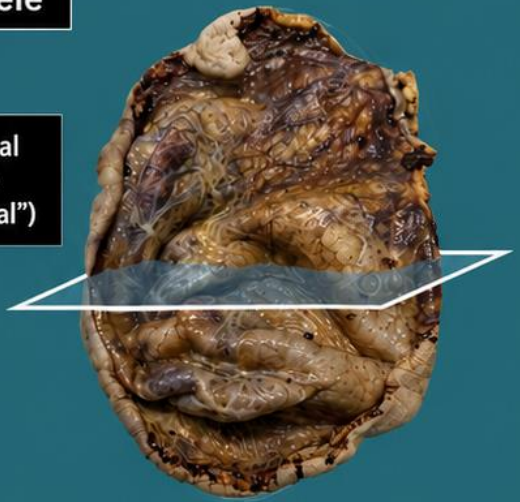


Excision of Meningocele

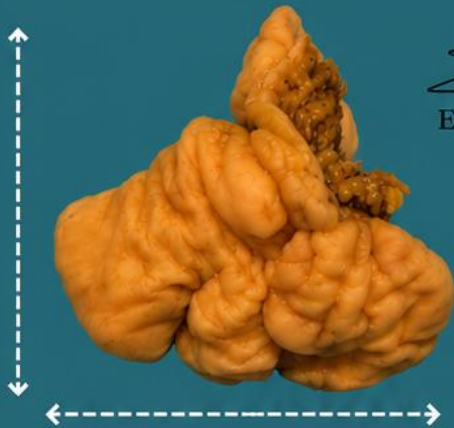


Skin surface
("cutaneous")

Meningeal surface
("meningeal")



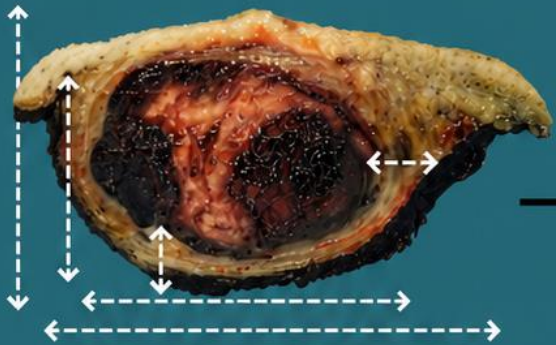
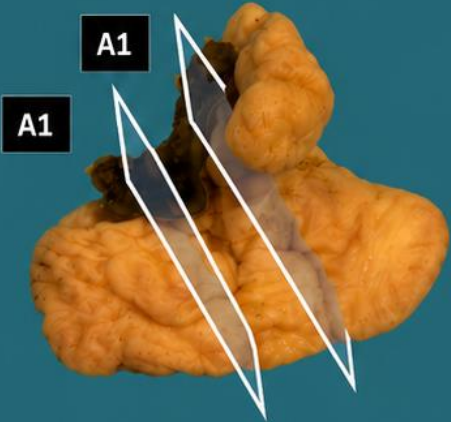
A1 - A2



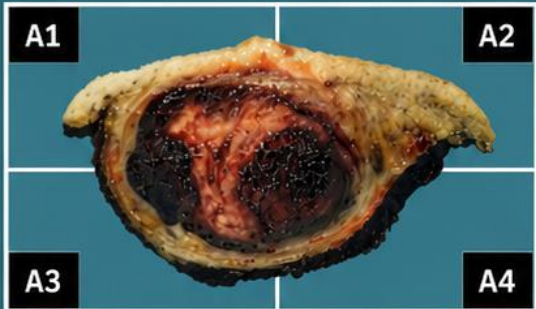
Emilio I. Abecia




Giant soft fibroma



Subcutaneous hematoma



Sampling of heterogeneous areas
(to exclude angiosarcoma)



BIBLIOGRAPHY

- Cipriani N., Rose S. (2019). *Skin Excision (Skin)*. Gross Pathology Manual (University Of Chicago). Recuperado el 13 de Mayo de 2024: <https://voices.uchicago.edu/grosspathology/skin/skin-excision/>
- *Orientation Guidelines (Dermatopathology)*. Gross Manual. UCLA Health. Recuperado el 13 de Mayo de 2024: <https://www.uclahealth.org/sites/default/files/documents/Orientation.%20MUST%20READ.pdf>
- *Skin Excision, Large (Dermatopathology)*. Gross Manual. UCLA Health. Recuperado el 13 de Mayo de 2024: <https://www.uclahealth.org/sites/default/files/documents/f0/skin-excision-large-12723.pdf?f=c79d69f4>
- Lemos, M. B., & Okoye, E. (2019). *Atlas of Surgical Pathology Grossing*. Springer Nature Switzerland AG. <https://link.springer.com/book/10.1007/978-3-030-20839-4>
- Susan C. Lester, French, C. A., & Curtis, S. G. (2010). *Manual of Surgical Pathology: Expert Consult* (ed. 3). Elsevier. <https://www.sciencedirect.com/book/9780323065160/manual-of-surgical-pathology>
- Shameem Shariff. (2019). *Fundamentals of Surgical Pathology* (ed.2). Jaypee Brothers Medical Publishers. <https://www.jaypeedigital.com/book/9789388958967>
- Westra, W. H., Ralph H. Hruban, Timothy H. Phelps, & Christina Iacson. (2003). *Surgical Pathology Dissection: An Illustrated Guide* (ed.2). Springer. <https://link.springer.com/book/10.1007/b97473>

DISCLAIMER

The image and text are provided for illustrative purposes only. The tissue sections submitted and the description provided will depend on the individual specimen characteristics, the clinical diagnostic suspicion, the experience of the dissector, and the institutional guidelines of the laboratory.

This document has been translated from the original Spanish version using AI-based tools. The text may contain typographical errors or inaccurate translations.

