

RADICAL MASTECTOMY


1. A left / right radical mastectomy specimen weighing X g and measuring XXX cm is received / with a skin ellipse measuring XX cm and a nipple-areola complex measuring XX cm / with an axillary lymph node dissection specimen measuring XXX cm / without orientation provided / oriented with X indicating the X o'clock position.
2. Externally, no remarkable features are identified // the nipple-areola complex appears retracted // a superficial lesion measuring XX cm is identified, showing X characteristics and located X cm from the surgical margin.
3. The anterior surface is inked X and the posterior surface is inked X.
4. On serial sectioning, a lesion measuring XXX cm is identified in the mid / posterior / anterior plane of the upper outer quadrant (UOQ) / upper inner quadrant (UIQ) / lower inner quadrant (LIQ) / lower outer quadrant (LOQ) / retroareolar region, located X cm from the X surgical margin.
5. The lesion is heterogeneous / homogeneous, with well / poorly defined borders, whitish in colour, and of firm / indurated consistency / etc.
6. The remaining parenchyma shows no significant abnormalities / alternating adipose areas with foci of fibrous appearance / an additional lesion measuring X cm is identified, located in X.
7. Within the axillary dissection specimen, X nodular structures are identified, ranging from X to X cm in greatest dimension.
8. Representative sections are submitted as follows:

1st Example (Post-neoadjuvant mastectomy for ductal carcinoma)

- A1: section of nipple-areola complex.
- A2 - A3: sections from the retroareolar area from 12 to 6 o'clock.
- A4 - A6: section of lesion in relation (A6 towards 6 o'clock).
- A7 - A9: section of lesion in relation (A9 towards 6 o'clock).
- A10: representative section from upper outer quadrant.
- A11: representative section from lower outer quadrant.
- A12: representative section from upper inner quadrant.
- A13: representative section from lower inner quadrant.


2nd Example (Mastectomy for extensive carcinoma)

- A1: section of nipple-areola complex.
- A2 - A6: one complete central section.
- A7 - A9: additional sections to assess muscle infiltration.
- A10: section from "3 o'clock" margin.
- A11: section from "9 o'clock" margin.
- A12 - A13: additional sections in relation to posterior margin.
- A14: section in relation to inferior "6 o'clock" margin.
- A15: representative section from upper inner quadrant.
- A16: representative section from lower inner quadrant.
- A17: representative section from upper outer quadrant.
- A18: representative section from lower outer quadrant.




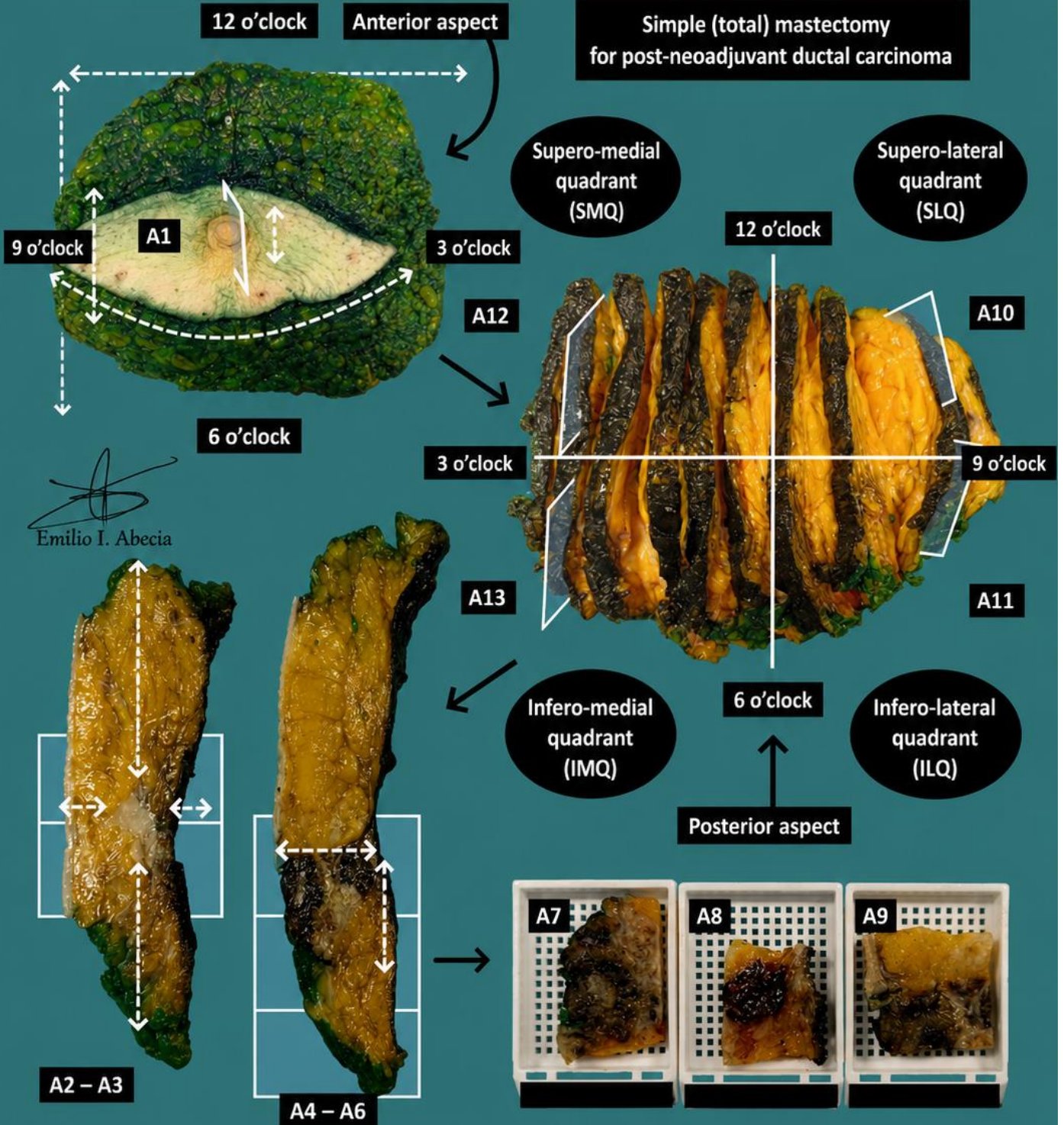
TO CONSIDER


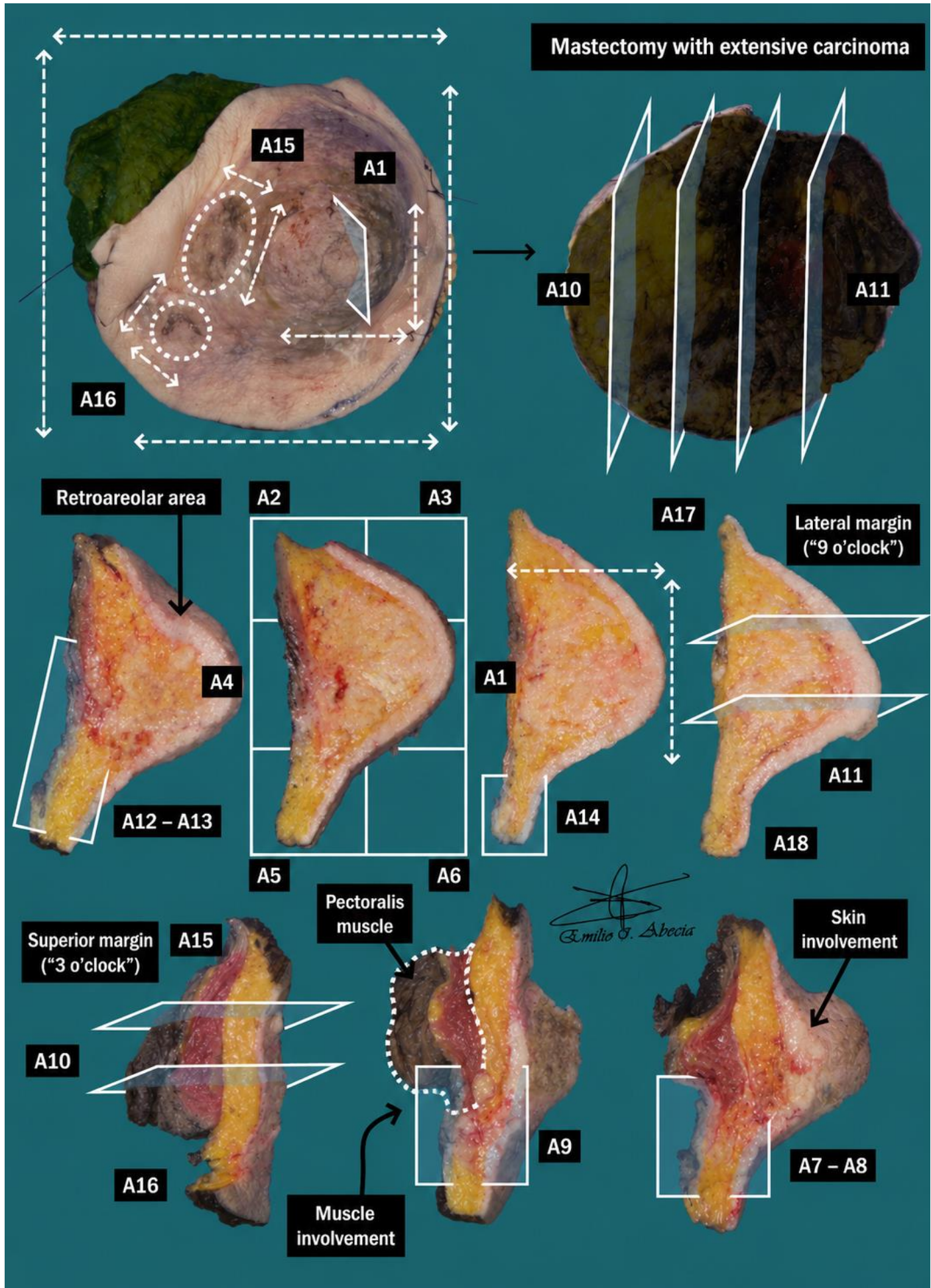
- Radical breast surgery specimen including breast tissue and skin, which may be accompanied by axillary lymph node dissection and pectoral muscle.
- Due to the nature of the tissue, prompt fixation of the specimen in formaldehyde following surgery is recommended for optimal processing and immunohistochemical staining quality.
- Prior to dissection, it is recommended to review the clinical history to confirm lesion location, multifocality, and whether the specimen has received neoadjuvant therapy (the lesion may show regressive changes, fibrosis, muscular hyperplasia, erosions, etc.).
- Orient and measure the specimen, specifying the type of mastectomy: simple, radical, modified radical, skin-sparing, or nipple-areola complex-sparing mastectomy.
- Describe the external surface and nipple-areola complex, indicating whether superficial lesions are present.
- Ink both surfaces of the specimen (posterior and anterior) according to institutional protocol. Due to their importance, the use of multiple ink colours is recommended.
- Serially section the specimen along the 12–6 o'clock axis; localise, measure, and describe the lesion, recording the distance to margins and nipple-areola complex.
- Document the presence of markers or secondary lesions (e.g. fibroadenoma).
- Submit representative sections:
 - Include representative sections of the nipple-areola complex and the four spatial quadrants.
 - Represent all spatial margins (12, 6, 3, 9 o'clock and posterior).
 - Submit at least one section per centimetre of the lesion's greatest dimension. If more than one lesion is identified, both should be described and measured, and the distance between them documented.
 - Multifocal mastectomies or extensive in situ carcinomas may require very meticulous sampling. Attempts should be made to optimise block selection.
 - If the specimen has received neoadjuvant therapy and no residual tumour is identified, entirely submit the indurated / ulcerated area (tumour bed with regressive changes).
 - When submitting the lymph node dissection specimen (if present), assess whether orientation by levels (I and II) has been provided. An attempt should be made to identify between 10–20 lymph nodes.
 - It is useful to document the blocks with a diagram or photograph.



1. Weigh, orient and measure the specimen, including the areola–nipple complex (ANC)
2. Describe external surface abnormalities
3. Include surgical margins
4. Serially section the specimen and measure the lesion, including distance to margins
5. Describe the cut surface of the lesion
6. Describe remaining parenchyma / possible secondary lesions
7. Isolate lymph nodes (if specimen includes lymphadenectomy)
8. Include representative sections

**Simple (total) mastectomy
for post-neoadjuvant ductal carcinoma**





BIBLIOGRAPHY

- Cipriani N., Rose S. (2019). *Mastectomy (Breast)*. Gross Pathology Manual (University Of Chicago). Recuperado el 13 de Mayo de 2024: <https://voices.uchicago.edu/grosspathology/breast/mastectomy/>
- *Mastectomy (Breast)*. Gross Manual. UCLA Health. Recuperado el 13 de Mayo de 2024: <https://www.uclahealth.org/sites/default/files/documents/57/mastectomy-122222.pdf?f=7ed770be>
- Schnitt S.J., Rosenberger L.H., Tan P.H., Fitzgibbons P.L., Connolly J.L. (2022). *Breast Phyllodes Tumor* (v1.1.0.1). College of American Pathologists (CAP). Recuperado el 13 de Mayo de 2024: https://documents.cap.org/protocols/Breast.Phyllodes_1.1.0.1.REL_CAPCP.pdf?_gl=1*15xz3sj*_ga*MTc4Nzk0MDczNC4xNzE0NDczNzAy*_ga_97ZFJSQQ0X*MTcxNDQ3MzcwMi4xLjEuMTcxNDQ3NDExMy4wLjAuMA
- Fitzgibbons P.L., Connolly J.L. (2021). *Breast DCIS, Resection* (v4.4.0.0). College of American Pathologists (CAP). Recuperado el 13 de Mayo de 2024: https://documents.cap.org/protocols/Breast.DCIS_4.4.0.0.REL_CAPCP.pdf?_gl=1*zg9g6e*_ga*MTc4Nzk0MDczNC4xNzE0NDczNzAy*_ga_97ZFJSQQ0X*MTcxNDQ3MzcwMi4xLjEuMTcxNDQ3NDExMy4wLjAuMA
- Krishnamurti U.G., Fitzgibbons P.L., Connolly J.L. (2023). *Breast Invasive, Resection* (v4.9.0.1). College of American Pathologists (CAP). Recuperado el 13 de Mayo de 2024: https://documents.cap.org/protocols/Breast.Invasive_4.9.0.1.REL_CAPCP.pdf?_gl=1*15xz3sj*_ga*MTc4Nzk0MDczNC4xNzE0NDczNzAy*_ga_97ZFJSQQ0X*MTcxNDQ3MzcwMi4xLjEuMTcxNDQ3NDExMy4wLjAuMA
- WHO Classification of Tumours Editorial Board (2019). *Breast tumours* (5th ed., vol. 2). International Agency for Research on Cancer. <https://publications.iarc.fr/Book-And-Report-Series/Who-Classification-Of-Tumours/Breast-Tumours-2019>
- Lemos, M. B., & Okoye, E. (2019). *Atlas of Surgical Pathology Grossing*. Springer Nature Switzerland AG. <https://link.springer.com/book/10.1007/978-3-030-20839-4>
- Susan C. Lester, French, C. A., & Curtis, S. G. (2010). *Manual of Surgical Pathology: Expert Consult* (ed. 3). Elsevier. <https://www.sciencedirect.com/book/9780323065160/manual-of-surgical-pathology>
- Shameem Shariff. (2019). *Fundamentals of Surgical Pathology* (ed.2). Jaypee Brothers Medical Publishers. <https://www.jaypeedigital.com/book/9789388958967>
- Westra, W. H., Ralph H. Hruban, Timothy H. Phelps, & Christina Iacono. (2003). *Surgical Pathology Dissection: An Illustrated Guide* (ed.2). Springer. <https://link.springer.com/book/10.1007/b97473>

DISCLAIMER

The image and text are provided for illustrative purposes only. The tissue sections submitted and the description provided will depend on the individual specimen characteristics, the clinical diagnostic suspicion, the experience of the dissector, and the institutional guidelines of the laboratory.

This document has been translated from the original Spanish version using AI-based tools. The text may contain typographical errors or inaccurate translations.

