

# THE NINTH QUADRANT

*Powered by Macroficial Intelligence*

May-Aug 2025



ONLINE  
STATS



[www.doped.co.in](http://www.doped.co.in)

120 DAYS

199 UNIQUE VISITORS

332 SITE SESSIONS



39% ▲



8% ▲



13% ▲  
Mobile sessions

(via Hostinger Analytics)



Follow us: @doped.cdsrc



Subscribe: @doped\_cdsrc

PATIENT  
STATS

1090

PREVENTIVE

1119

RESTORATIVE

83

INTERCEPTIVE

1016

PULP THERAPIES

09

SPECIAL CASES

**“Research is to see what everybody else has seen, and to think what nobody else has thought.”**

*Albert Sczent-Gyorgyi*

The Ninth Quadrant is one of the many attempts of the **Department of Pediatric & Preventive Dentistry at the College of Dental Sciences & Research Centre (Ahmedabad, India)** to impart dental education and engage young scholars in scientific reading & writing. This newsletter is a triannual publication. We welcome potential contributors to send us an email at [bopalpedo@gmail.com](mailto:bopalpedo@gmail.com).



## DENTAL NEWS

1. Toothache as a sign of heart attack: <http://bit.ly/4lFdMoX>
2. Neuromelioidosis through dental cross-infection: <https://bit.ly/46uDUyo>
3. The Fluoride Debate: <https://bit.ly/4eI10Uu>

## DENTAL QUIZ



1. Name any four methods of mixed dentition model analysis.
2. When do we use the tongue blade therapy?
3. What is the difference between straight line access and glide path?

### INVENTORS



**Michael Buonocore**  
Acid Etching



**Rafael Bowen**  
Bis-GMA



**Sumita Mitra**  
First nanofilled restoration



**Alan Wilson**  
Glass Ionomer Cement

## LISTEN UP!

### TRY THIS AI PROMPT

“Design a poster illustrating the eruption timeline of primary teeth.”

### BEWARE OF

European Journal of  
Molecular and Clinical  
Medicine

### BE AWARE OF

Dental and Medical Problems

## CLINICAL CONUNDRUM

### WHAT IF THE SPACE DISCREPANCY IS 0 MM?

This is a case of the space discrepancy being in an equilibrium. The space available for the eruption of the permanent tooth is the same as the space it requires. The extent of the tooth's premature exfoliation must be checked, and if there is a potential for space loss, a space maintainer must be placed. If not, the patient must undergo routine follow-ups, and the position of the successor must be monitored.

## READING

Primary Tooth Development  
in Infancy – A Text and Atlas  
by P. Sema Aka

## LISTENING

Brews and Tiny Teeth on  
Spotify

## DOCUMENTARY

The Brown Heart

## SOCIAL MEDIA HANDLE

Instagram: @doped.cdsrc

## WEBSITE

<https://hemingwayapp.com/>  
for online grammar check

## SOFTWARE

Zotero Reference  
Management

## APPLICATION

Swayam

## BIOFEEDBACK RELAXATION


**WHAT:** A technique that shows the patient their vital signs and allows them to voluntarily control them.

**WHEN:** Children displaying high anxiety.

**HOW:** An electric or electromechanical device is placed which shows the pediatric patient their physiologic signs.

They are then given an aim to control the readings through conscious efforts which leads to relaxation via distraction.

BEHAVE!





**DOWNLOAD THIS**  
<http://bit.ly/44NIKqt>

**CHECK THIS OUT**  
<https://www.doped.co.in/clinical-tutorials>

**SCAN TO BE A PART OF IT!**



The Parental Hetero-Assessment Scale can be used to evaluate the relation between the anxiety of the parent and its influence on the child's behavior in the dental clinic.

*"It is important that the approach of the dentists is good which we found here."*  
 - Parents of an 8-year-old whose kid got three teeth extracted.

**TIC-TAC-TOE**

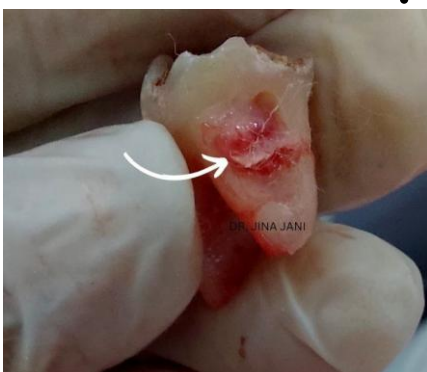PARENT'S BEHAVIOR	
0	Relaxed, Smiling, Calm voice, Good rapport with the dentist, does not move from designated place
1	Uneasy, preoccupied, tense expressions, fixed gaze, distressed voice
2	Reluctant, worried, agitated, restless, grimaces
3	Very disturbed, frightened, approaches the dental seat, aggressive, moans, constantly gives suggestions to the dentist and interrupts treatment
4	Out of control, criticism, touches the child, leaves the office, opposes treatment, cries/in tears, overprotection of child, treatment remains incomplete

ACCESSORY CUSPS	
CUSP OF CARABELLI	Lingual to mesiolingual cusp of upper molars
METACONULE	On the distal border of upper molars
PARACONULE	At the mesial marginal ridge
PARAMOLAR CUSP	On the buccal surface of upper & lower permanent molars
ENTOCONULID	Between the distal & lingual border of lower molars
METACONULID	On the lingual groove of lower molars
PROTOSYLID	On the mesiobuccal surface of mesiobuccal cusp of first and third lower permanent molars
DENS EVAGINATUS	Central cusp on occlusal surface of lower molars arising from buccal or lingual cusp
TALON CUSP	Lingual surface of anterior teeth

**COMPILATION**

**MYTH:** Extracting the upper milk teeth affects the eye.  
**TRUTH:** There is no scientific evidence to support this claim. Loss of vision as a complication of upper teeth extraction has never been reported.

LATERAL ROOT RESORPTION



**DENTAL PHOTOGRAPHY**

**PATIENT FAQ**

**Q: Can kids use powered toothbrush?**  
**A:** Powered toothbrushes are absolutely safe for children and can be used once they cross the age of 3 years. They are absolutely safe and at times even more effective than manual toothbrushes.



**OUTREACH PROGRAMS**

## HOW-TO

### MIX ENDOFLAS



Endoflas comes as a powder-liquid component. It is dispensed on a clean dry glass tile and mixing is done till a consistency is achieved where a cone shape can be appreciated when the spatula is separated from the glass tile. The final consistency must be decided by the practitioner. The material is then inserted in the canals by suitable pressure using cotton, cones, or lentulo-spirals.

### STERI-PPROTOCOL



Agate spatulas are made from natural agate stone. A good quality agate spatula will be non-stick and durable. After using it, all debris on the spatula must be removed using a mild detergent and preferably warm water. The agate spatula is autoclavable. It can also be disinfected using glutaraldehyde or low concentration hydrogen peroxide.

### TRIVIA

Hollywood-fame Sofia Vergara was a dental student who left college two semesters before completing her degree.

### DIET TIP

Food pouching or packing is a parafunctional habit by children that leads to dental caries and nutritional deficiencies.

### PRENATAL PRUDENT

Prenatal Vitamin D supplementation from the second trimester can decrease the risk of early childhood caries.

### PEDIATRIC VALUE

The normal pediatric respiratory rate at the ages of birth to 1 year, 1-3 years, 3-6 years, & 6-12 years is 30-60, 24-40, 22-34, & 18-30 breaths per minute respectively.

### SO CLOSE

**Obturator:** An appliance given to an infant born with cleft lip and cleft palate for facilitating effective feeding.

**Obturation:** Technique of filling the root canals with suitable medicament after its cleaning and disinfection.

## RESEARCH TIPS

### IS A JOURNAL WITH AN NLM ID NECESSARILY INDEXED IN PUBMED?

If a journal has a National Library of Medicine (NLM) ID, it does not mean that it is indexed in PubMed or MEDLINE. Securing an NLM ID is simply for cataloguing purpose for digital libraries. After evaluating a few basic features, an NLM ID is assigned to the journal. However, this does not mean the journal will be indexed in PubMed or MEDLINE. A NLM ID for a journal can be thought of as merely a listing of the journal in a bookshop. To make it to the best-sellers list of this bookshop (PubMed/MEDLINE indexing), the journal has to pass through stringent checks. A journal's profile on the NLM Catalog will state whether the journal is indexed in PubMed/MEDLINE or not.

## IT'S A DATE!

1<sup>st</sup> August: National Oral Hygiene Day

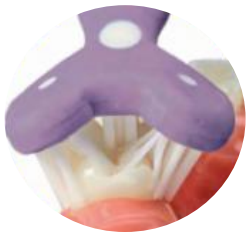1<sup>st</sup> to 7<sup>th</sup> September: National Nutrition Week

7<sup>th</sup> – 9<sup>th</sup> November: 5<sup>th</sup> International Congress of Contemporary Pediatric Dentistry

19<sup>th</sup> – 22<sup>nd</sup> November 2025: 46<sup>th</sup> ISPPD National Conference

## PEDONOW

The Surround Toothbrush has three bristle pads that simultaneously cleans all surfaces of the teeth. This heart-shaped toothbrush is made of latex-free rubber and has soft, end-rounded bristles. They come in two variants – STB for all age groups, and STBC for toddlers (up to 5 years of age).



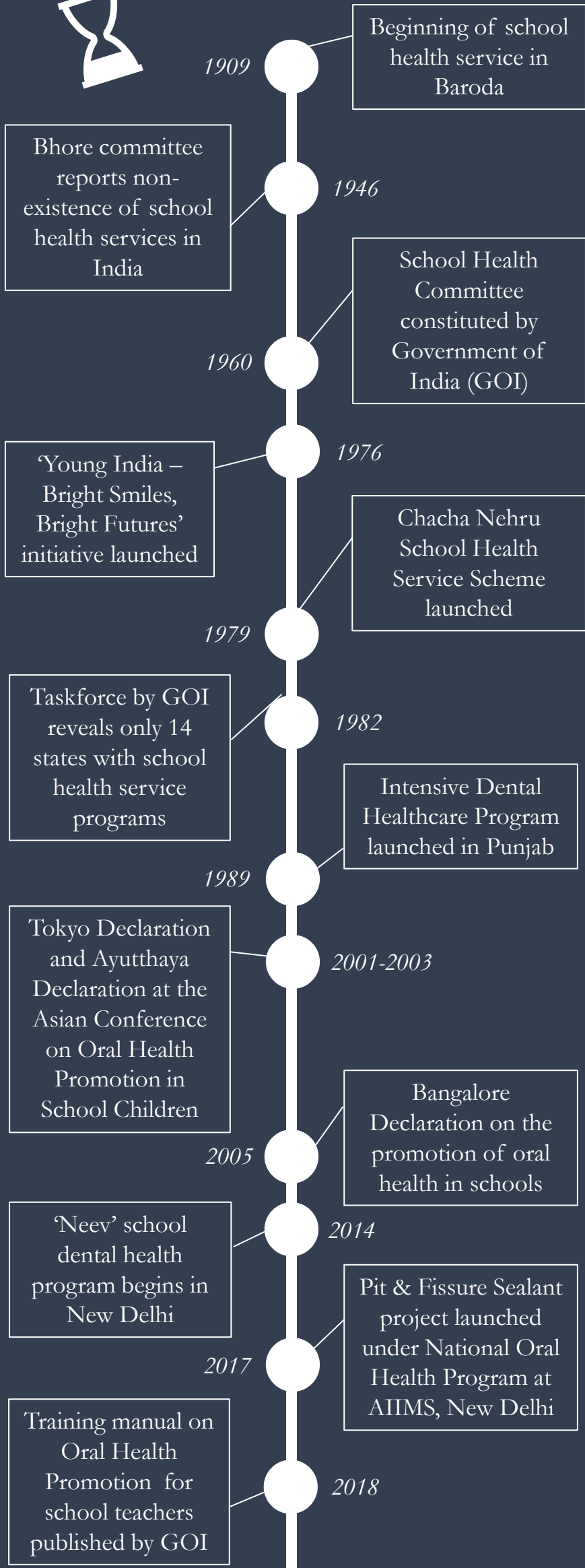
More: <http://bit.ly/44jNUzZ>

## ODONTOINDIA

Dezy, India's fastest growing digital dental chain has been named among the World Economic Forum's Top 100 Technology Pioneers. Dezy's revolutionary work involves the inculcation of cutting-edge technology in clinic with patient care ranging from online consultations, at-home dental services, or virtual assistance. It is headed towards an AI-integrated, convenience-first, and user-led care models.

Link to its official website: <https://www.dezy.com/about-us>

## ODONTORETRO

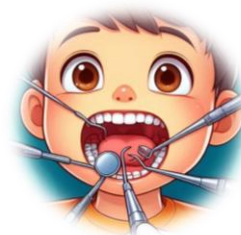

## THE VALIANT PERCH OF THE PEDIATRIC DENTIST

Adults are often mortified at the sight of a needle. They are petrified even more when this scenario plays out in the dental clinic. Seconds later, terror ensues when they see the little bur within the dental drill spinning at a high rate while simultaneously dispatching a flurry of water droplets. Within a short span of time, the mind pans out stills of painful images while keeping up with the heavy bag of the local anesthetic deposited on one of the cheeks. Some wail, some groan, some moan, a few wish to atone, and only a handful behave like what they are – adults.

Human behavior is shaped through events that may or may not be experienced by an individual. A dental visit is rarely a matter of celebration, and irrespective of the age they live in, a painless visit to the dentist is a wish that most ask for at least once in their lifetime. If the atrocities mentioned above are to be translated for a child, it becomes an uphill task for odontologists to deliver a successful treatment. For decades now, the specialty of pediatric dentistry has focused on dealing with the psychology and behavior of the child in the dental clinic. Much has been spoken regarding the heroics of pediatric dentists in this domain. Hence, it is now time to view a dental visit through the lens of the bearers of milk teeth, and in turn realize how they soldier their mind through a dental procedure.

Imagine putting in two pairs of hands, wielding dental instruments, inside a wide-open mouth through which even a cheese ball struggles to squeeze its way through. This oral cavity has a bite block fixed on one side, ensuring the tooth to be treated is accessible. But for our young soldier, it is a




hard filling of a sandwich that is resistant to compression. Moreover, we are talking about an oral cavity that is almost always in constant motion to cope with the unpleasant stimuli. The dental light shines strongly in front of their eyes, the sound of the air turbine constantly drums their eardrum, the nose receives an influx of unpleasant odor from the infected tooth, and various medicaments repeatedly assault the tongue. Amidst these physical caresses, the heart yearns to go to the parent as the human behind the mask continues their effort to tame the child's psyche.

Another stratum that complicates the matter for these younglings is their limited ability to communicate, which eventually hinders their ability to express their feelings. The vision of a tear-eyed kid melts any human heart. Some clench their fists firmly, while others flutter kick onto the dental chair. Eventually, the high-pitched shrills are the final nail in the coffin to signal the termination of their tolerance. For the dental surgeon, the appointment ends, but the treatment might remain. Another stratum – a recall, a follow-up, a visit where the child is likely to time-travel to the latest experience.

It is here that we understand why pedodontists are always pursued as heroes. The ability to choose the right behavior guidance technique for each child, depending on their age and behavior, the promise to take care of the little teeth that help them speak, smile, and chew, and the eventual appreciation of acknowledging the child's bravery is what makes pediatric dentistry heroic in every regard.

# SPOT THE DIFFERENCES

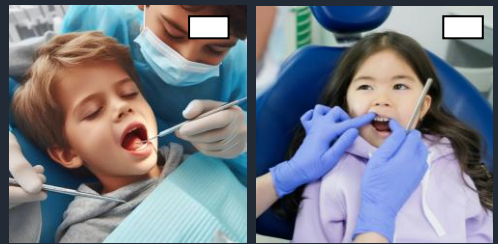

## WORD SEARCH

Enamel,  
Dentin, Pulp,  
PDL, Apex,  
Root Canal,  
Cementum,  
Alveolus,  
Gingiva,  
Periodontium

A	T	U	A	O	N	T	O	O	R	C	L	P	R
L	X	E	P	A	I	P	L	L	P	P	D	L	P
N	A	O	L	A	U	A	P	P	P	C	I	E	P
V	A	I	O	L	I	G	E	M	A	N	R	L	N
P	T	P	P	T	V	P	U	V	L	I	D	M	I
N	E	A	P	R	N	T	I	P	O	E	C	D	T
I	T	U	A	V	N	G	R	D	P	T	M	T	E
U	M	M	R	E	N	A	O	I	E	L	N	O	N
V	T	T	M	I	G	N	E	L	L	D	E	M	L
N	N	E	G	R	T	S	U	L	O	E	V	L	A
E	C	M	L	I	G	N	I	T	N	E	D	N	U
U	M	I	U	D	X	U	T	L	E	I	N	U	P
L	N	M	N	I	L	E	M	A	N	E	P	C	S
R	O	O	T	C	A	N	A	L	N	D	N	I	P

# TICK THE AI-GENERATED IMAGE



## 1-MINUTE GAME

Write a list of all toothpaste brands you can think of in 60 seconds.

## ANAGRAM SOLVER

REARVC  
THECHAT  
PERLOXER

## STUDYING TECHNIQUE

The Feynman Method is one way to ensure that you have thoroughly understood a topic. It is done by imagining teaching that topic to a 5-year-old.



## The Wilkerson Dental Chair

YOU can pay a higher price, but you cannot get a better-made chair at any money than the Wilkerson. It is built to endure the use to which it is put. It will last almost a lifetime. There are plenty of them still in good form after more than twenty years' active service. It has all the movements which go to make operating easy for patient and operator. At its price, also, it is the cheapest chair at the service of the dentist.

**PRICES**

Foot-boards covered with Wilton Carpet or Rubber

In Green or Maroon Plush, with Watkins Sectional Head-rest as shown	\$125.00
In Green or Maroon Plush, with Wilkerson Head-rest	125.00
In Green or Maroon Plush, padded with Plush, trimmed with Silk Cord, with Watkins Sectional Head-rest	155.00
In Green or Maroon Plush, padded with Plush, trimmed with Silk Cord, with Wilkerson Head-rest	145.00
With Foot-boards covered with Cork Carpet (green or red) adds to above prices	4.00
Cork Carpet Foot-boards for the Wilkerson Chair (regular)	7.65 per set



CLASSIC AD

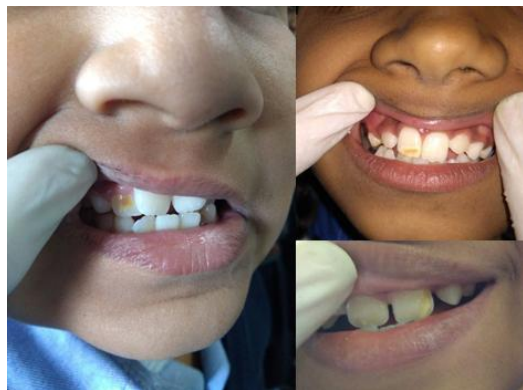S.S. White Dental Manufacturing Co | Dental Cosmos | 1907

The Entry Level Dental Clinics Certification Program, offered by the National Accreditation Board for Hospitals & Healthcare Providers (NABH), is designed to guide understanding of the NABH Certification Process. This certification program has a validity of 2 years and is recommended for owners, managers, administrators, and quality managers associated with a dental clinic setup with at least eight dental chairs. The NABH's official website hosts further details on this program.

## COURSE OVERVIEW

## PEEKABOO

Can you identify what the image depicts?



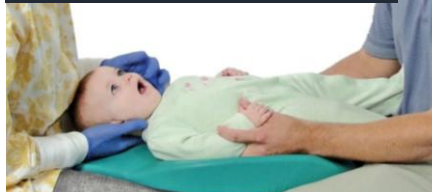Answer: Turner's Hypoplasia that arises due to disruption in enamel formation due to periapical infection in the predecessor primary tooth. It is most often seen in incisors and premolars.

## ACADEMEMEICS

When you're presenting at a conference and the buffet opens



## CLINICAL DECOR



Lap boards in the pediatric dental clinic facilitate easy examination of the infant's oral cavity.

## VOGUE



Scrub caps wore by pediatric dentists can come with designs that attract children!

Sinusitis is the inflammation of the sinuses due to an infection. Of all the sinuses in the facial region, the maxillary sinus has a direct association with the upper teeth. Oftentimes, sinusitis can cause pain that is referred to the upper teeth. Patients might feel they have a toothache, but in reality, the upper back teeth and the maxillary sinus share the same nervous supply. Once the teeth are rendered healthy, treatment should be started against sinusitis, which will eventually resolve the toothache.

In the earlier times of my clinical learning, I struggled with crown preparation in the upper molars. In hindsight, it was a result of lack of experience in tactile sensation, less awareness on anatomical variations, and a clinical confidence which built over a period of time. In the upper molars, accessibility and visibility in the pediatric oral cavity was also a challenge. The consequence of it was often seen as a ledge formation. But I believe it was experience that eventually taught me how to control the angulation of the bur and how the anatomical variations can be tackled. Not only did the chances of me creating a ledge decreased, but if ever there was one, then I knew how to rectify it!

- Second Year Post-Graduate Student (Pediatric & Preventive Dentistry, CDSRC)

**HICCUP**

Earlier when I started with pulpectomies, I didn't find confidence in locating the canals. Moreover, there was also a fear of perforating the pulpal chamber due to no awareness of the tactile sensation. So I decided to understand the anatomy of the tooth and concurrent with each case, I started understanding the common dentinal maps and the optimum width of deroofing the pulp. During this time, I also learnt how to effectively use the Endo-Z bur. Today I find it much easier to locate the mesiolingual canal, with which I initially struggled. I take my learning curve as one wherein I focused on my own growth rather than comparing the relative ease with which my peers were able to perform the same procedure.

- Second Year Post-Graduate Student (Pediatric & Preventive Dentistry, CDSRC)

**ONE-UP**

I never particularly struggled while performing pulpectomies. But there was always this constant feeling where I believed that I am not conserving the sound tooth structure enough. Oftentimes, simply to ensure that I have a greater area to access for biomechanical preparation, I would widen the cavity by including even the sound tooth structure. But then I started to keep my access cavity as minimal as possible. After a few cases I began realizing that even a minimal preparation can facilitate cleaning and shaping of the canals. I continue to strive to achieve perfection in this regard.

- Second Year Post-Graduate Student (Pediatric & Preventive Dentistry, CDSRC)

**MOON'S CRATER**

An opportunity for the ones who dare!  
Stand a chance to be published in our forthcoming edition! Write in no more than 400 words on one of the following topics:

- Cricket and pediatric dentistry
- A detective tale on the 'Murder of the first primary molar'
- A visual depiction of things that go inside a dental student's brain

**THE SILLY SENSE**



**THANK YOU CONTRIBUTORS**

Prof Dr Anup Panda • Prof Dr Krishna Dere • Prof Dr Mira Virda • Dr Jina Jani • Dr Deepika Chari • Dr Balraj Shukla • Dinesh Gohel • Rakesh Vaniya • Dr Yashwi Doshi • Dr Rashmita Dalsaniya • Dr Tanvi Jadeja