

TPLO Radiographic Technique

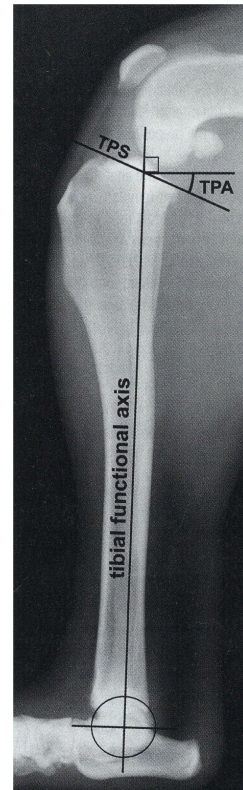
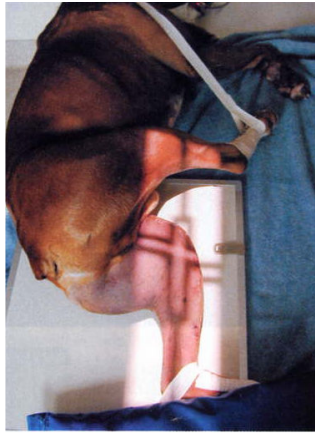Positioning for TPLO Films:

(under sedation or anesthesia)

Lateral view:

Use a large film cassette and place it under the patient so that the hip, stifle and tarsus are all resting on the plate (if the dog is too big, place a second plate next to the first). Pull the unaffected leg away (abduct or pull cranial) Position the stifle and tarsus at right angles.

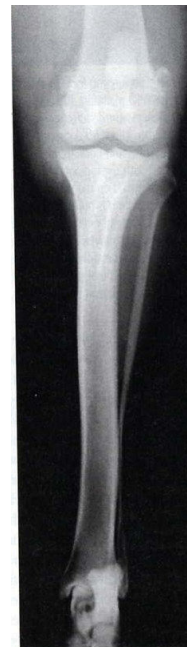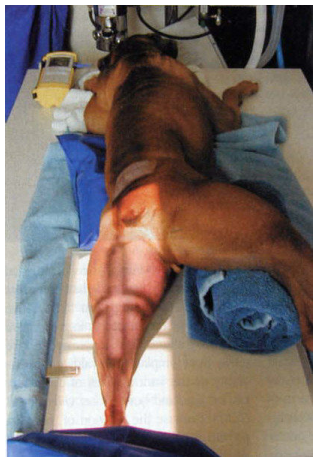Center the beam on the stifle or as close to it as possible. Be sure to include the stifle, entire tibia and tarsus in the exposure. In the radiograph the femoral condyles should overlap.



Caudal-Cranial View:

The patient is positioned in sternal recumbency. Use a large cassette (or the unexposed half of the previous cassette if there is room). Pull the affected limb distal and straight so that the patella rests on the cassette. Do not twist or rotate the tarsal joint or paw. Center the crosshairs on the stifle again. Include the stifle, entire tibia and tarsus in the exposure.

In the radiograph the patella should be centered between both fabella. The medial border of the calcaneus should be aligned with the center of the distal tibia.



Illustrations are reproduced from the following sources:

Images from: Palmer RH. Understanding tibial plateau leveling osteotomies in dogs. Vet Med 100: 426-436, 2005