

RadAnat 2026: Online Workshop on Radiological Anatomy

Learn. Visualize. Interpret



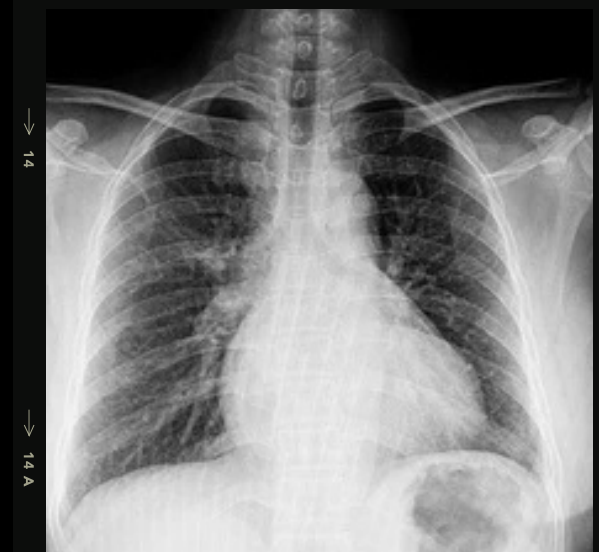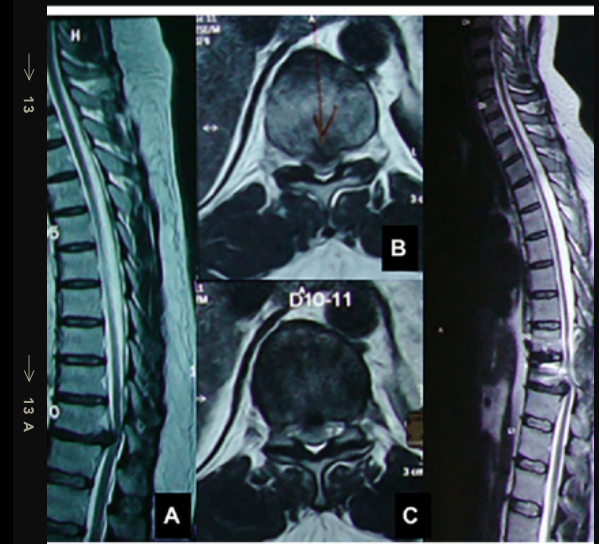
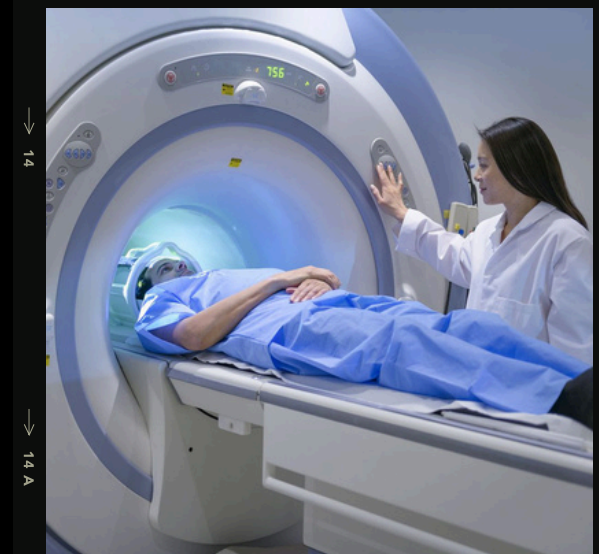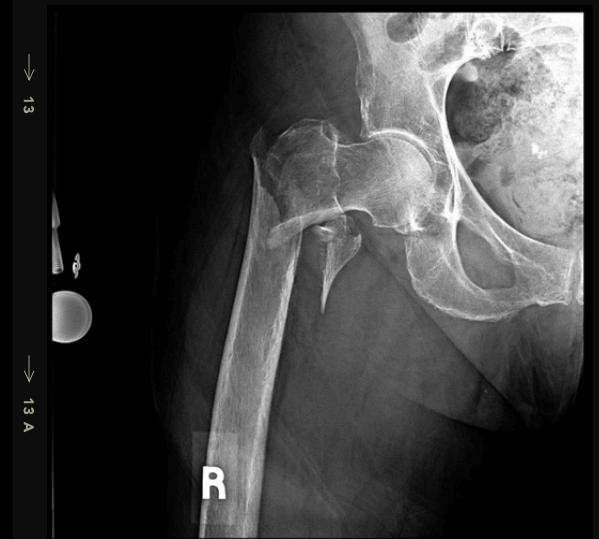20 to 30 April, 2026 | 7:00-8:00 PM IST Daily

Key Features

- E-Certificate on Completion
- Online Live & Interactive Sessions
- Software, Video and Image-Based Learning
- Real Radiograph & CT Case Examples
- Expert Faculty from Radiology & Anatomy
- Lecture PPTs and Recording of the sessions



REGISTER NOW



RadAnat 2026

About the Workshop

Discover how anatomy comes alive through medical imaging. This interactive 2-week online workshop bridges textbook anatomy and diagnostic radiology, helping learners visualize human structures on X-ray, CT, MRI, and ultrasound. Through expert-guided video sessions and image-based learning, participants will gain hands-on understanding of anatomical landmarks, skeletal features, and positioning principles used in diagnostic imaging

Who can join?

- B.Sc., M.Sc. Radiology & Medical Imaging Students
- Allied Health Science, Paramedical Students and Faculty
- Aspiring Radiology Interns and Imaging Technicians
- Beginners seeking a foundation in Radiological Anatomy

Global Timings

India	7:00 PM
New York	9:30 AM
Singapore	10:30 PM
Saudi Arabia/Qatar	4:30 PM
Dubai/Oman	5:30 PM
Australia	11:30 PM

Training Fee

- Students (India): ₹1499
- Faculty / Professionals: ₹1999
- International Participants: \$ 85 (USD)

Course Module

Week 1: Fundamentals of Radiological Anatomy

Introduction to Radiological Anatomy

- Scope and applications in diagnostic imaging
- Comparison between gross anatomy and radiological anatomy
- Understanding tissue densities and image contrast

Anatomical and Radiological Terminology

- Body planes (sagittal, coronal, transverse)
- Anatomical positions and movement terminology
- Radiographic symbols, abbreviations, and orientation markers

Identification of Key Anatomical Landmarks on X-ray, CT, and MRI

- Correlation of surface anatomy with imaging anatomy
- Recognizing normal radiographic appearances of major regions (head, chest, abdomen)

Standard Radiographic Positions and Projections

- PA, AP, lateral, and oblique views explained with examples
- Patient positioning techniques for common diagnostic studies

Learning Outcomes:

- Explain the role of radiological anatomy in medical imaging and clinical diagnosis.
- Identify body planes, anatomical landmarks, and orientations on radiological images.
- Understand patient positioning principles for high-quality imaging.

Assessment:

- Quiz: Body Planes & Positions
- Radiograph Spot Test: Landmark Identification

Course Module

Week 2: Skeletal Radiological Anatomy (Axial & Appendicular Skeleton)

A. Axial Skeleton

- **Skull:** Identify cranial and facial bones, sinuses, and sutures; interpret normal variants and common projection errors.
-
- **Vertebral Column:** Cervical, thoracic, lumbar, sacral, and coccygeal regions with characteristic vertebral features.
-
- **Thoracic Cage:** Recognition of ribs, costal cartilage, and sternum; differentiating between normal and pathological appearances.

B. Appendicular Skeleton

- **Upper Limb:** Shoulder girdle, humerus, radius/ulna, wrist, and hand – major bony landmarks and joint articulations.
-
- **Lower Limb:** Pelvic girdle, femur, tibia/fibula, ankle, and foot – recognizing anatomical alignment and developmental ossification centers.

Learning Outcomes:

- Identify major bones and joints on radiographs and CT images with anatomical precision.
- Recognize ossification centers, growth plates, and key skeletal landmarks.
- Differentiate normal anatomical variations from pathological changes.

Assessment:

- **X-ray Labeling Activity:** Identify skeletal regions and bony features.
- **CT Bone Anatomy Quiz:** Apply anatomical knowledge to interpret 3D bone structures.



CATR
Centre for Advanced Training and Research



CERTIFICATE OF PARTICIPATION

This certificate is presented to

For participating in the **“RadAnat 2026: Two-Week Online Workshop on Radiological Anatomy”** organized by Centre for Advanced Training and Research, Lucknow, U.P. (India) from 10-20 January 2026.

Director
CATR