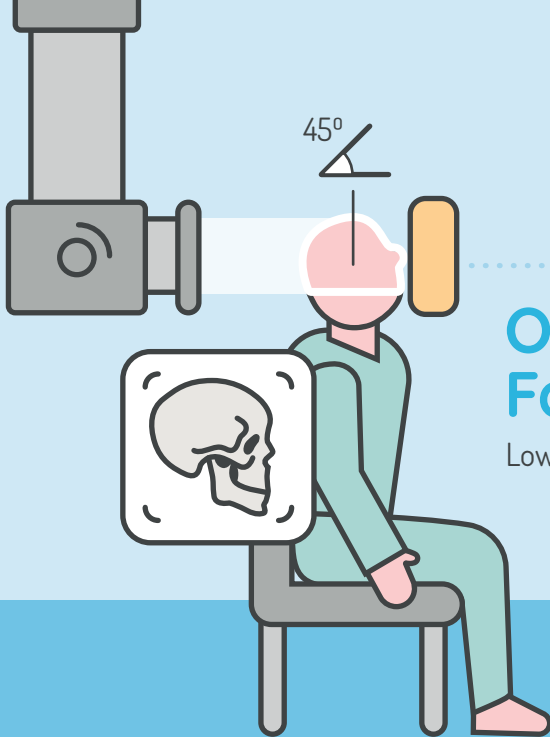


# Visual Reference Book

Radiographic Positioning

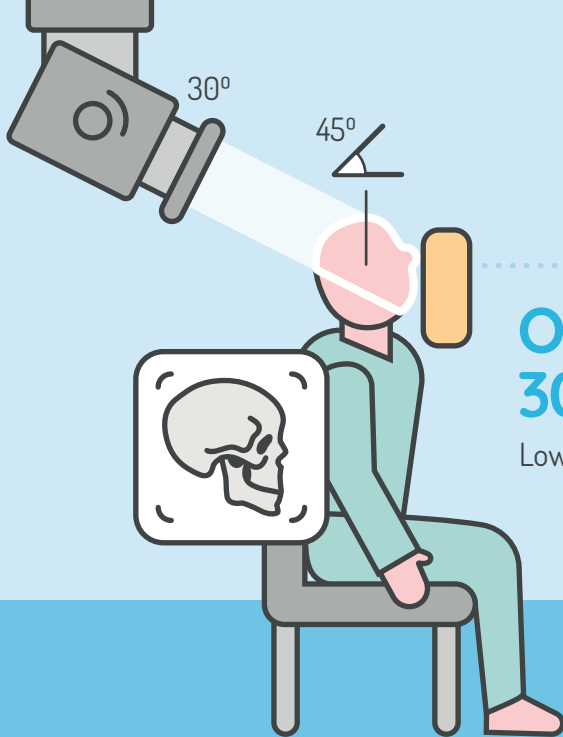


**SoR**  
THE SOCIETY OF  
RADIOGRAPHERS



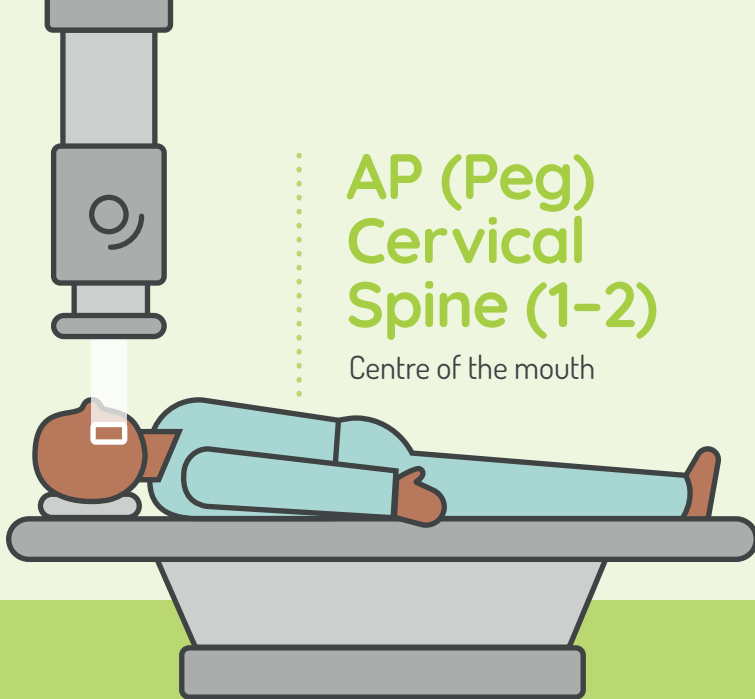
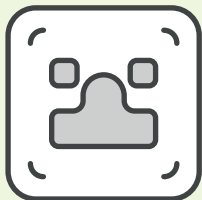
# Occipitomental Facial Bones

Lower orbital margins




# Occipitontal 30° Facial Bones

Lower orbital margins



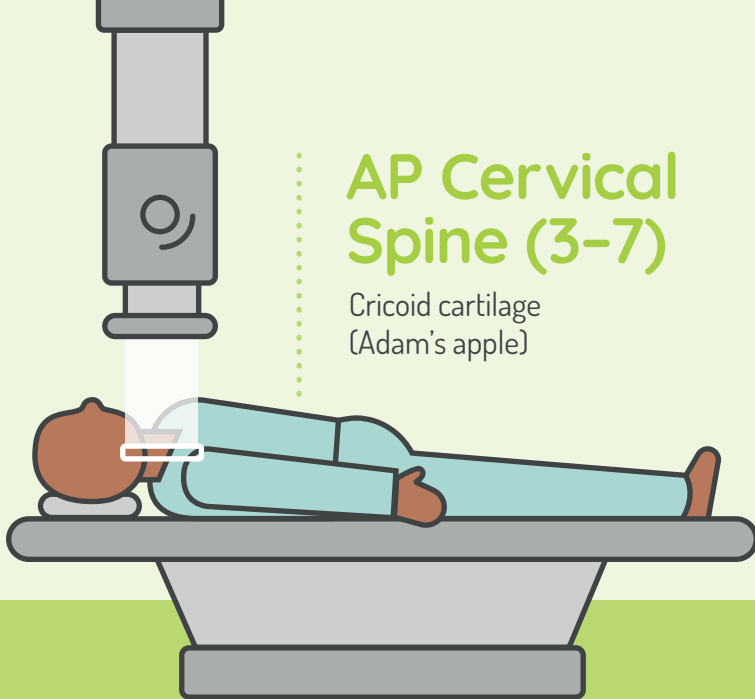
# AP (Peg) Cervical Spine (1-2)

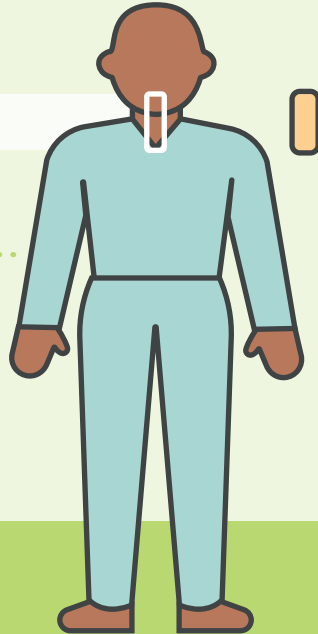
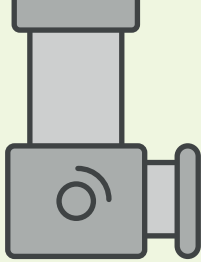

Centre of the mouth



## AP Cervical Spine (3-7)

Cricoid cartilage  
(Adam's apple)

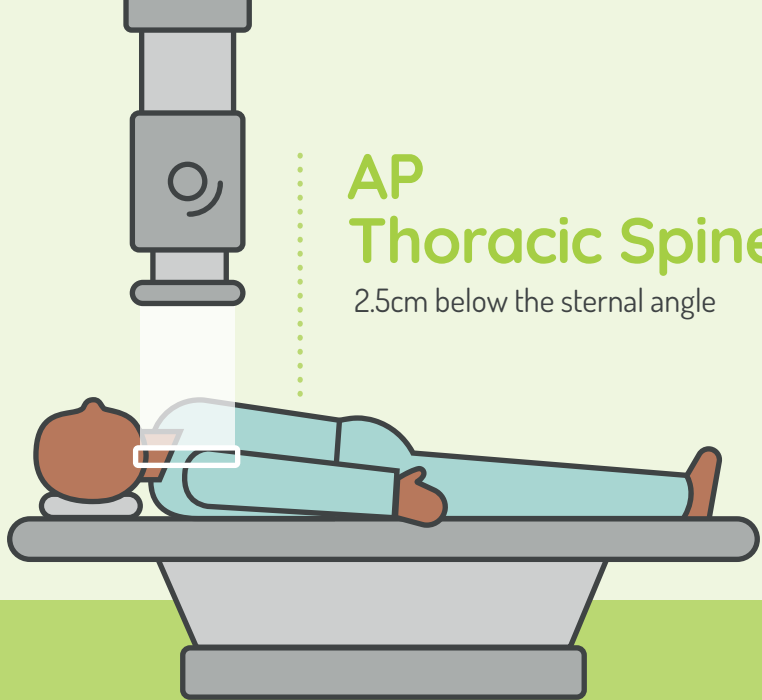
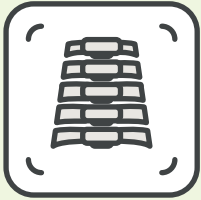



## Lateral Cervical Spine

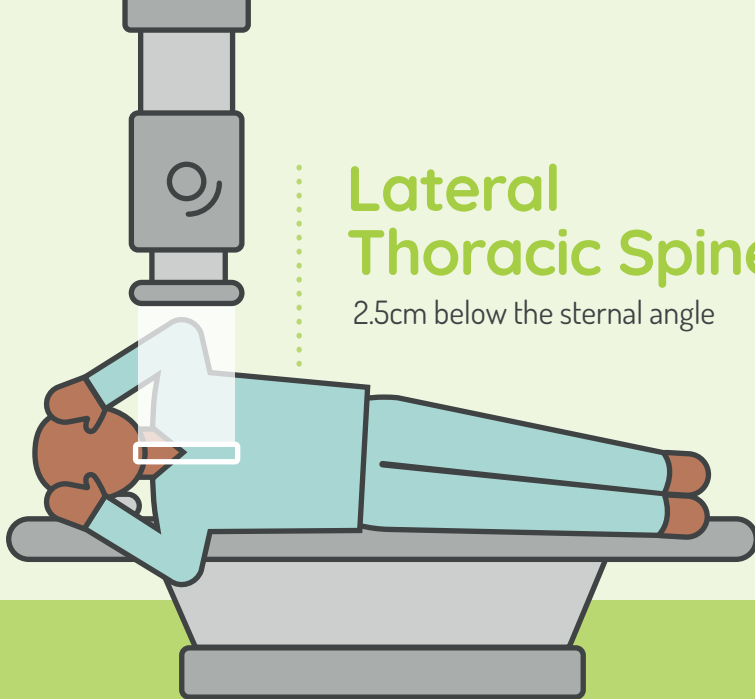
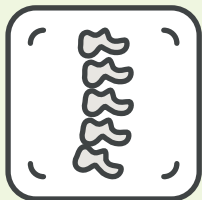
2.5cms posterior and inferior from  
the angle of mandible

Trauma patients should remain lying down



# AP Thoracic Spine

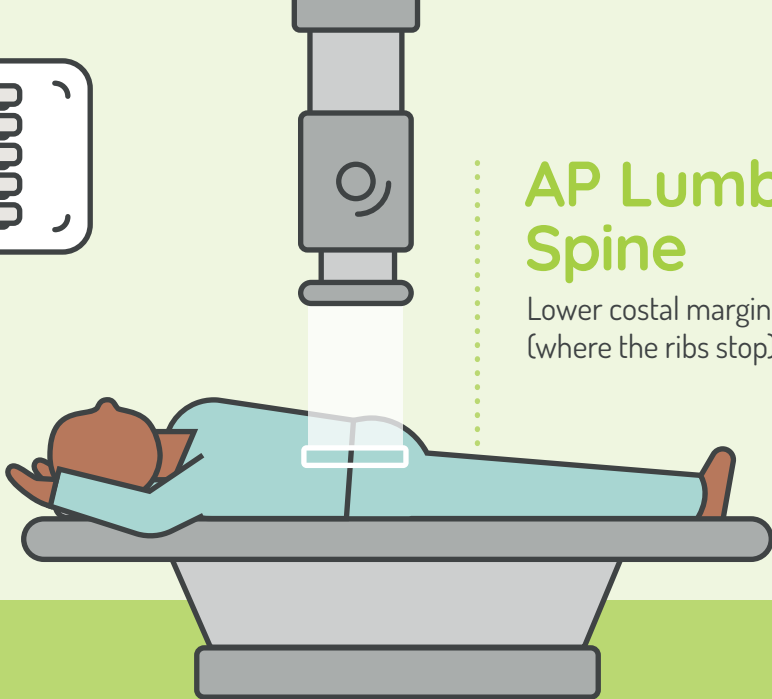

2.5cm below the sternal angle



## Lateral Thoracic Spine

2.5cm below the sternal angle





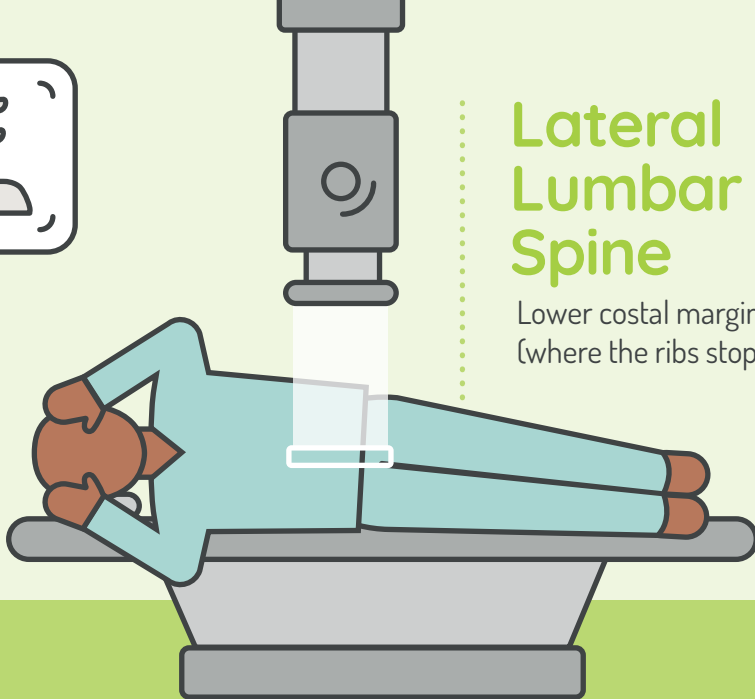
## AP Lumbar Spine

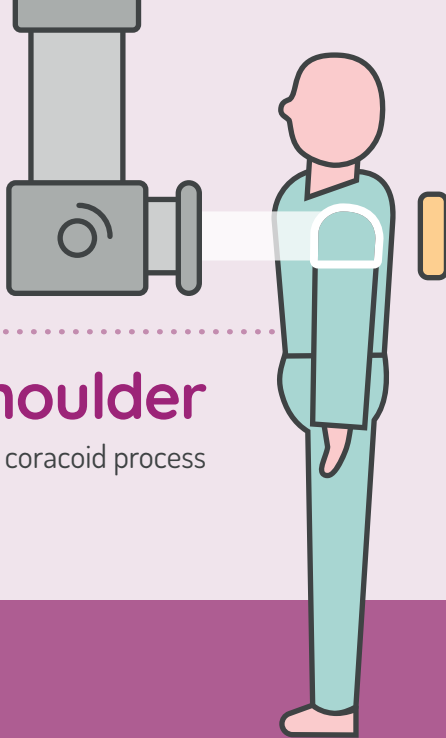
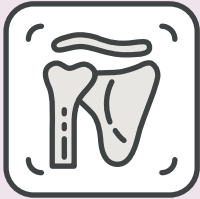Lower costal margin  
(where the ribs stop)



# Lateral Lumbar Spine

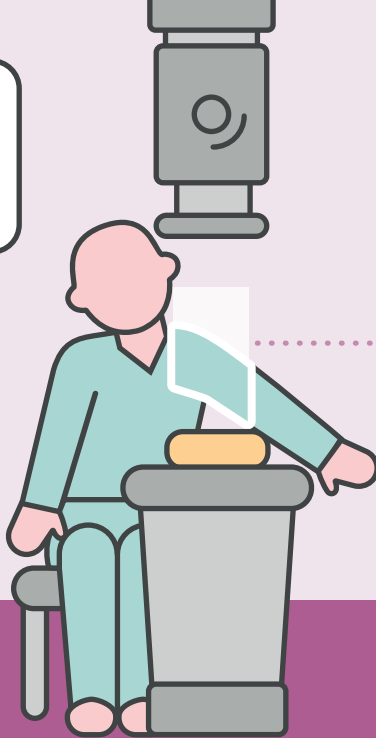
Lower costal margin  
(where the ribs stop)





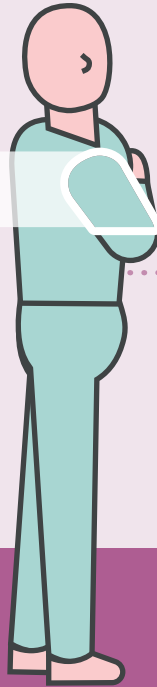
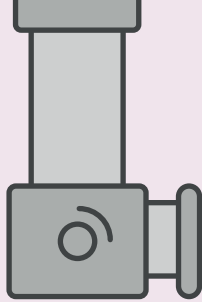
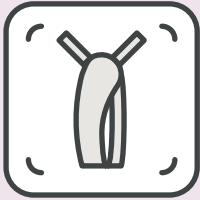
# AP Shoulder

Palpable coracoid process



# Axial Shoulder

Mid-glenohumeral joint

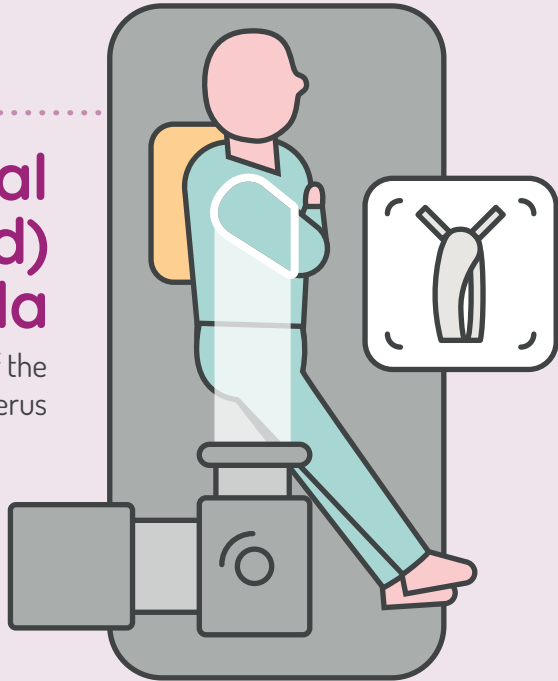


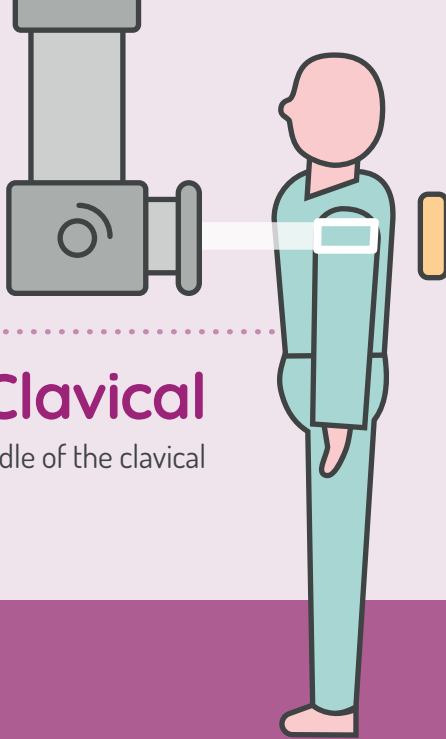
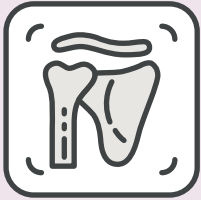# Lateral Scapula

Medial border of the  
scapula/head of humerus

# Lateral (adapted) Scapula

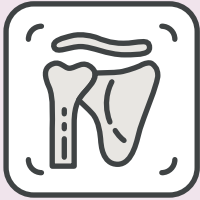Lateral border of the  
scapula/head of humerus





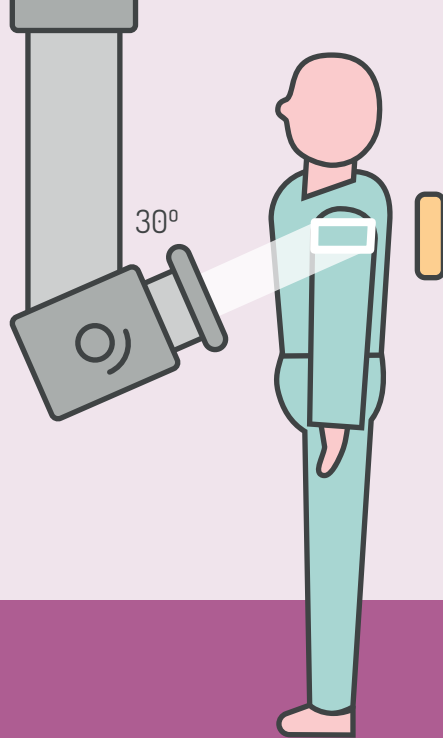
# AP Clavical

Middle of the clavical

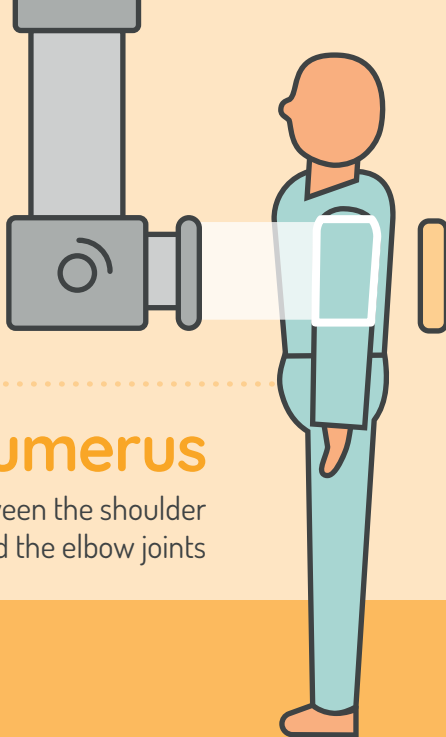
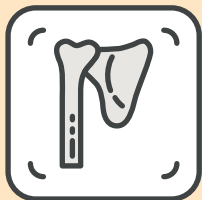

# Modified Axial Clavical

Middle of the clavical


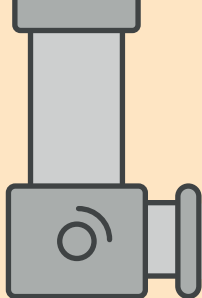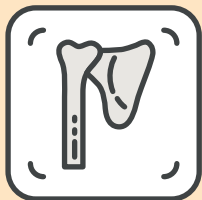






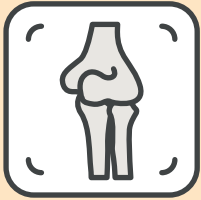
## AP Humerus

Midway between the shoulder  
and the elbow joints



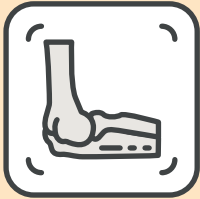
# Lateral Humerus

Midway between the  
shoulder and the elbow joints




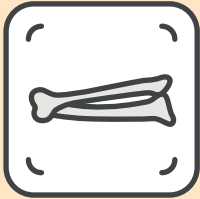
## AP Elbow

Between the epicondyles  
of the humerus




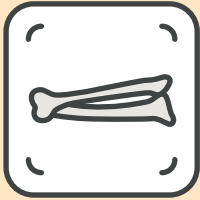
# Lateral Elbow

Lateral epicondyle



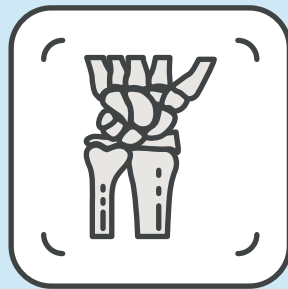

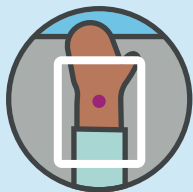
## AP Forearm (Ulna/Radius)

Midway between the wrist and  
elbow joints



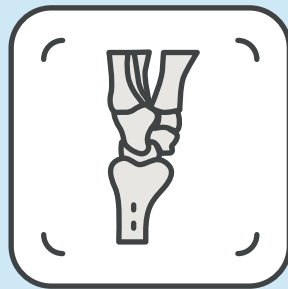
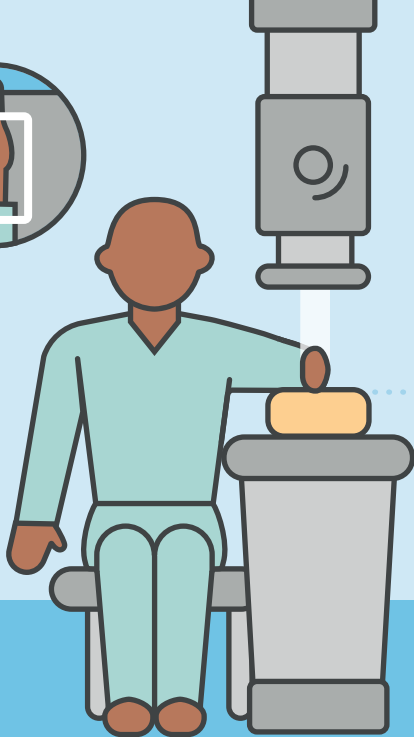
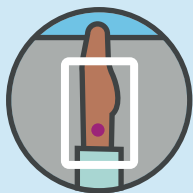
## Lateral Forearm (Ulna/Radius)

Midway between the wrist and elbow joints



## PA Wrist

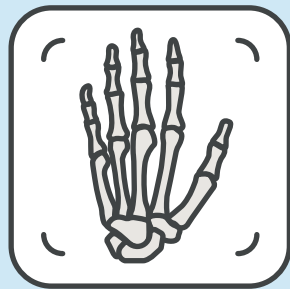


Midway between the  
styloid process



## Lateral Wrist


Radial styloid process



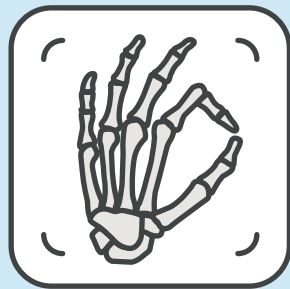


## DP Hand

Head of the third metacarpel




External Rotation  
(From DP lift the  
thumb 30-45°)

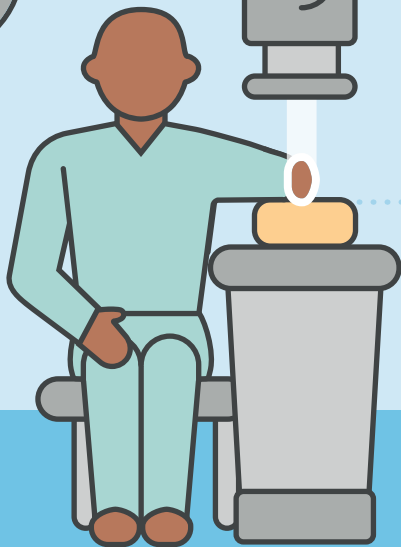
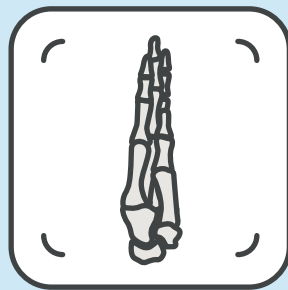


## Oblique Hand

Head of the third metacarpel

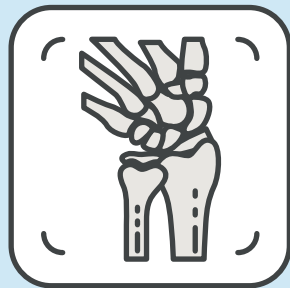


Make sure to use  
an FB marker



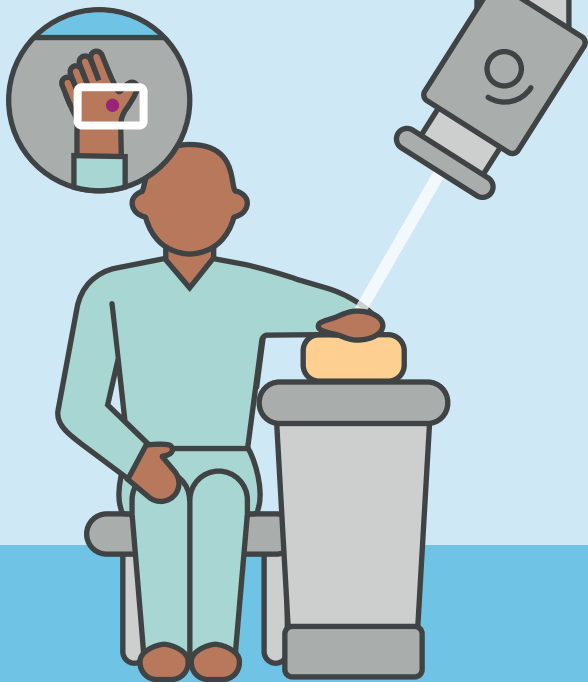
## Lateral Hand

Head of the second metacarpel



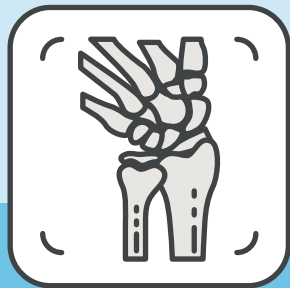## PA (ulna deviation) Scaphoid

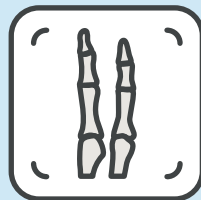
Radial fossa (anatomical snuff box)



## PA (ulna deviation) 30° Scaphoid

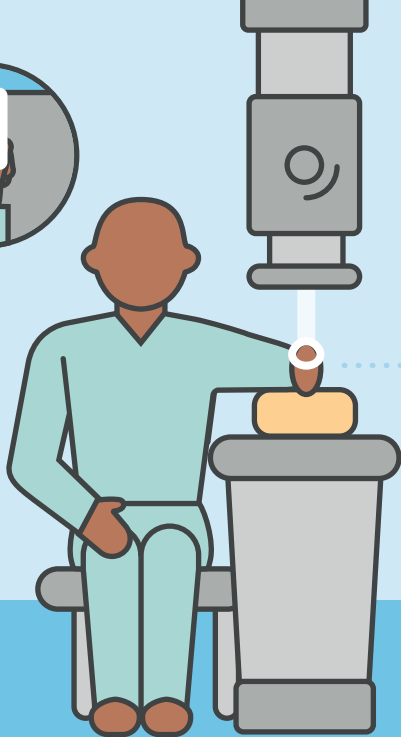
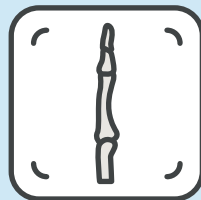

Radial fossa  
(anatomical snuff box)





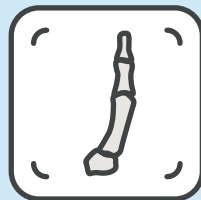
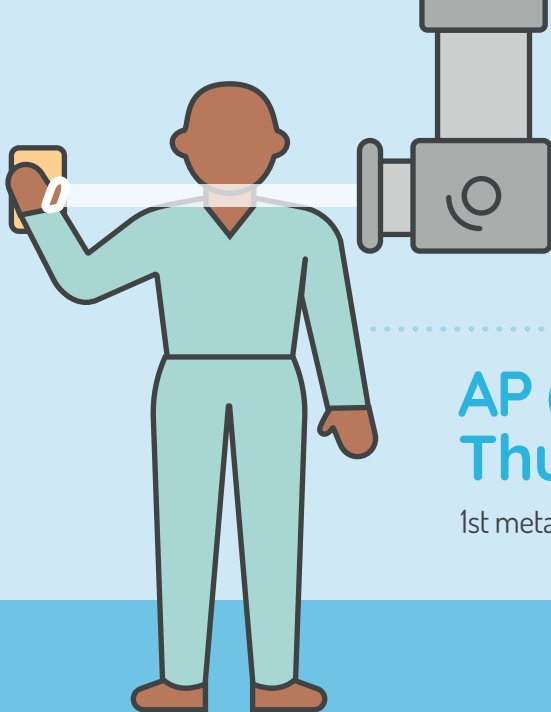
## DP Fingers

Proximal interphalangeal joint  
(include adjacent finger)



# Lateral Fingers

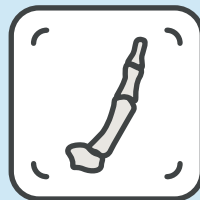
Proximal interphalangeal joint



## AP (standing) Thumb

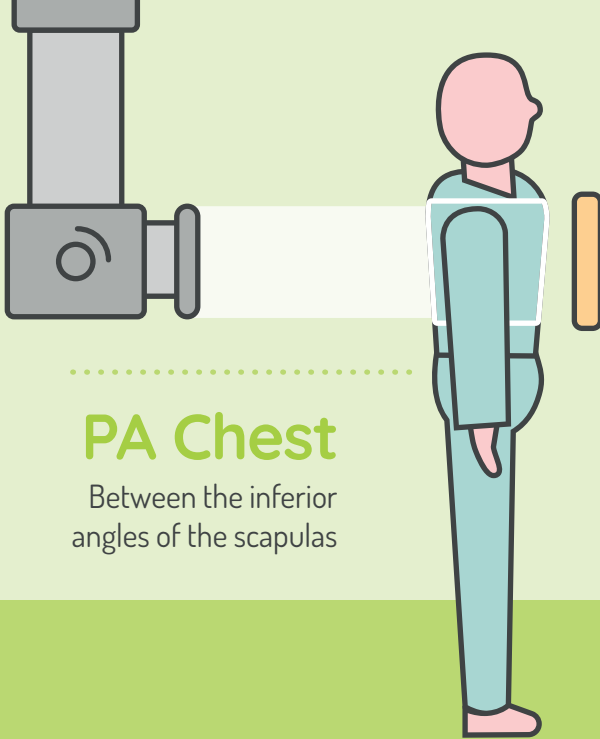
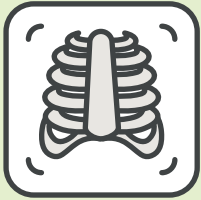
1st metacarpophalangeal joint (MCPJ)





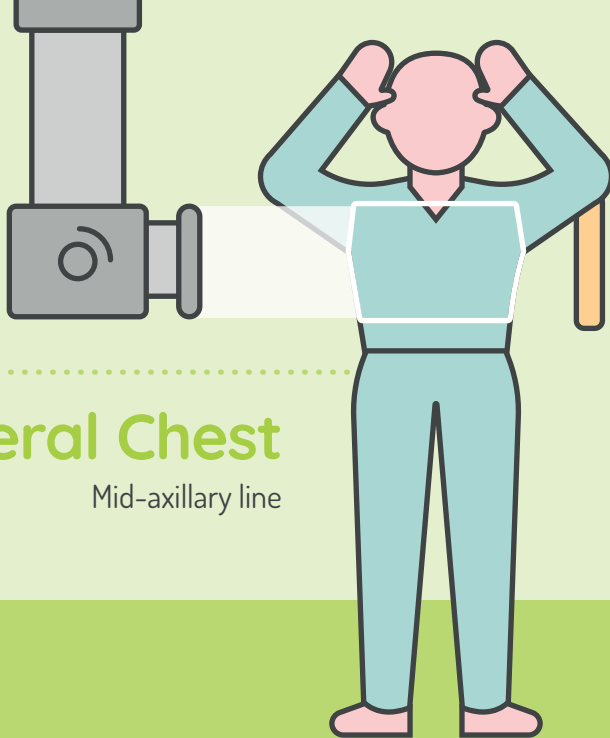
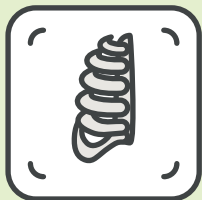# Lateral Thumb

1st metacarpophalangeal joint (MCPJ)



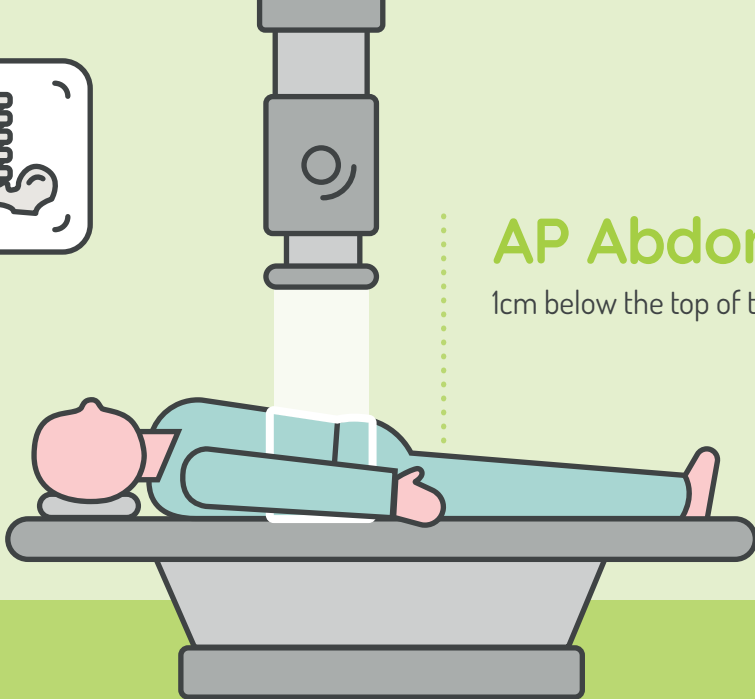
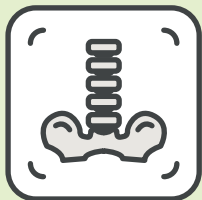## PA Chest

Between the inferior  
angles of the scapulas



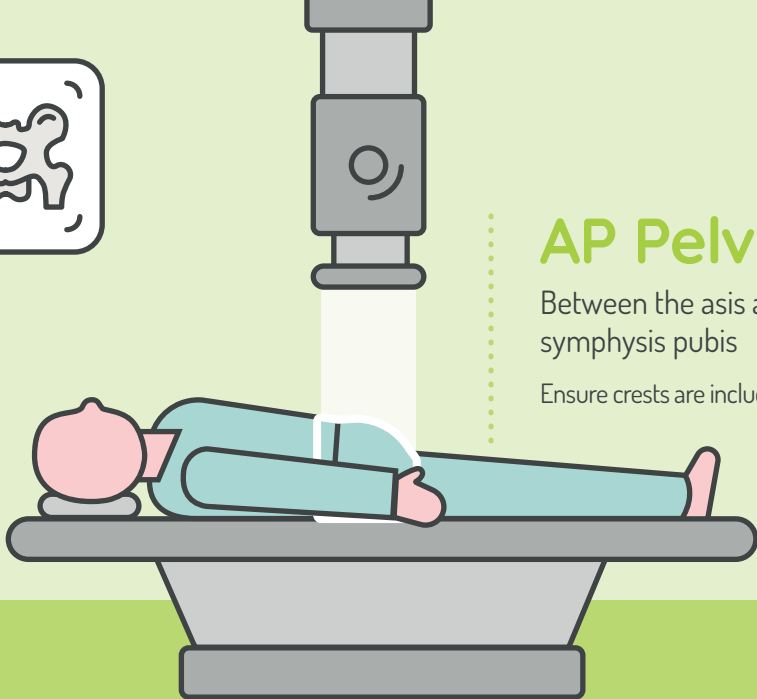
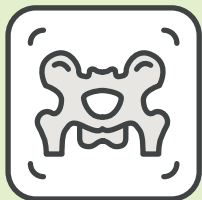# Lateral Chest

Mid-axillary line



## AP Abdomen

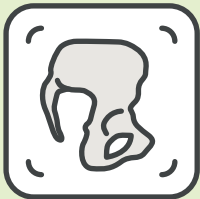1cm below the top of the crest



## AP Pelvis

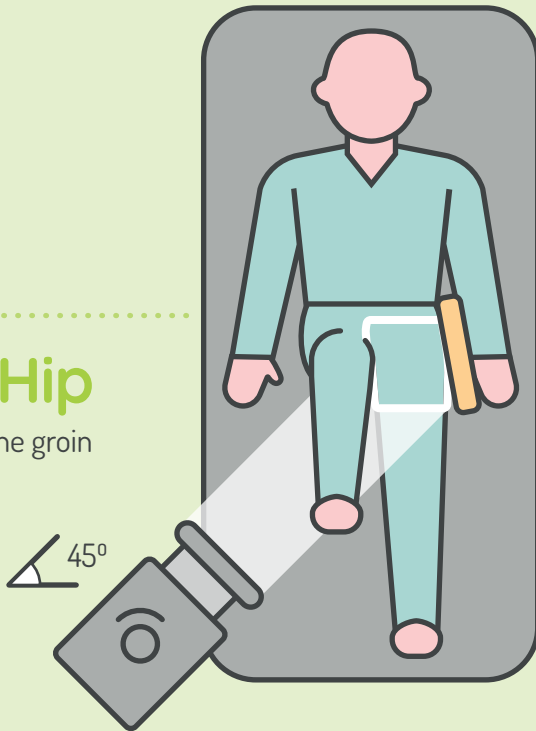
Between the asis and the  
symphysis pubis

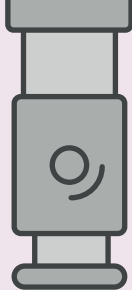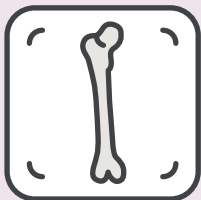
Ensure crests are included



## Lateral Hip

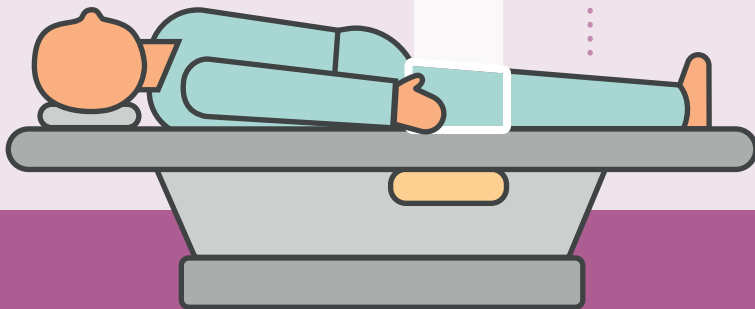Crease of the groin

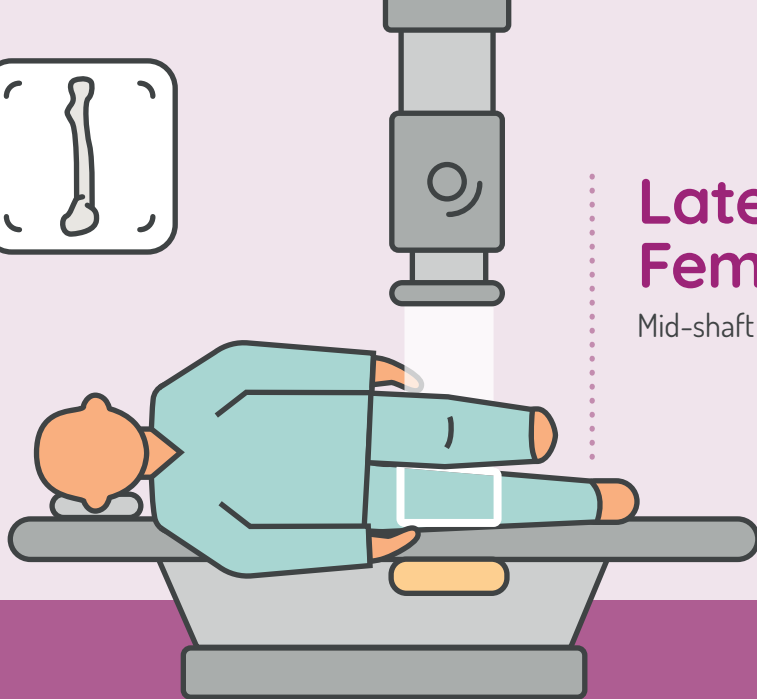
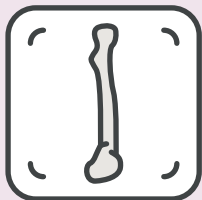




# AP Femur

Mid-shaft of the femur

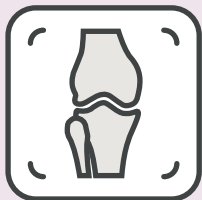



# Lateral Femur

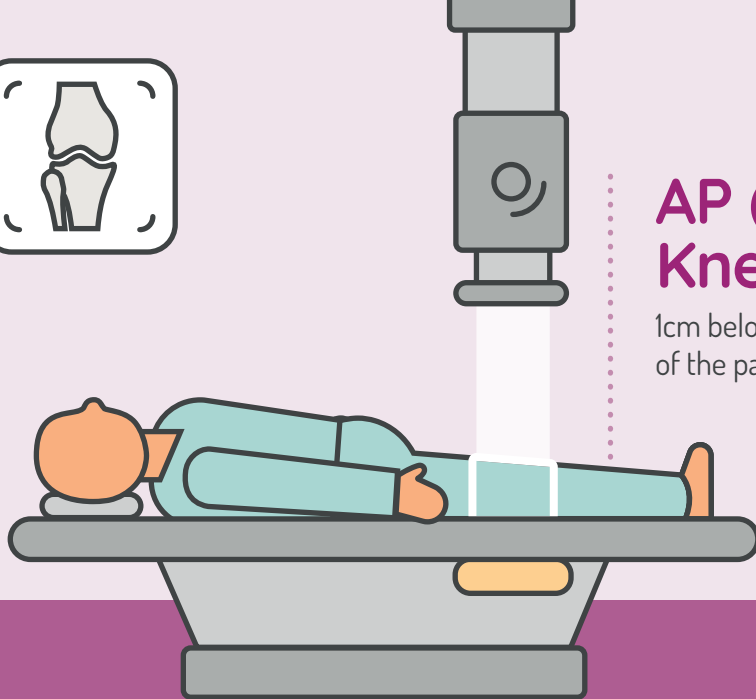
Mid-shaft of the femur

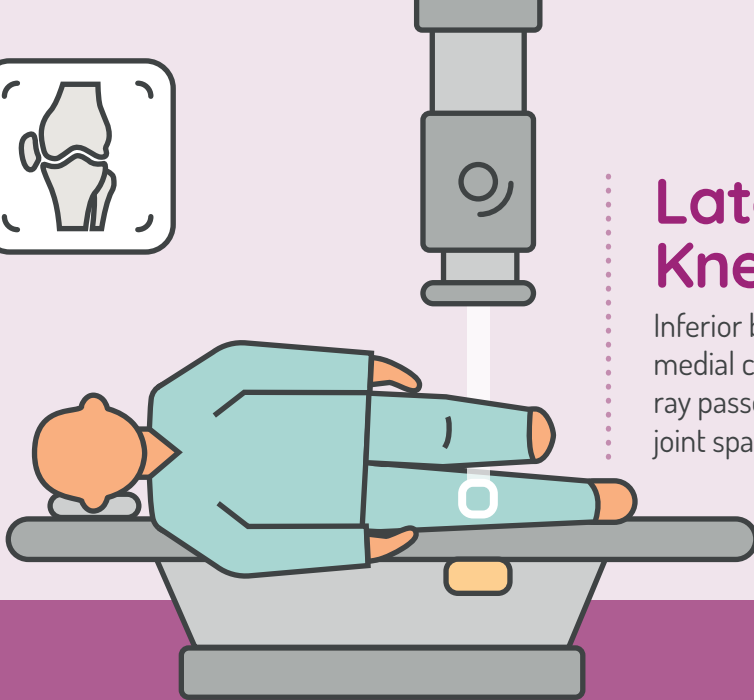
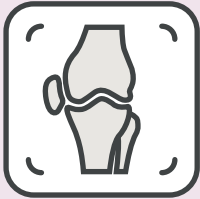



# AP (supine) Knee


1cm below the apex  
of the patella





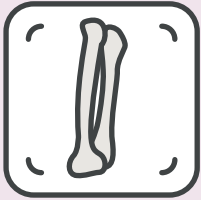
## Lateral Knee

Inferior border of the  
medial condyle (so the  
ray passes through the  
joint space)



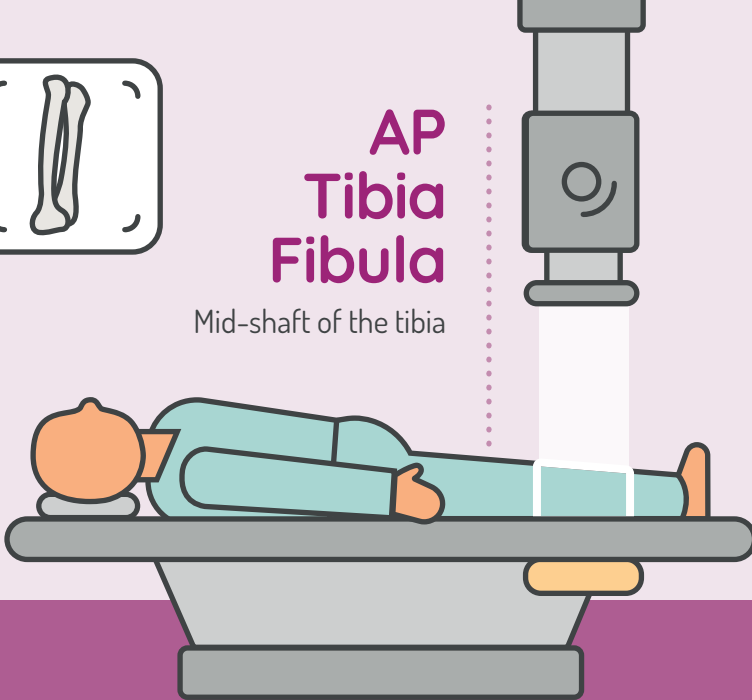
# Skyline Knee

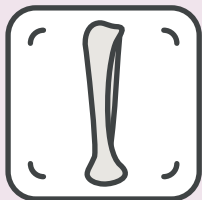
Apex of the patella



# AP Tibia Fibula

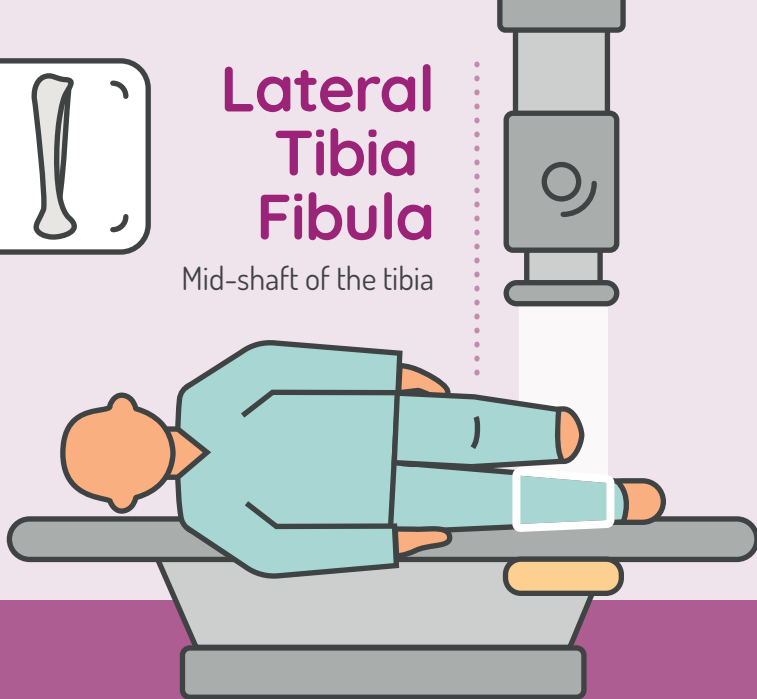
Mid-shaft of the tibia

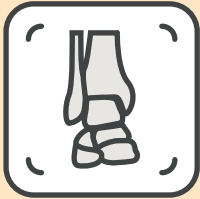



# Lateral Tibia Fibula

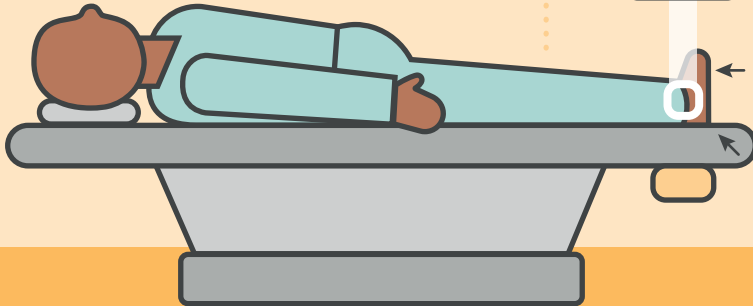
Mid-shaft of the tibia



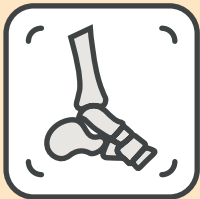

## AP (Mortise) Ankle

Midway between the  
two malleoli

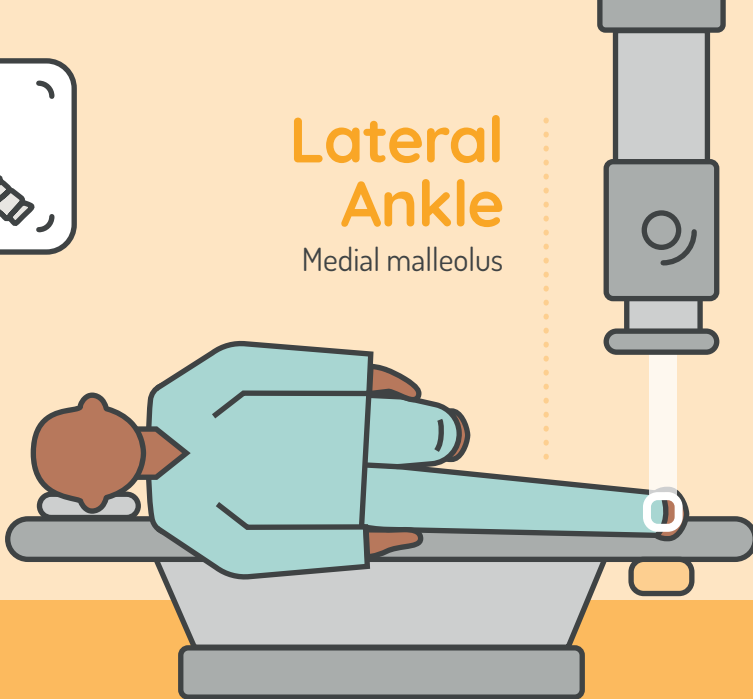


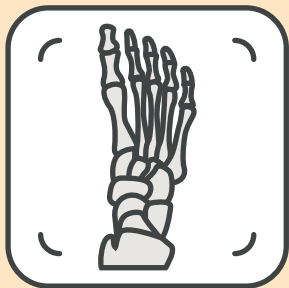1. Dorsiflex as much as possible
2. Slightly medially rotate until the malleoli are equidistant from the detector



# Lateral Ankle

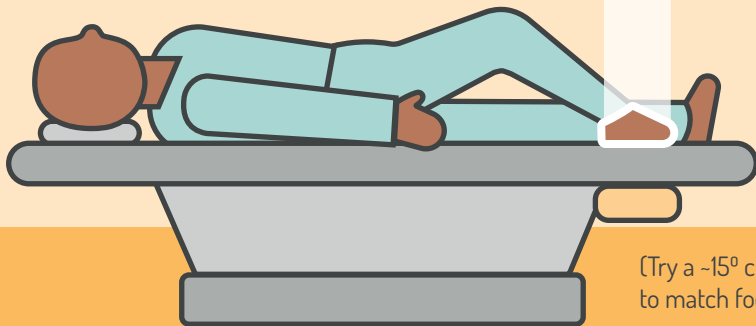
Medial malleolus





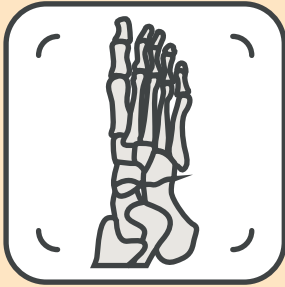
## DP Foot

Cuboid-navicular joint



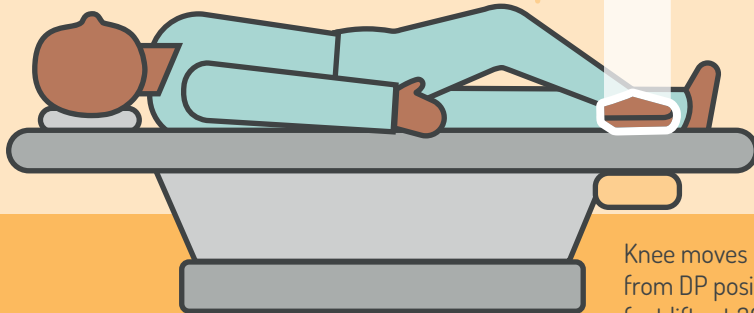
[Try a  $-15^{\circ}$  cranial angle  
to match foot arch]



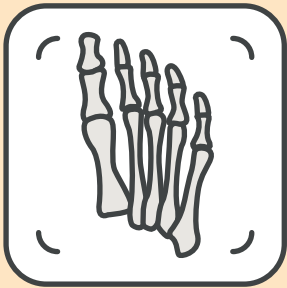

# Oblique Foot

Cuboid-navicular joint

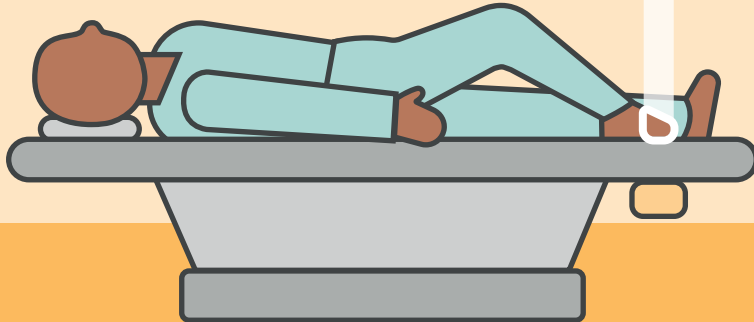


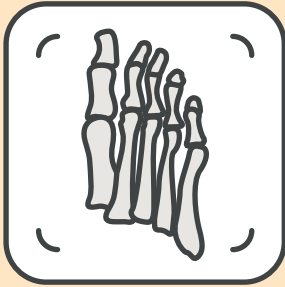Knee moves medial  
from DP position so the  
foot lifts at 30-45°



## DP Toes

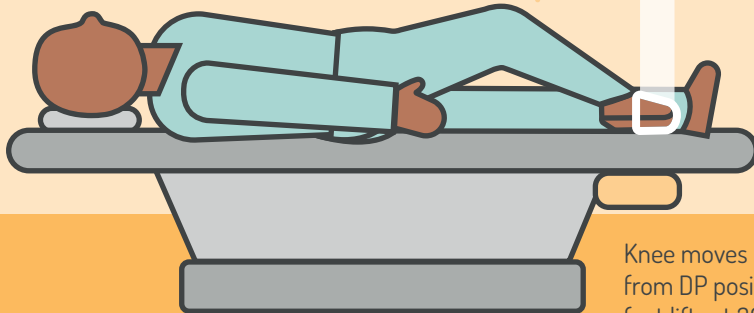
The 3rd  
metatarsophalangeal  
joint (MTPJ)





# Oblique Toes

The 1st metatarsophalangeal joint (MTPJ)



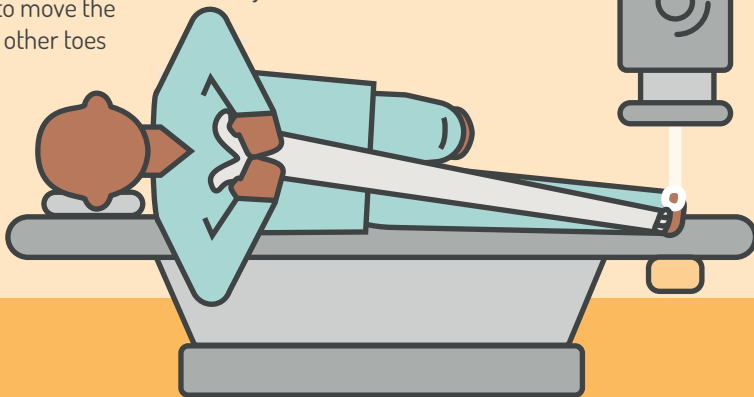
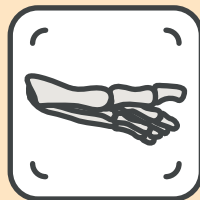Knee moves medial from DP position so the foot lifts at 30-45°



Ask the patient  
to move the  
other toes

# Lateral Hallux

The 1st  
metatarsophalangeal  
joint (MTPJ)



Ben Potts  
2022

The Society and College of Radiographers  
207 Providence Square  
Mill Street  
London SE1 2EW