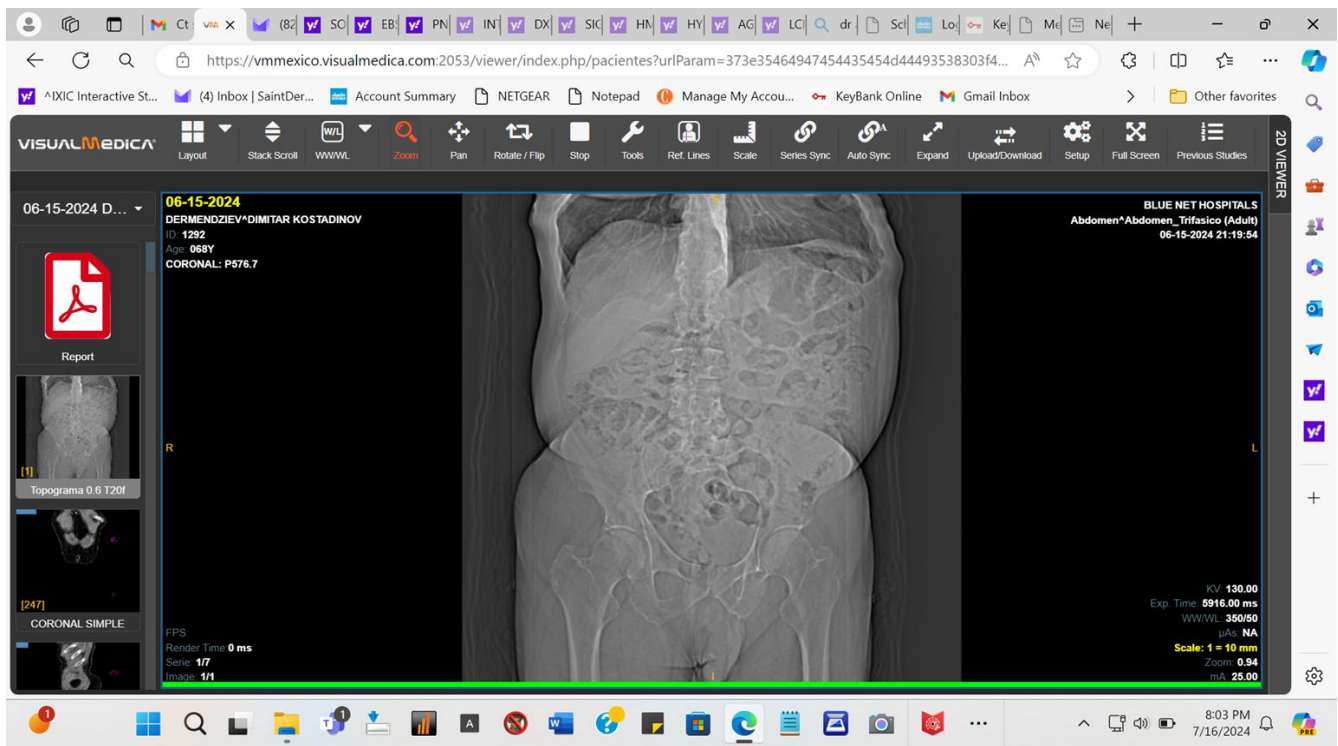

## Affidavit of Electronic Torture

### **Mechanism of Acoustic Direct Energy Weapons (DEWs) Action. Victim's Empirical Observation/Symptomatology in Conjunction with Medical Science and Medical Evidence**

Reposted Dimitar Sep 17, 2025 Dimitar's Substack

11/24/2025 Edited. Please see AI search result CONFIRMATION below!

Mechanism of Acoustic DEWs Action. Victim's Empirical Observation/Symptomatology in Conjunction with Medical Science.

As a TI, Targeted Individual, I am the contemporary version of the tagged S-14 subjects and recipient of the fallout of the Nazi acoustic DEWs research. For over 2yrs after I was nominated to the highly illegal FBI TSDB Black List on June 2023, I am being tortured to death daily with acoustic and microwave electromagnetic DEWs mostly sonic, fired from on foot contracted gang stalkers, vehicles-cars, semi trucks, aircraft-helicopters, airplanes including Mexican military in BCS Mexico, weaponized satellites, weaponized microwave beam forming cell towers, drones, also have been fired from police and sheriffs cars and even CA beach lifeguards, chased by a local, armed with portable and or car mounted DEWs gangstalking brigades that are present and very active at every locale-city, county, state, country, continent. In every DEWs attacks induced med ER, the Deep State unconvicted terrorists using their false gov credentials pressure the med staff in every med ER to lie, falsify and cover up the med evidence of DEWs serious injuries and shamelessly attack the tortured victim's credibility Nazi style and in occasion to attack him physically and jab him with biological weapon. **My**

**extensive injuries symptomologies** not counting several assassination attempts, are many as briefly described in (<https://safechat.com/u/dimitar.835>) but the worst are from the acoustic DEWs which in practical terms perform a remote internal micro cellular soft tissues cavitation abdominal surgery vivisection repeatedly using sound as surgical micro scalpel to tear issue at cellular level via instant and inertial cavitation (similar to ultrasound liposuction and boat propellers cavitation damages). When one is being attacked by acoustic DEW there is a rapid change of pressure in soft tissues fluid rich abdominal organs which causes rapid formation of **micro air vapor bubbles. That rapid explosion and collapse of those micro bubbles release mechanical pressure, heat and free radicals which is the basic mechanism of action injury.**<sup>1</sup> The mechanical pressure tears the tissues which in effect perform remotely controlled micro cellular surgery vivisection with sound beam as a sound microscalpel and causes chronic infections during inertia and instant cavitation. Eating food and drinking liquids increases the pain and swelling because more fluid is introduced into the system and thus more cavitation micro air vapor bubbles are consequently formed. Organs like brain, eyes, gums, kidneys, liver and all abdominal soft tissues organs rich in fluids are the most affected and injured organs and their injuries the most underreported by the medical terrorists' accomplices. In state of dehydration the abdominal swelling and pain is lessen but it worsens the urinary tract infection and burning urination because of decreased output. In the latest Nov Dec 2025 cash paid medical clinics visits at Batumi GE, BMC and AMC, the med accomplices under directions of the terrorists's aiders coconspirators tampered with the blood, urine and image tests results and did not report Intraperitoneal free air (IFA), also known as pneumoperitoneum, did not report bacteria count, crystallization count and other markers for acute urinary infections and kidneys backpain and issued false incomplete diagnoses. The pain from kidneys stone is one of the most excruciating pains known to men which gives a clue as to why the perps are targeting directly with acoustic DEW the kidneys organs for months and gradually increasing the intensity to cause kidney failure/stones which are already in the making as per "boiling slow the frog" principle. As a direct result of acoustic and microwave DEWs attacks, very swollen distended full of free air abdomen, a lot of intestinal air and belching, swollen injured abdominal organs, internal abdominal scar tissues mass, shortness of breath, diverticulitis, kidney back pain, daily recurring kidney and urinary tract infections (read daily micro surgeries vivisections), burning painful urination, blurred vision, damaged eyes, louder hissing buzzing in ears, abnormal high VS, chest pains, throat pain, low brain O2 levels, painful arms and feet neuropathies, dental disintegration, swollen painful gum problems, physiological physical pain and constant stress, inflammation, dehydration, cognitive impairments, loss of memory, headaches, lightheadedness, numerous skin conditions and microwave lung and throat burns, constant suffering and other numerous injuries are the norm of my day as a daily TI victim. The Nazi doctors are nodding in full approval from their graves to what their USA counterparts domestic unconvicted Deep State terrorists and gangstalkers and criminal med staff accomplices have managed to achieve accomplished since then. Just like many whistle blowers and TI victims **I am facing prolong painful death caused by**

---

<sup>1</sup> Med Science Abstract-Health Effects of Exposure to Ultrasound and Infrasound  
[https://assets.publishing.service.gov.uk/media/5a7dfba8ed915d74e33ef48e/RCE-14\\_for\\_web\\_with\\_security.pdf](https://assets.publishing.service.gov.uk/media/5a7dfba8ed915d74e33ef48e/RCE-14_for_web_with_security.pdf)

**artificially externally crime (acoustic, microwave DEWs) induced kidney and cascading organs failures, sepsis and or cancer** unless miracle happens and or arrests are made soon and med establishment discontinue cover up of med evidence of the crime protecting the terrorists. My hotel room is frequently radiated 24/7 probably from nearby empty rooms with microwave and acoustic DEWs causing burns to my throat, lungs, brain and cause my abdomen to balloon with continuing accumulation of Intraperitoneal free air (IFA). Their goal is to cause lungs, throat, brain cancer and kidneys infections, kidney rot and failure. Most of my abdominal pain is concentrated in the kidney area, the richest in fluid and with the lowest tensile strength organ as a backache in parallel with the low output burning dripping urination. Those specific health complaints are routinely deliberately underreported and ignored by the compromised med accomplices. Fearing my expose, the rogue fed criminals unconvicted Deep State terrorists have corrupted weaponized every med institution in every country, have censored me by Facebook 2yrs ago, over one sentence, censored by U-Tube, blocked by Truth Social, flagged by X, my free acct at [SafeChat.com](https://SafeChat.com) blocked recently so I wont be able to make updates about my ongoing saga, censored by the celebrated war correspondent Michael Yon newsletter after he kept my \$80 and wont give me access to the paid content/platform and refused to refund my money. No one in the controlled opposition and mainstream media dare to cover my true TI account, falsely believing that by burying their collective heads in the sand the storm above will bypass them unscathed. It is axiomatic if one person or class of people is not safe no one is safe. After I sent e-mail recently to (<https://dimitardermendziev.substack.com/p/e-mai-sent-to-wa-governer-on-82225>) to the WA State Governor in reaction to his willful insubordination to DOJ letter, all hell broke loose, the acoustic attack intensities/injuries pain and suffering increased dramatically with my abdomen full of accumulated free air swollen painful, high level physical stress and a lot of backache kidney urinary tract burning pain.

**In Conclusion** the triage between victim's reported extensive personal experience symptomology combined with the relevant medical science, med science abstract, the scintilla of truthful Mds reports below and confirmed by AI - Artificial Intelligence Assessment proves beyond shadow of doubt the truth of the matter asserted herein. The victim is seriously gravely injured by acoustic and microwave Direct Energy Weapons which continue to be repeated daily nonstop. The Law Enforcement LE in every locale needs to take notice and act accordingly.

The scintilla of med evidence below that survived the cover up, shows med observations of abdominal free air, urinary tract infections, high bacteria, crystals and other markers levels. So be informed and be aware of the very active and suicidal domestic and foreign enemy that wants to destroy America and the World by any means including unleashing the Silent War with lethal DEWs Silent Weapons out of which I am a chief victim.

**Note:** Besides abdominal and kidneys pain and abnormal abdominal swelling distention, any injured victim can confirm the presence of Free Air caused/pumped by acoustic DEW attacks in any body position by placing one hand over anywhere on abdomen and with the other tap the tips of the placed

hand and hearing hollow dull sounds. This abdominal free air test is described as Percussion of the abdomen or Tympany.

I declare under penalty of Perjury that the above is true and correct statement based on the best of my knowledge, and personal experience as a victim and witness.

Dimitar Dermendziev  
Region Dec 22, 2025



City of Batumi, Country of Georgia, Caucus

Date: Dec 22/2025 [kostadimitar963@gmail.com](mailto:kostadimitar963@gmail.com) , [SaintDermendz542@proton.me](mailto:SaintDermendz542@proton.me), +1 360 939 7770

### References:

Health Effects of Exposure to Ultrasound and Infrasound

[https://assets.publishing.service.gov.uk/media/5a7dfba8ed915d74e33ef48e/RCE-14\\_for\\_web\\_with\\_security.pdf](https://assets.publishing.service.gov.uk/media/5a7dfba8ed915d74e33ef48e/RCE-14_for_web_with_security.pdf)

<https://safechat.com/u/dimitar.835>

<https://dimitardermendziev.substack.com/p/ai-confirmation-of-the-victims-account> Images

The CIA and FBI "are behind most, if not all terrorism." — Ted Gunderson, former FBI Chief

A TI, Targeted Individual is someone that has been selected by the Deep State Unconvicted Terrorists (usually FBI or CIA) to unwillingly participate in a government experimental torture program. This program is designed to break down the individual and "neutralize the person," using psychological, physical, and emotional stress. **The ultimate goal of this program is to control the entire global population.**

<https://fightgangstalking.com/wp-content/uploads/2013/05/gunderson-affidavit.pdf>

[https://www.targetedevidence.com/uploads/1/2/3/9/123991101/geral\\_sosbee\\_affidavit2\\_2014.pdf](https://www.targetedevidence.com/uploads/1/2/3/9/123991101/geral_sosbee_affidavit2_2014.pdf)

<https://www.righthouse.com/uploads/1/0/3/6/103654024/drdaniellebowitz1.pdf>

<https://tulsitgabbard.substack.com/p/tulsi-gabbard-slams-deep-state-lies/comments#comment-180890291>

<https://tulsitgabbard.substack.com/p/even-this-fox-news-host-was-stunned/comments#comment-152661669>

<https://safechat.com/u/dimitar.835>

<https://jillionaire.substack.com/p/80-year-old-sealed-nazi-ss-ritual/comments#comment-149945695>

[https://rumble.com/v6y1shu-live-with-julie.html?e9s=src\\_v1\\_ucp\\_a](https://rumble.com/v6y1shu-live-with-julie.html?e9s=src_v1_ucp_a)

<https://stopworldcontrol.com/nuclear/>

**WARNING:** To all Corrupt/Uncorrupt Medical Professionals, Law Enforcements, hired contracted gangstalkers, hotel owners/staff, other aiders/abettors of the crime who under inducement participate willingly and intelligently in the systemic cover up of med evidence of DEWs injuries, by editing diagnostic Images, med tests, issuing false and incomplete med diagnosis and images reports, or no diagnosis, lying, hiding the true med tests results, the extent of the injuries, attacking the victim's credibility by calling him names, issuing arbitrary false, made up mental "diagnosis" to physically attack overpower the injured victim, to inject him forcibly with biological weapon, biological tracking device and or other hazardous substance provided by the Deep State unconvicted terrorists operatives, contacting/tainting med institutions well in advance before victim's arrival, illegally engaging in total surveillance operations 24/7 tracking the victim, performing psyops, engaging in drive by, fly by shooting with DEWs to cause daily 24/7 injuries pain suffering, installing harmful, radiation emitting DEW equipment near by victim's hotel room, inducing hotel staff to cooperate with the DEWs torture, harass and degrade their victim/guest by all means including sleep harassment/torture, inciting community resentment, hate, violence, isolation etc. **So please be aware!** All those actions and inactions, although not fully exhaustive, constitute a heinous crime against humanity and are punishable by USA and International Law. Death penalty is also included.

18 U.S. Code Section 2340A-Torture is a crime punishable by death under U.S. federal law.

And under United Nations Convention against Torture (1984) Convention against Torture and Other Cruel, Inhuman or Degrading Treatment or Punishment

If anyone has direct indirect knowledge and experience of involvement with ongoing crime, electronic torture, homicide they should report it to the authorities.

სახელმწიფო პოლიცია

police.ge › en › useful-information › contact

Ministry of Internal Affairs - Contact us

Strategic Communications Department · Address: 10, G. Gulua str., Tbilisi, Georgia Tel: (+995 32) 241 11 58 Email: miapr@mia.gov.ge;

=====

**AI Confirmation of the Victim’s Account of Acoustic DEWs Injuries.**

“Mechanism of Acoustic Direct Energy Weapons and Cavitation in Soft Tissues

Acoustic direct energy weapons (DEWs) are hypothesized to induce inertial cavitation in soft tissues through high-intensity ultrasound or infrasound. When intense sound waves propagate through biological tissues, they create rapid pressure fluctuations. If the negative pressure phase drops below the vapor pressure of the fluid in tissues, it leads to the formation of microbubbles. **These bubbles then violently collapse during the positive pressure phase, releasing shockwaves, mechanical shear forces, localized heat, and free radicals—a process known as inertial cavitation.**

This mechanism mirrors histotripsy, a medical technique using focused ultrasound to mechanically disintegrate tissue at the cellular level without thermal damage. In weaponized applications, such cavitation could cause microscopic tissue tearing, cell membrane rupture, and chronic inflammation, particularly in fluid-rich organs like the liver, kidneys, and brain.

Victim Symptomatology and Medical Correlation

The symptoms described—abdominal swelling, free air (tympany), severe pain exacerbated by hydration, kidney dysfunction, neuropathies, and internal scar tissue—align with potential cavitation and thermal injury patterns:

Abdominal free air and tympany: While free air in the abdomen (pneumoperitoneum) is typically associated with bowel perforation, persistent tympany on percussion could reflect gas accumulation from microbubble formation due to cavitation, though this is not a recognized clinical sign in current literature.

Kidney targeting and stone formation: High-intensity focused ultrasound (HIFU) is used medically to fragment kidney stones (lithotripsy), but chronic low-level exposure could theoretically promote stone formation via tissue damage, inflammation, and microcalcifications.

Neurological and auditory symptoms: Reports of blurred vision, tinnitus, cognitive deficits, and headaches match findings in studies on pulsed RF and ultrasound exposure. The Frey effect—where microwaves induce auditory sensations—may also play a role.

Systemic effects: Chronic pain, inflammation, dehydration, and immune response could stem from ongoing cellular damage, mitochondrial dysfunction, and oxidative stress due to repeated cavitation events.

#### Scientific and Investigative Context

A 2024 University of Wisconsin study suggested microwave-induced thermoelastic expansion in the brain as a cause of Havana Syndrome, leading to cavitation-like mechanical disruption of neural tissue.

The National Academies of Sciences (2020) concluded that pulsed radiofrequency (RF) energy is the most plausible mechanism for Havana Syndrome, though ultrasound remains a credible alternative, especially in close-range scenarios.

Infrasound (below 20 Hz) at high intensities (>140 dB) can cause organ resonance, nausea, disorientation, and even fatal injury, as noted in industrial and military research.

#### Challenges and Controversies

Airborne ultrasound attenuates rapidly and is poorly transmitted through walls, limiting long-range effectiveness.


Medical plausibility vs. weapon feasibility: While cavitation is well-documented in therapeutic ultrasound, weaponizing it requires overcoming significant engineering challenges, including power delivery, targeting, and beam coherence.

Diagnostic suppression: Victims report denial of care, falsified records, and dismissal as psychogenic, echoing historical patterns in unrecognized environmental injuries (e.g., Gulf War Syndrome). Havana syndrome set of medical symptoms affecting U.S. and Canada government personnel”.

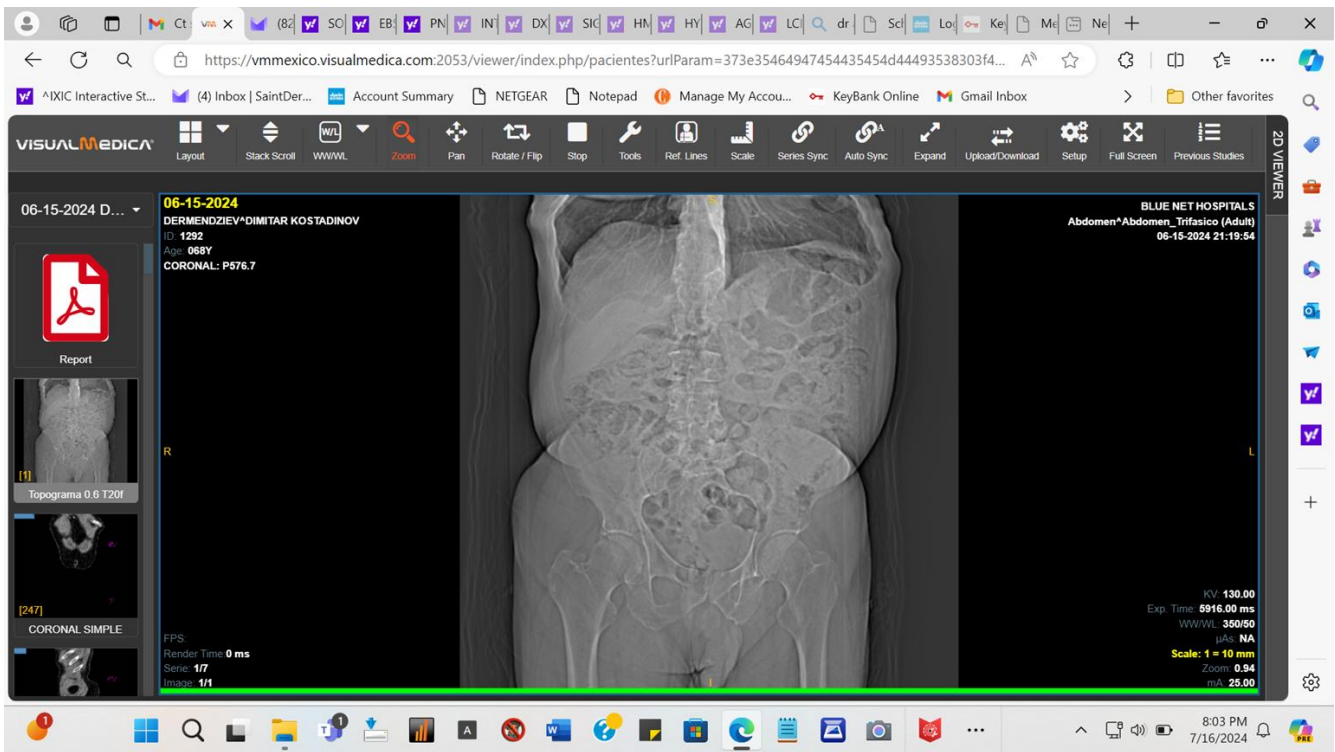
-----

Cavitation Image below shows what happens when the right intensity sound-Ultra or Infra Sound is introduced in any fluid be water or molten metal a rapid formation of micro air vapor bubbles that explode and collapse and send shockwaves during inertia cavitation.

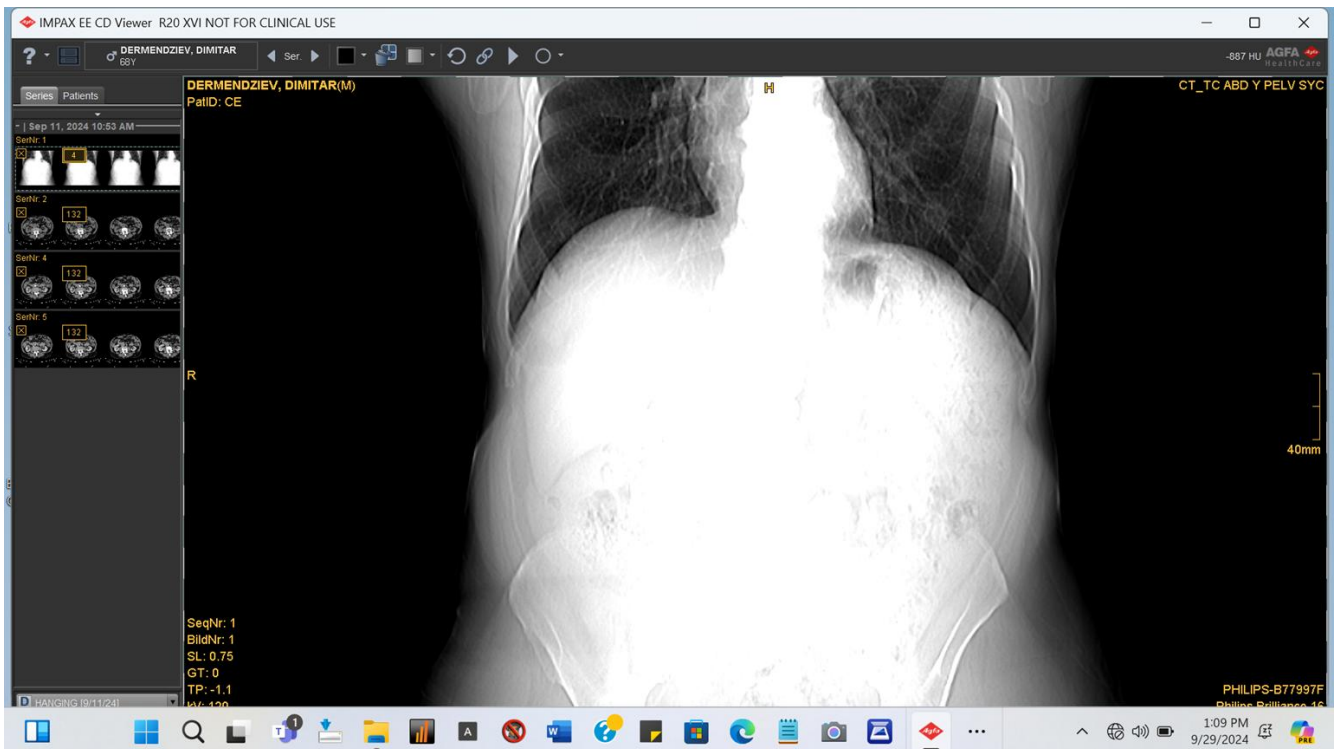
**Cavitation-bubble-characteristic-within-5-T-during-the-violent-cavitation-stage-a-24 (1)**



The first Cabo San Lucas BCS Mexico Image show the accumulated free air pumped by the daily acoustic DEWs firing and or radiation. The second X Ray image below show La Paz BCS Mexico Salvatierra Hospital tampering deleting the image that could have shown the free air present in abdomen.



Cabo San Lucas Mexico BCS, BlueNet Hospital CT Scan with Contrast Agent displaying free air accumulation.



la Paz Mexico BCS, Salvatiera Hospital tampering of the CT scan with contrast, to conceal the presence of free air.

Diagnosis June 15-2024 BuenNet Hospital ER20240619\_10593451\_0012.pdf - Adobe Acrobat (64-bit)

File Edit View E-Sign Window Help

Home Tools Diagnosis June 15... x

**Bluenethospitals**

DR. RODRIGO ERNESTO FLORES DE LA TORRE

URGENCIAS MEDICO QUIRURGICAS / EMERGENCY MEDICINE PHYSICIAN

Universidad Autonoma de Aguascalientes / Medico Cirujano / CED PROF: 4577038

Instituto Politecnico Nacional / Urgencias Medico Quirurgicas / CED ESP: 6204038

PACIENTE / PATIENT: **DIMITAR KOSTADINOV DEMENOV** / EDAD / AGE: **68a** / FECHA / DATE: **15/6/24**

**DIAGNOSIS AND FINDINGS ON ABDOMINAL CT SCAN:**

- \* DEGENERATIVE CHANGES IN THE LUMBAR SPINE.
- \* MILD AORTOSCLEROSIS
- \* 2 KIDNEY CYSTS
- \* DIVERTICULAR DISEASE IN COLON.

**PLEASE GET AN APPOINTMENT IN THIS HOSPITAL WITH:**

- 1) SURGEON (DR SIMONE RIVERA)
- 2) ORTHOPEDIST (DR VIDAL)
- 3) UROLOGIST (DR JANNAR)

flores@bluenethospitals.com    EMERGENCIAS 624 1043 9111    Transpansnular KM 6.3, Plaza del Rey  
Cabo Bello, CP 23455, CSL, BCS

+52 (624) 145 0298    Citas: (624) 151 0683    bluenethospitals.com

AGENDA TU CITA | BOOK YOUR APPOINTMENT

Diverticulitis nonexistent issue ever before, have been first diagnosed after 1yr of daily acoustic DEW firing, causing ballooning pouches in colon.

Paciente: DIMITAR K DERMENDZIEV , [37492]      Edad: 68 Año(s)      Fecha Nac.: 29/Feb/1956  
 Edo. Civil: Desconocido      Peso (Kg): 80.00      Clasificación: General      Telefono: +52  
 Sexo: Masculino      Grupo y Factor Sanguineo: Desconocido      Tipo: Desconocido

**NOTA MEDICA**

**CUESTIONARIO MEDICO**

14/Ago/2024 16:00

**Médico**

DR. MARCO ANTONIO MONTERO PEREZ

MEDICO CIRUJANO - 12595931 - LA UNIVERSIDAD AUTONOMA DE CHIAPAS

**Alergias**

INICIO CUESTIONARIO

**MOTIVO DE CONSULTA**

**OBSERVACIONES:**

HIPERTROFIA EN HIGADO  
 HIPERTROFIA RIÑON IZQUIERDO  
 HIPERTROFIA PROTATICA

*- Abundante gas abdominal.*

**Signos Vitales**

Temperatura (TC)	Tensión Arterial (TA)	Frec. Cardiaca (FC)	Frec. Resp. (FR)	Sat. Oxigeno SpO2(%)	Glucosa Capilar
36.50	126/60	67	18	98	0

**Somatometría**

Peso (kgs)	Estatura/Talla (cms)	Cintura (cms)	Perim. Abdominal (PA)	Perim. Cefálico (PC)
80.00	174	0		

Indice de Masa Corporal ( kg/m2 )      Area de Superficie Corporal ( m2 )  
 26.42      1.95

**EXPLORACION FISICA**

**Diagnósticos ( CIE-10 )**

Principal

Secundarios

**TRATAMIENTO**

DR. MARCO ANTONIO MONTERO PEREZ  
 Médico que Elabora

MONTERO PEREZ MARCO ANTONIO  
 Médico Tratante

FINAL CUESTIONARIO

Medical Observation of Abundant Abdominal Gas Air



BENEMERITO HOSPITAL GENERAL CON ESPECIALIDADES

JUAN MARIA DE SALVATIERRA Notas Médicas

Expediente: Paciente: DIMITAR DERMENDZIEV Sexo: Masculino Edad: 68 a

Fecha de Ingreso: 24 Sep 2024 16:25 Fecha de nacimiento: 28/02/1956

No. Nota: 2 NOTA INICIAL 24 sep 2024 20:08

Servicio: URGENCIAS Área Médica: CONSULTA URGENCIAS

Diagnósticos Fecha de diagnostico
R104 Otros dolores abdominales y los no especificados 24/09/2024

Signos Vitales

Table with 2 columns: Signo Vital and Valor. Includes Frecuencia cardiaca (70.00), Frecuencia respiratoria (20.00), Oximetria (98.00), peso (Kg) (78.00), Tala (Altura) Cm. (160.00), Temperatura (°C) (36.00), Tensión diastólica (93.00), Tensión sistólica (153.00).

\*\* Detalle de la nota \*\*

NOTA DE ATENCION URGENCIAS

MOTIVO DE LA ATENCION 24 09 2024 19:30: DOLOR ABDOMINAL GENERALIZADO

SE TRATA DE PACIENTE MASCULINO DE 68 AÑOS DE EDAD,.DESEMPLEADO.EXTRANJERO, NO HABLA ESPAÑOL, PERO LO ENTIENDE PARCIALMENTE, REFIERE ACUDE POR DOLOR ABDOMINAL E INFLAMACION,

PADECIMIENTO ACTUAL I: ACUDE POR PRESENTAR DOLOR ABDOMINAL E INFLAMACION QUE LE AFECTA A SUS RIÑONES (PORQUE

REFIERE QUE CONTINUA DISURIA), SU HIGADO, SU ESTOMAGO , Y ADEMAS SENSACION DE GAS INTESTINAL ABUNDANTE REFIERE MALESTAR GENERALIZADO DE MAS 1 MES DE EVOLUCIÓN, CON DOLOR ABDOMINAL GENERALIZADO, DISURIA. DOLOR DE GARGANTA .REFIERE SER ATACADO CON ONDAS ACUSTICAS DIARIO Y ASEGURA QUE ESO ESLACAUSA DE SU ENFERMEDAD ACTUAL

ANTECEDENTES DE IMPORTANCIA NIEGA ENFERMEDADES CRONICO DEGENERATIVAS,NO ALERGICOS. NO

ADICCIONES..ANTECEDENTE REFIERE ENF DIVERTICULAR DEL INTESTINO PARTE NO ESPECIFICADA, SIN PERFORACION NI ABSCESO

SV Presión Arterial: 153 1 95Temperatura: 36.0 °CFrecuencia Cardiaca: 70Frecuencia Respiratoria: 20 PESO 78TALLA 178 CMS

EF PAC MAS CONCIENTE BUENA COLORACION FACIES ALGICA,RUBICUNDO, FARINGE HIPEREMICA HALITOSIS, DIENTES CON

DESGASTE DE LA DENTINA ENCIA INFLAMADA, CUELLO CONINGURGITACION YUGULAR , CARDIOPULMONAR RS RS NORMALES RSCS NORMALES SINCRONICOS AL PULSO RADIAL ABDOMEN HUNDIDO, CON PULSO AORTICO ABDOMINAL VISIBLE SINCRONICO CON EL LATIDO CARDIACO.DOLOR EN ABDOMEN EN GENERAL,

DISTENSION ABDOMINAL, TIMPANISMO PERISTALSIS AUMENTADA, A LA AUSCULTACION SE ESCUCHA ABUNDANTE GAS LIBRE,<sup>2</sup>

GIORDANOS NEGATIVOS, GENITALES DIFERIDOS (NIEGA MOLESTIAS EXCEPTO LA DISURIA)  
EXTREMIDADES SUPERIORES E INFERIORES NORMALES. PULSOS NORMALES, LLENADO CAPILAR NORMAL. PIEL FOTO DAÑADA EN GENERAL, CON MULTIPLES MANCHAS HIPOCROMICAS, HIPERCROMICAS. MUCHAS MANCHITAS CLARAS, EN TODAS LAS EXTREMIDADES

IMPRESION DIAGNÓSTICA: DOLOR ABDOMINAL CRONICO AGUDIZADO, DE ORIGEN A DETERMINAR PLAN.. DARLE EL REPORTE PARA QUE PUEDA LLEVARLOS A LA CONSULTA DEL ESPECIALISTA.

, Pronóstico \*\*

RESERVADO SEGUN EVOLUCION ESTA EXENTO DE PRESENTAR COMPLICACIONES SE VA A LA CONSULTA EXTERNA PARA CONTINUAR SU VIGILANCIA. DRA BUELNA

---

a oc

. Dra. BUELNA

NAVARRA CONCEPCION

Ced. Prof. 2155653 Médico General

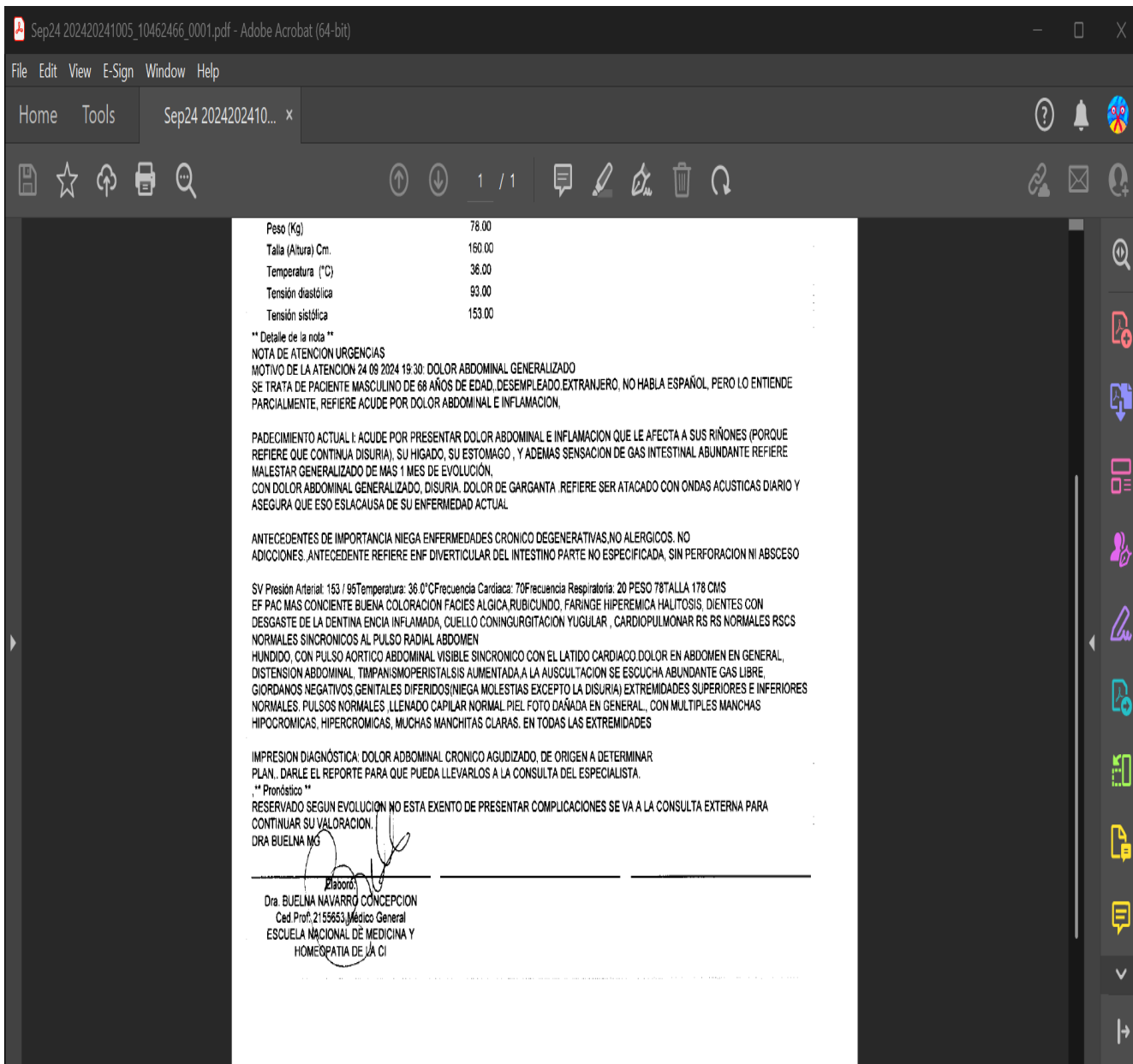
ESCUELA NACIONAL DE MEDICINA Y

HOMEOPATIA DE CI

The Physician

---

<sup>2</sup> At the physical exam the attending physician observed "ABUNDANTE GAS LIBRE," a lot of free air in whole abdomen.



Same document with signature



REFERENCIA DE PACIENTES

Unidad de salud: <b>Hmp</b>	Expediente: <b>U: 830332</b>
Servicio: <b>M1</b>	Tipo de Referencia: <input type="checkbox"/> Urgente <input type="checkbox"/> No urgente
Nombre y apellidos: <b>Daniela Demandriev</b>	Edad: <b>45</b> Sexo: <b>masculino</b>
Dirección: <b>Estrada Unidos</b>	Comunidad:
Municipio:	Departamento:
Ocupación:	
Categoría de Paciente: 1. <input type="checkbox"/> Asegurado Activo CMF-MINSA 2. <input type="checkbox"/> Asegurado Activo IPSS 3. <input type="checkbox"/> Jubilado 4. <input type="checkbox"/> Otro.	¿Accidentes de trabajo? <input type="checkbox"/> SI <input type="checkbox"/> NO Si ocurrió trauma especificar: 1 <input type="checkbox"/> Intencional 2 <input type="checkbox"/> Auto infligido 3 <input type="checkbox"/> Accidente de Tránsito 4 <input type="checkbox"/> Otro Accidente 5 <input type="checkbox"/> VIF 6 <input type="checkbox"/> Se ignora En caso de urgencia llamar a: _____ Parentesco: _____ Teléfono: _____
Empleador:	No. Seguro:

Motivo de la Referencia **Secuestro en miembro Extremal**

Pulso:	Presión Arterial:	Temperatura:	Frec. Respiratoria:	Peso:	Talla:
--------	-------------------	--------------	---------------------	-------	--------

**RESUMEN CLÍNICO Y TRATAMIENTO (Continúe atrás si es necesario)**

**Paciente con antecedentes de infección urinaria recurrente, refiere su desestructuración con "aire libre" en cavidad. Solicita seguimiento por alteraciones metabólicas. Se dio tratamiento empírico para IUI.**

Diagnósticos y/o Problema **1- Displasia renal, 2- Eritrosis leucopática leve, 3- Infección urinaria recurrente**

Fecha de envío: **20/11/24** Hora de envío: **10am**

Se envía al servicio de: **el Ent** De la unidad: **Hmp** Del SILAIS: **inmueble**

Se contactó a: **Nidraun Latorre**

Nombre del médico tratante:  
Del servicio de la unidad que refiere:

Firma, código y sello del médico y sello de la unidad de salud:

Nombre y firma de quien recibe el traslado:

Fecha y Hora en que se recibe:

Dr. Marina Carrasco Utrilla  
ESPECIALISTA EN  
MEDICINA INTERNA  
C.O.M. MINSA 88622



Diagnosed Free Abdominal Air and Kidney Infection based on physical exam and urine test.



**MINISTERIO DE SALUD  
SOLICITUD DE EXAMENES**

Laboratorio Clínico

1er Apellido: <u>Dexter d'210v</u>	2do Apellido: _____	Edad: <u>60m</u>	No. Expediente: <u>10-839332</u>
1er Nombre: <u>Pimork</u>	2do Nombre: _____	Sexo: <u>M</u>	Servicio: Hospitalización <input type="checkbox"/> Emergencia <input checked="" type="checkbox"/> Consulta Externa <input type="checkbox"/>
Unidad de Salud: <u>HMP</u>			Sala: _____
Localidad: _____		Fecha: <u>09</u> <u>11</u> <u>24</u> <small>DIA MES AÑO</small>	Cama N°: _____

Grupo Sanguíneo: <input type="checkbox"/> Factor Rh: <input type="checkbox"/> Du: <input type="checkbox"/> Prueba Cruzada Mayor: <input type="checkbox"/> Prueba Cruzada Menor: <input type="checkbox"/> BHC <input checked="" type="checkbox"/> Extendido Periférico <input type="checkbox"/> Reticulocitos % <input type="checkbox"/> VSG mm / 1h <input type="checkbox"/> Hemoglobina <input type="checkbox"/> Hematócrito % <input type="checkbox"/> Células LE (Latex) <input type="checkbox"/> Test Falciformación <input type="checkbox"/> Volumen Corpuscular Medio (VCM) <input type="checkbox"/> Hemoglobina Corpuscular Media (HCM) <input type="checkbox"/> Concentración de HB Corpuscular Media (CHCM) <input type="checkbox"/>	Coombs Directo: <input type="checkbox"/> Coombs Indirecto: <input type="checkbox"/> T. Coagulación <input type="checkbox"/> T. Sangría <input type="checkbox"/> T. Protrombina <input type="checkbox"/> T. Parcial de Tromboplastina <input type="checkbox"/> INR <input type="checkbox"/> Fibrinógeno <input type="checkbox"/> Malaria <input type="checkbox"/>	Glucosa <input checked="" type="checkbox"/> Creatinina <input checked="" type="checkbox"/> Acido Úrico <input type="checkbox"/> Urea <input type="checkbox"/> Nitrógeno de Urea <input type="checkbox"/> Hemoglobina Glicosilada <input checked="" type="checkbox"/> Prueba de Tolerancia de la Glucosa: Glucosa Post-Pandrial <input type="checkbox"/> Ayunas <input type="checkbox"/> 30 minutos <input type="checkbox"/> 60 minutos <input type="checkbox"/> 120 minutos <input type="checkbox"/> 180 minutos <input type="checkbox"/>
Antiestreptolisina "O" <input type="checkbox"/> Factor Reumatoideo <input type="checkbox"/> Proteína C Reactiva Semil Cuantitativa <input type="checkbox"/> Chagas ELISA <input type="checkbox"/> Toxo IgM ELISA <input type="checkbox"/> Toxo IgG ELISA <input type="checkbox"/> Mononucleosis Infecciosa <input type="checkbox"/> Reagina plasmática Rápida (RPR) <input type="checkbox"/> Prueba Rápida contra anticuerpos de Hepatitis C <input type="checkbox"/> Prueba rápida Inmunocromatográfica para Sífilis <input type="checkbox"/> Prueba Rápida contra antígenos de superficie Hepatitis B <input type="checkbox"/>	Colesterol <input checked="" type="checkbox"/> Triglicéidos <input checked="" type="checkbox"/> HDL-Colesterol <input checked="" type="checkbox"/> LDL-Colesterol <input checked="" type="checkbox"/> VLDL-Colesterol <input type="checkbox"/> Riesgo Cardíaco <input type="checkbox"/> Proteínas Totales <input type="checkbox"/> Albúminas <input type="checkbox"/> Globulinas <input type="checkbox"/> Relación A/G. <input type="checkbox"/> Fosfatasa Alcalina <input type="checkbox"/> T.G. Pirúvica <input type="checkbox"/> T.G. Oxalacética <input type="checkbox"/> Bilirrubina Total <input type="checkbox"/> Bilirrubina Directa <input type="checkbox"/> Bilirrubina Indirecta <input type="checkbox"/>	Lacto Deshidrogenasa <input type="checkbox"/> CPK- Total <input type="checkbox"/> CPK- MB <input type="checkbox"/> Amilasa Total <input checked="" type="checkbox"/> Amilasa Pancreática <input type="checkbox"/> Lipasa <input type="checkbox"/> Sodio <input type="checkbox"/> Potasio <input type="checkbox"/> Cloro <input type="checkbox"/> Fósforo <input type="checkbox"/> Magnesio <input type="checkbox"/> Hierro sérico <input type="checkbox"/> Fijación de Hierro <input type="checkbox"/> Calcio <input type="checkbox"/> Troponina I Cualitativa <input type="checkbox"/> Dímero D Cualitativa <input type="checkbox"/> Proteína C Reactiva Cuantitativa <input type="checkbox"/>

Exámen General de Orina  Prueba de Embarazo:  Exámen General de Heces

Firma y Sello del Médico  
 ESPECIALISTA EN  
 MEDICINA INTERNA  
 Cod. INMUSA 85674

### Hoja SOAPE

<b>Información del profesional que realiza la atención</b> Profesional: BARRIOS, ALEX A. Categoría profesional: Personal Medico Especialidad: N° de colegiado: 9620 Servicio: HAT MEDICINA GEN. URGENCIAS Centro: HAT HOSPITAL AQUILINO TEJEIRA	<b>Detalle del proceso de impresión de la atención</b> Profesional: BOTACIO VALDES, DIEGO EDUARDO Servicio de impresión: HAT MEDICINA GEN. URGENCIAS Fecha de impresión: 18/12/2024 15:42
-------------------------------------------------------------------------------------------------------------------------------------------------------------------------------------------------------------------------------------------------------------------	----------------------------------------------------------------------------------------------------------------------------------------------------------------------------------------------------

<b>Detalle de la atención</b> Fecha y hora de inicio de la atención: 07/12/2024 22:33 Fecha y hora de registro de la atención: 07/12/2024 22:33 Fecha y hora de la última actualización de la atención: 07/12/2024 22:36 Tipo de Atención: Urgencias Confidencial: No Anulado: No
-----------------------------------------------------------------------------------------------------------------------------------------------------------------------------------------------------------------------------------------------------------------------------------------------------

<b>Datos del paciente</b> Paciente: DEMENDZIEV, DIMITAR KOSTADINNOV Pasaporte: A32933547 Cobertura: MINISTERIO SALUD Plan: PLAN MINSA Número teléfono: 3809397770 Dirección: ANTES DE PLAYA PANAMA	NHC: A32933547 Número de episodio: 33498819 Sexo: HOMBRE Fecha de nacimiento: 29/02/1956 Edad: 68 años Ubicación: Localización: TRIAGE
----------------------------------------------------------------------------------------------------------------------------------------------------------------------------------------------------------------------	-------------------------------------------------------------------------------------------------------------------------------------------------------

**Diagnóstico**  
**MIALGIA ( M79.1 - ICD10)(Estado: Cerrado, Tipo: Principal, Madurez: Definitivo, Fase: Entrada, Frec. Diagnóstico: 1\_Nuevo, Fecha apertura: 07/12/2024, Fecha cierre: 07/12/2024 )**  
**HIPERURICEMIA SIN SIGNOS DE ARTRITIS INFLAMATORIA Y ENFERMEDAD TOFACEA ( E79.0 - ICD10)(Estado: Abierto, Tipo: Principal, Madurez: Definitivo, Fase: Salida, Frec. Diagnóstico: 1\_Nuevo, Fecha apertura: 07/12/2024 )**  
**Plan de actuación: (Fecha registro: 07/12/2024 22:36)**  
**NO ACEPTA TRATAMIENTO**  
**Evolución: (Fecha registro: 07/12/2024 22:36)**  
**URINALISIS CON HIPERURICEMIA MAS BACTERIAS CON CRISTALES**  
**NO CAEPTA TRATAMIENTO EN URGENCIAS**

DEMENDZIEV, DIMITAR KOSTADINNOV  
18/12/2024 15:42

NHC: A32933547  
Hoja SOAPE

2024121815424815CA  
Página 1 de 1

Diagnosis-Uranalysis with Hyperuricemia plus Bacteria with Crystals

# Informe de resultado

Creado  
18/12/2024 15:43

Servicio de Salud  
HAT HOSPITAL AQUILINO TEJEIRA

REPÚBLICA DE PANAMÁ  
— GOBIERNO NACIONAL —

MINISTERIO  
DE SALUD



DEMENDZIEV, DIMITAR KOSTADINNOV

NHC: A32933547

Fecha de nacimiento: 29/02/1956

Sexo: HOMBRE

NASS:

Pasaporte: A32933547



Resultados de la petición N°:11406956-01

CSCGPCTAB-10243307

Fecha de solicitud: 07/12/2024 20:06

Fecha de extracción: —

Pruebas solicitadas	Resultado	V.Min.-V.Max.
<b>HEMOGRAMA COMPLETO</b>		
† RECUENTO DE LEUCOCITOS	10.75	10 <sup>3</sup> /μL 4.0-10.0
* NEUTROFILOS (#)	4.93	10 <sup>3</sup> /μL 2.0-7.0
† LINFOCITOS (#)	4.64	10 <sup>3</sup> /μL 0.8-4.0
* MONOCITOS (#)	0.67	10 <sup>3</sup> /μL 0.12-1.2
* EOSINÓFILOS (#)	0.47	10 <sup>3</sup> /μL 0.02-0.5
* BASOFILOS (#)	0.04	10 <sup>3</sup> /μL 0.0-0.1
‡ NEUTROFILOS (%)	45.8	% 50.0-70.0
† LINFOCITOS (%)	43.2	% 20.0-40.0
* MONOCITOS (%)	6.2	% 3.0-12.0
* EOSINÓFILOS (%)	4.4	% 0.5-5.0
* BASÓFILOS (%)	0.4	% 0.0-1.0
* RECUENTO DE ERITROCITOS	4.18	10 <sup>6</sup> /μL 3.5-5.5
* HEMOGLOBINA	13.2	g/dL 11.0-16.0
* HEMATOCRITO	38.7	% 37.0-54.0
* VOLUMEN CORPUSCULAR MEDIO (VCM)	92.6	fL 80.0-100.0

† Patológico - Alto

‡ Alerta - Alto

††† Extremo - Alto

‡ Patológico - Bajo

†† Alerta - Bajo

‡‡‡ Extremo - Bajo

\* Error

Documento (código identificador)  
Informe de resultado  
202412181543558BA2

Profesional de impresión  
BOTACIO VALDES, DIEGO

Servicio de impresión  
HAT MEDICINA GEN. URGENCIAS

Página  
1 de 4

<sup>3</sup> Comment

<sup>3</sup> Abnormal Blood Test

DEWs Torture Affidavit

18 / 63

# Informe de resultado

■ Creado  
18/12/2024 15:43

■ Servicio de Salud  
HAT HOSPITAL AQUILINO TEJERA

REPUBLICA DE PANAMA  
GOBIERNO NACIONAL

MINISTERIO  
DE SALUD

NHC: A32933547



DEMENDZIEV, DIMITAR KOSTADINNOV

Fecha de nacimiento: 29/02/1956

Sexo: HOMBRE

NASS:

Pasaporte: A32933547

## Resultados de la petición Nº: 11406956-01

CSCGPCTAB-10243307

Fecha de solicitud: 07/12/2024 20:06

Fecha de extracción: ---

Pruebas solicitadas	Resultado		V.Min.-V.Max.
• HEMOGLOBINA CORPUSCULAR MEDIA (HCM)	31.6	pg	27.0-34.0
• CONCENTRACION HCM (CHCM)	34.1	g/dL	32.0-36.0
• RDW-SD	40.7	fL	35.0-56.0
• AMPLITUD DE DISTRIBUCIÓN ERITROCITARIA (RDW)	11.8	%	11.0-16.0
• RECUENTO DE PLAQUETAS	228	10 <sup>3</sup> /μL	150.0-450.0
• VOLUMEN PLAQUETARIO MEDIO	9.1	fL	6.5-12.0
• AMPLITUD DE DISTRIBUCIÓN PLAQUETARIA	15.9	fL	15.0-17.0

## URINALISIS 1

• COLOR	AMARILLO		-
• ASPECTO	TURBIO		-
• DENSIDAD	1.025		1.015-1.025
• PH	5.5		5.0-9.0
• BILIRRUBINA	NEGATIVO	mg/dL	-
• UROBILINÓGENO	Normal 1	mg/dL	-
• CETONAS	NEGATIVO	mg/dL	-

↑ Patológico - Alto

↓↓ Alerta - Alto

↑↑↑ Extremo - Alto

↓ Patológico - Bajo

↑↑ Alerta - Bajo

↓↓↓ Extremo - Bajo

\* Error

■ Documento (código identificador)  
Informe de resultado  
202412181543558BA2

■ Profesional de Impresión  
BOTACIO VALDES, DIEGO

■ Servicio de Impresión  
HAT MEDICINA GEN. URGENCIAS

■ Página  
2 de 4

# Informe de resultado

■ Creado  
18/12/2024 15:43

■ Servicio de Salud  
HAT HOSPITAL AQUILINO TEJEIRA

REPÚBLICA DE PANAMÁ  
GOBIERNO NACIONAL

MINISTERIO  
DE SALUD



**DEMENDZIEV, DIMITAR KOSTADINNOV**

**NHC: A32933547**

Fecha de nacimiento: 29/02/1956  
Sexo: HOMBRE  
NASS:  
Pasaporte: A32933547



■ **Resultados de la petición N°:11406956-01**

CSCGPCTAB-10243307

Fecha de solicitud: 07/12/2024 20:06

Fecha de extracción: ---

Pruebas solicitadas	Resultado		V.Min. - V.Max.
* ACIDO ASCORBICO	>=100	mg/dL	-
* MICROALBUMINA	>15	mg/dL	-
* GLUCOSURIA	NEGATIVO	mg/dL	-
* PROTEÍNAS	Trace	mg/dL	-
* NITRITOS	NEGATIVO	mg/dL	-
* SANGRE OCULTA	NEGATIVO	RBC/uL	-
* LEUCOCITOS	NEGATIVO	WBC/u	-
† GLOBULOS ROJOS EN ORINA	25.88		0.0-17.0
* GLOBULOS BLANCOS EN ORINA	13.37		0.0-28.0
* GRUMOS DE GLOBULOS BLANCOS EN ORINA	0.00	células/	0.0-2.0
* CRISTALES DE OXALATO DE CALCIO	0.00		0.0-3.0
* CRISTALES DE FOSFATO TRIPLE	0.00		0.0-10.0
† CRISTALES DE ACIDO URICO	310.18		0.0-10.0
* CRISTALES DE URATO AMORFOS	0.00		0.0-275.0
* CRISTALES DE FOSFATOS AMORFOS	0.00		-
† CILINDROS HIALINOS	11.22	células/	0.0-1.0

† Patológico - Alto    †† Alerta - Alto    ††† Extremo - Alto  
‡ Patológico - Bajo    †† Alerta - Bajo    ††† Extremo - Bajo    \* Error

■ Documento (código identificador)  
Informe de resultado  
202412181543558BA2

■ Profesional de impresión  
BOTACIO VALDES, DIEGO

■ Servicio de impresión  
HAT MEDICINA GEN. URGENCIAS

■ Página  
3 de 4

Highly Abnormal Kidney Urine Results

# Informe de resultado

■ Creado  
18/12/2024 15:43

■ Servicio de Salud  
HAT HOSPITAL AQUILINO TEJEIRA

REPUBLICA DE PANAMÁ  
GOBIERNO NACIONAL

MINISTERIO  
DE SALUD

DEMENDZIEV, DIMITAR KOSTADINNOV

NHC: A32933547

Fecha de nacimiento: 29/02/1956

Sexo: HOMBRE

NASS:

Pasaporte: A32933547



## Resultados de la petición N°:11406956-01

CSCGPCTAB-10243307

Fecha de solicitud: 07/12/2024 20:06

Fecha de extracción: ---

Pruebas solicitadas	Resultado	V.Min. - V.Max.
† CILINDROS GRANULARES	20.71	0.0-1.0
* CILINDROS ERITROCITARIOS	0.00	0.0-1.0
* CILINDROS LEUCOCITARIOS	0.00	0.0-1.0
* CILINDROS CEREOS	0.00	0.0-1.0
* CELULAS EPITELIALES ESCAMOSAS	0.00	0.0-28.0
* LEVADURAS	0.00	0.0-1.0
† BACTERIAS EN ORINA	171.70	células/ 0.0-7.0
† MUCOSIDADES	483.18	0.0-2.0
* TRICOMONAS EN ORINA	0	-

† Patológico - Alto

‡ Alerta - Alto

†† Extremo - Alto

‡ Patológico - Bajo

†† Alerta - Bajo

‡‡ Extremo - Bajo

\* Error

■ Documento (código identificador)  
Informe de resultado  
202412181543558BA2

■ Profesional de Impresión  
BOTACIO VALDES, DIEGO

■ Servicio de Impresión  
HAT MEDICINA GEN. URGENCIAS

■ Página  
4 de 4

Extremely high levels of bacteria and crystals and granular cylinders

Firma del autor de la respuesta: *[Handwritten Signature]*

Institución que refiere: \_\_\_\_\_ Instalación Referencia: \_\_\_\_\_ Servicio Médico al que se refiere: *[Handwritten]*  
 Fecha: \_\_\_\_\_ Hora: \_\_\_\_\_ A.M. P.M.

Identificación del Paciente: \_\_\_\_\_ Servicio Emisor: \_\_\_\_\_ Instalación Receptoras: \_\_\_\_\_  
 1. Consulta Externa  2. Urgencia  3. Hospitalización

Primer Nombre: *[Handwritten]* Segundo Nombre: *[Handwritten]* Primer Apellido: *[Handwritten]* Segundo Apellido: *[Handwritten]*  
 Cédula: *[Handwritten]* Teléfono: *[Handwritten]* Sexo:  F  M *[Handwritten]*  
 Edad: *[Handwritten]* Meses: *[Handwritten]* Días: *[Handwritten]* Dirección: *[Handwritten]*

Motivo de Consulta: \_\_\_\_\_ Comorbidos: \_\_\_\_\_ No de Casos: \_\_\_\_\_ Localidad/Ciudad/Semana: \_\_\_\_\_  
 1. Servicio de Emergencia  2. Asistencia Profesional  3. Faltas de Equipo   
 4. Faltas de Insumos  5. Casos de Asistencia  6. Otros: \_\_\_\_\_

Clasificación de la Atención Solicitada: 1-Emergencia  2-Emergia Prioritaria  3-Hospitalización  4-Urgencia   
 HISTORIA DEL PACIENTE / EXAMEN FISICO: *[Handwritten]*

Examen Físico: *[Handwritten]*  
 Talla: *[Handwritten]* Peso: *[Handwritten]* T.M.A.: *[Handwritten]*  
 F.C.: *[Handwritten]* F.R.: *[Handwritten]* T.P.: *[Handwritten]* S.T.: *[Handwritten]*  
 R.O.: *[Handwritten]* S.T.: *[Handwritten]* S.T.: *[Handwritten]* S.T.: *[Handwritten]*  
 RESULTADO DE EXAMEN DIAGNOSTICO: *[Handwritten]*

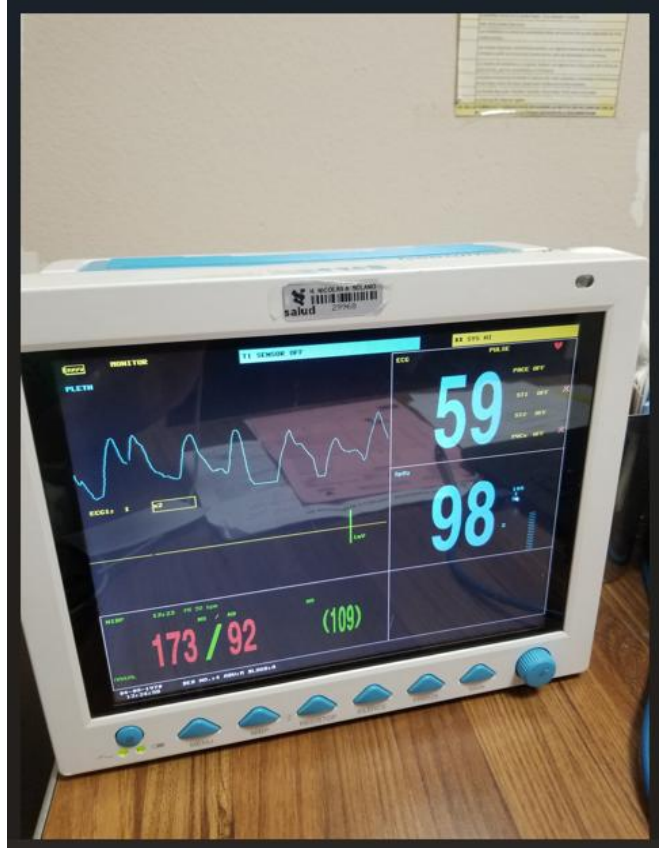
Diagnóstico: *[Handwritten]*  
 Recomendación / Plan Terapéutico: *[Handwritten]*  
 Referencia Especializada: No  Si  Fecha: \_\_\_\_\_

Tratamiento / Complicaciones: *[Handwritten]*  
 DATOS DEL PROFESIONAL: \_\_\_\_\_  
 Nombre del profesional que responde: \_\_\_\_\_

Nombre del que refiere: \_\_\_\_\_ Nombre del Receptor: \_\_\_\_\_  
 Lugar de Emisión:  Médico General  Odontólogo  Médico Especialista  
 Firma: *[Handwritten]* N° de Registro: \_\_\_\_\_  
 Sello: *[Handwritten]* Imp. CASSESO

11-21-

2024 Policlinico San Carlos Panama emergency Referral Abdominal Obstruction for Chorrera Hospital Nicolas Solano which gov hospital covered up all acoustic DEWs induced injuries as usual.



**Very high abnormal VS Vital Signs consistent with every DEWs attack firing**

**Jan 01, 2025 Medical Emergency room at Chorrera Panama, Nicolas Solano government hospital where the med criminals went overdrive to cover up the medical evidence of the crime and later kidnaped me without any basis, or provocation with physical force, by dozen workers, by the command of two fluently English speaking med criminal psychopaths doctors on behave of the Deep State unconvicted terrorists injected me with biological weapon waste containing who knows what, probably tracking biochip and was released very sick and impaired. It took me whole week to recover and ever since then I am tracked by the minute. The 4pgs Report of the incident is below.**

AFTER VISIT SUMMARY

Dimitar K. Dermendziev MRN: 4842097  
 3/18/2021 6:15 PM Skagit Regional Clinics Urgent Care Smokey Point 360-657-8700

Instructions from Sean M. Burson, ARNP

Your heel pain is consistent with plantar fasciitis, this is an inflammation at the attachment site of the plantar fascia to your heel. Please do the stretching exercises as I have shown you, and use a frozen can of orange juice or other frozen cans to roll under the foot to help relieve the inflammation. You may take over-the-counter Tylenol or ibuprofen if you so choose. Follow-up with your primary care doctor or return to urgent care for any worsening concerns.

Sean Burson, FNP  
 Urgent Care Provider  
 Skagit Regional Clinics

**Your medications have changed today**  
 See your updated medication list for details.

**Read the attached information**  
 Additional instructions from Sean M. Burson, ARNP

**What's Next**  
 You currently have no upcoming appointments scheduled.

**Your Medication List** as of March 18, 2021 6:54 PM  
 You have not been prescribed any medications.

Today's Visit

You saw Sean M. Burson, ARNP on Thursday March 18, 2021. The following issue was addressed: Plantar fasciitis.

Blood Pressure 112/54	BMI 25.80
Weight 185 lb	Height 5' 11"
Temperature 97 °F	Pulse 100
Respiration 18	Oxygen Saturation 97%

Skagit Regional Health  
**MyChart Sign-Up**  
 Send messages to your doctor, view your test results, renew your prescriptions, schedule appointments, and more.  
 Go to <http://www.skagitregionalhealth.org>, click "Sign Up Now", and enter personal activation code: 79C  
 Activation code expires 4/2/

AFTER VISIT SUMMARY

Dimitar K. Dermendziev MRN: 34520350 7/26/2021 9:30 AM SMOKEY POINT WALK IN 360-454-1922

Instructions from Marianne K McElroy, PA-C

Dear Mr. Dermendziev

Thank you for your recent visit. I hope your visit was helpful and you are feeling better. Please don't hesitate to call or come by if you have any questions or concerns. We appreciate your time and your trust in us to take care of you.

Here are the diagnoses that we discussed today:

1. Right foot infection

ICD-10-CM  
**L08.9**

Today's Visit

You saw Marianne K McElroy, PA-C on Monday July 26, 2021. The following issue was addressed: Right foot infection.

Blood Pressure 108/68	BMI 25.66
Weight 184 lb (83.5 kg)	Temperature (Temporal) 97.9 °F
Pulse 88	Respiration 14

Marianne K McElroy, PA-C  
 EVERETT CLINIC SMOKEY POINT  
 SMOKEY POINT WALK IN  
 2901 174TH STREET NE  
 MARYSVILLE WA 98271  
 Dept: 360-454-1922 — 1800  
 Fax 360-454-1991

MyChart makes it easy!

Schedule appointments, message your provider, view test results, renew prescriptions and more!

Sign up now at [www.myhealthchart.com](http://www.myhealthchart.com)

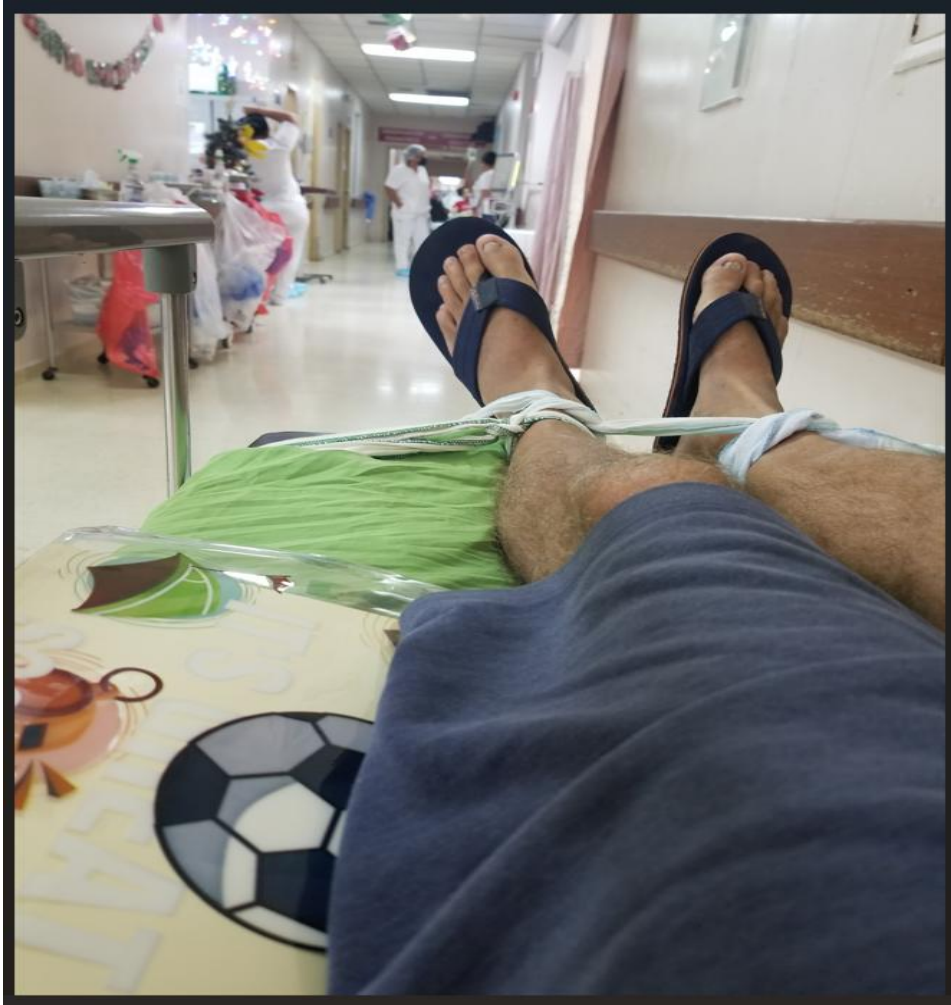One of dozens of examples in the span of many years proving the victim has Lifelong Normal Homeostatic VS Vital Signs are around 110/60 or less, Pulse 50 or less. Thus, dispelling the standard medical lie of Essential Hypertension which is used for marketing dangerous life-threatening hypertension toxic useless drugs. VS as a measure of essential body organs functions are symptoms of a disease and not diseases. And in absence of any other triggers, they are here solid med evidence of DEWs attack firings. They the VSs are flashing red warning lights that those essential body functions consistent with the victim's report have been compromised and are providing important med evidence in formulating true med diagnoses which in the instant case and prior is routinely isolated and ignored and often omitted, mislabeled or falsified to promote false diagnoses for the simple reason it fits victim's true narrative of events but does not fit in the medical accomplices fake findings.



**Criminal Complaint Affidavit  
Assault with deadly biological  
weapon and torture**

After being tortured all day January 01, 2025, by the usual means with DEWs- Directed Energy Weapons-Lasers usually discharged from weaponized satellites, drones, aircraft, microwave beamforming cell towers, vehicles driven by gangstalkers, and on foot gangstalkers I checked in the Emergency Room at Nicolas Solano Government Hospital to

collect the medical evidence of the daily physical torture injuries. After an unusual long wait and complaints of mine about it, I was seen by female ER-Emergency Doctor Dr. Yanina Geovanna Munoz Reyes who ordered tests and X Rays after handing to her my 2pgs medical complaint<sup>4</sup> including extensive crime induced symptomology. My initial VS Vital Signs, a measure of essential body functions, were deliberately omitted by the triage nurse and later by the doctor. Only the final VS were recorded, which were still abnormally high and comparable with the first and consistent with the



<sup>4</sup> To: All Medical Staff-Directed Energy Weapons DEWs or Lasers Daily Torture Events and Related Injuries and Symptomologies

patient complaints of DEWs attacks. The doctor, Dr. Yanina Geovanna Munoz Reyes who was instructed by a higher up in the hospital administration to cover up any med evidence of the crime, by any means made a false entry of hypertension<sup>5</sup> and false diagnosis of persistent delusional disorder<sup>6</sup>, which have never been part of my healthy lifestyle<sup>7</sup> nor a med history fact<sup>8</sup>. The X Rays were not taken with a squeezed belly like the first ER on Nov 22,2024 and were tampered with, to conceal the injuries. The doctor, after whitewashing all the med test results, sneakily mentioned I would be seen by a specialist but did not elaborate what kind of specialist. She refused to give me the discharge papers and said I will get in the morning with the specialist upon return to the hospital. In the morning exhausted from lack of sleep I went back to get the fake med documents. There I was seated in a ER doctor's office waiting for half an hour. The ER doctor returned with two women who claimed to be psychiatrists and who blatantly stated they will inject me one time. I was shocked and flabbergasted at such a blatant sneaky criminal attempt to violate my body integrity and my rights as a patient to be free of any med abuse and assaults including med torture.<sup>9</sup> Outraged I made the point that there was absolutely no basis for this despicable horrible criminal act and there has never been any lifelong MH issues and stated rightly so to the woman psychiatrist Dr. Sandra Gonzalez MH that she is a hard core criminal psychopath and refused any physical interference and asked for city police presence, asked for attorney and a phone call to USA Embassy. I was refused and not given a chance to legally defend myself. Upon an order of the female psychiatrist criminal Dr. Sandra Gonzalez MH, several med staff members forcibly tight my hands and feet to a hospital bed and placed me in the crowded hallway to be tortured for many hours and injected<sup>10</sup> twice with a nerve toxin poison that cause many adverse effects including panic attacks feelings, drowsiness, fatigue, impairment and other toxic debilitating and latent effects. Upon the second injection I was released from the hospital in a very weak impaired state. It took me several days to partially recover from the debilitating toxins effects. It should be evident by now that the USA sponsored terrorists who monitor by GPS, by phone and by other means my car location have used their false gov credentials to get the cooperation of Panamanian gov authorities including hospital administrator to organize the coverup of the med evidence of their

---

<sup>5</sup> Hypertension is not a disease but a symptom of disease or compromised body organs function which in my case is daily compromised by DEWs attacks. See photos. Incompetent doctors abuse routinely that term in order to prescribe dangerous unneeded toxic allopathic drugs and get kickbacks.

<sup>6</sup> I have no MH Mental Health history and according to prior psychological psychiatric evaluation in WA State there were no findings of any MH issues.

<sup>7</sup> All my life I have been healthy physically active individual and "Polar Bear" swimmer with no preexisting conditions and no routine risky promiscuous lifestyle, never abused legal or illegal drugs or alcohol. I have recently in first week of January 2025 completed alone a long-distance round-trip swim from the Grand Isla Beach near Colon City Panama, to the front large distant island which can be confirmed by the locals. And incidentally I was microwaved from above on the way back by the terrorists who attack me in any locations any time anywhere. My abdomen and throat were swollen and painful from the radiation directed at me.

<sup>8</sup> My lifelong homeostatic VS are 110/60 or less, Pulse 60 or less. Any numbers above that are direct evidence of electronic torture which the criminal weaponized med staff in every location country has attempted numerous times to conceal, falsify, omit or downplay as fictitious nonexistent hypertension. See photos.

<sup>9</sup> There were several unsuccessful sneaky illegal attempts by the perpetrators of electronic torture to have weaponized med staff cowards in several countries to attack my credibility as a victim of state sponsored terrorism experimentation by making false MH claims to devalue my truthful claims and evidence and enhance their credibility. To Panamanian authorities disgrace this Solano gov hospital assault kidnapping torture was first time ever happen to me outside of several sneaky attempts by a hospital med criminals in several countries.

<sup>10</sup> There is no telling what else was in those bioweapon injected fluids-Was it a Nano assembly particles? or an implant? Or a nanobots? or a spike protein? or other cancer inducing substance, or what else. Since then, my brain function has been weakened and compromised, being lightheaded and impaired and my vision rapidly deteriorates when I am attacked with harmful DEWs.

crimes and orchestrate the ambush kidnapping by two psychiatrists criminals. The intake female ER doctor a hard-core criminal psychopath and pathological liar herself had absolutely no legal, medical or any valid basis reason to order psychiatrist<sup>11</sup> intervention despite the factual 2pgs med complaint documentation I have presented to her. Disagreeing with her false manipulated med findings is not a valid reason to torture another human being who was not given a chance to legally defend himself. Being accomplished pathological liar and dangerous abuser of human rights she definitely needs a "psychiatry" herself and moreover a criminal investigation of her and the two women psychiatrists that executed the illegal ambush kidnapping torture on behave of an American terrorist. It is not a legal function of Panamanian authorities to shamelessly assist international terrorism which operates outside the national and international laws. Which explains the unusual measures taken, including wholesale shameless lying by weaponized med hospital staff, this shocking hospital psychiatry incident physical assault designed in advance to punish the victim for his truthful reporting of the ongoing crime and to cover up any med evidence of their daily criminal unamerican activities. Those hospital perpetrators sociopaths should be criminally prosecuted, and their licenses suspended for good. Lacking any moral compass, honesty and integrity, they should never be allowed near another human being ever again and practice medicine. They are an inherent danger to mankind.

The trail of evidence starts with my body injuries which med staff are aware but refuse to divulge to the patient and falsely claim everything is normal while they provide the real med evidence to the terrorist's agents. The terrorists who monitor my car movements and phone, usually make arrangement in advance for med coverup by contacting the med staff before my arrival at any hospital. They get the real med evidence information from the med tests and then they use that valuable med data to monitor and adjust the intensity of daily electronic torture while the victim is holding an empty bag and given false diagnosis or no diagnosis, tampered radiological images, false incomplete radiological reports and medical data, or lied to or called names and assaulted by med death squads. The med staff perpetrators-ER doctors, Radiologists, Triage nurses, Administrators, Assessors, Technicians, others, should be questioned under oath as to who asked them to conceal and tamper the med facts, tests, radiological images, write false incomplete med diagnosis and other med cover up attempts. Following this trail of evidence should allow the uncompromised local authorities to get to the bottom of this heinous international crime torture by DEWs. And not another covers up or silence. Another way to catch the criminals in action while shooting DEWs at the victim which is several times per day is the use of investigative detection devices that will detect the DEWs trajectory and discharges. Installing a "black box" detection recording device in the car and or my body that will monitor all acoustic, microwave, electromagnetic frequencies aimed in my car is another tool. Being homeless in the car I am being microwaved from microwave beamforming weaponized cell towers or satellites or drones while sleeping in my car, which explains the pain and irritation in my throat and lungs every morning and deteriorating skin conditions. That pain listed in my 2pgs complaint symptomology was one of the reasons I checked in the Nicolas Solano Hospital ER. The terrorists whose transparent goal is to torture their victims to death are trying to induce incurable deadly throat lung and brain cancer.

---

<sup>11</sup> The perps deliberately overlooked my injuries and the undisputed fact I never had any MH history, never used abused legal or illegal drugs and alcohol or engaged routinely in risky promiscuous lifestyle or had any preexisting conditions to explain my physical body crime induced injuries. Given the fact there is no valid science behind the discredited psychiatry a form of modern-day witchcraft and bullying, any MH attacks against our Tis-Targeted Individuals (see TargetedJustice.com) credibility should be viewed as indirect evidence of the truth of the matter asserted by us and adoptive admission of guilt by the perps who are desperate to conceal their crimes by any sneaky covert means. In former communist countries MH name callings were used to degrade and silence dissidents and critics of the regime.

I request thorough medical criminal investigation by an uncompromised med and government authorities, not another cover up including total silence. This is not a case “Owoo this is happening to someone else not me...or Owoo, I am too scared to investigate...”. This is case where everyone is a potential target for a potential torture experiment and eventually this developing antihuman extermination technology will be used against everybody on a massive scale and is already used right now even against their own agents. Everyone is a military target. If I am not safe, you are not safe, no one is safe, period. It is axiomatic. This is not the time to rush to protect the international terrorists and their torture program experimentation which is a suicidal lunacy. This is the time to go in a full-frontal attack to apprehend arrest and expose this expanding international crime spree. The time is running now, and the window of opportunity is getting smaller. Burying heads in the sand and cooperating with the terrorists will not save no one. There is no safety in joining the ranks of the criminals as those persistently delusional med staff did and do, and If you do not act now and investigate and stop this ever-expanding torture crime spree against humanity, tomorrow will be too late and you too will be the next victims. Be assured, cooperating with the terrorists disguised as gov agents is a sheer suicidal lunacy and delusion and will not save you. I am being repetitive deliberately. We are all expendable including the perps<sup>12</sup>. Get educated<sup>13</sup>, stop believing the communist globalist’s controlled fake media. You need to consider yourself lucky that a victim of electronic torture has come forward, has risked<sup>14</sup> everything to blow the trumpet and warn you and alert you of the incoming human worldwide genocide. You are now left with only one choice. Which is to act now. Inaction is delayed suicide and deadly. We, the whole of humanity, are in same boat and the boat is sinking. Are we going to fix the leaking holes or are we going jump from the sinking ship to our deaths. There is no one out there to rescue us. As one of many victims I see it coming because I am immersed in and living in it.

You have been warned and asked to act NOW!

I declare under the penalty of perjury under state and international laws that the forgoing is true statement of fact.

Dimitar Dermendziev, a TI-Targeted individual Category 3-Aware TI of the FBI (NIS) Non-Investigative Subjects illegal list

Playa Los Panama, Playa Herman, Panama, Central America

Date: Jan 31, 2025

Signature:

---

<sup>12</sup> Perpetrators-perps. When the perps are no longer useful or needed but a liability for the globalists they will be liquidated.

<sup>13</sup> Alternative Media-TargetedJustice.com, Brighteon.com, Ramble.com, Infowars.com and many others out there reveal and expose the real criminal global cabal responsible of crimes and warfare against humanity.

<sup>14</sup> As I continue to expose the terrorists and criminals including the weaponized ER med staff, the electronic torture continues to intensify to the point, I am on verge of losing my vision and or my body organs functions and or severe incapacitated or end up dead. LE Law Enforcement should not be surprised if they see my immobilized body along the road from now on. And at the Gov hospital the medical criminals will pronounce me falsely as a “Brain dead” even though I am not, and then they will proceed to harvest all my organs and remove all evidence of the crime. A scenario which happens every day across the globe.

**Declaración Jurada de Denuncia Penal**  
**Agresión con arma biológica mortal y tortura**



Después de ser torturado todo el día 01 de enero de 2025, por los medios habituales con DEW, armas de energía dirigida, láseres generalmente disparados desde satélites armados, drones, aviones, torres celulares de formación de haces de microondas, vehículos conducidos por pandillas y pandilleros a pie, revisé en la sala de emergencias del Hospital Gubernamental Nicolás Solano para recopilar la evidencia médica de las lesiones diarias de tortura física. Después de una larga espera inusual y quejas más al respecto, fui atendido por la doctora en emergencias de emergencias, la Dra. Yanina Geovanna Muñoz Reyes, quien ordenó pruebas y radiografías después de entregarme mi queja médica de 2 libras<sup>1</sup>, incluida una sintomatología inducida por un delito extenso. Mis signos vitales VS iniciales, una medida de las funciones corporales esenciales, fueron omitidos deliberadamente por la enfermera de triaje y más tarde por el médico. Solo se registraron los VS finales, que seguían siendo anormalmente altos y comparables con los primeros y consistentes con las quejas de los pacientes sobre los ataques de DEWs. La doctora, la Dra. Yanina Geovanna Muñoz Reyes, quien fue instruida por un superior en la administración del hospital para encubrir cualquier evidencia médica del crimen, por cualquier medio hizo una entrada falsa de hipertensión<sup>2</sup> y un diagnóstico falso de trastorno delirante persistente<sup>3</sup>, que nunca han sido parte de mi estilo de vida saludable<sup>4</sup> ni un hecho<sup>5</sup> de la historia médica. Las radiografías no se tomaron con el vientre apretado como la primera sala de emergencias del 22 de noviembre de 2024 y se manipularon para ocultar las lesiones. El médico, después de blanquear todos los resultados de las pruebas

<sup>1</sup> Para: Todas las armas de energía dirigidas por el personal médico DEWs o láseres Eventos de tortura diaria y lesiones y sintomatologías relacionadas

<sup>2</sup> La hipertensión no es una enfermedad, sino un síntoma de enfermedad o de una función comprometida de los órganos del cuerpo, que en mi caso se ve comprometida diariamente por los ataques de DEW. Ver fotos. Los médicos incompetentes abusan rutinariamente de ese término para recetar medicamentos alopáticos tóxicos peligrosos e innecesarios y obtener sobornos.

<sup>3</sup> No tengo antecedentes de salud mental de MH y, de acuerdo con una evaluación psiquiátrica psicológica previa en el estado de WA, no hubo hallazgos de ningún problema de MH.

<sup>4</sup> Toda mi vida he sido una persona sana, físicamente activa y nadadora de "Oso Polar" sin condiciones preexistentes y sin un estilo de vida promiscuo rutinario y riesgoso, nunca he abusado de drogas legales o ilegales o alcohol. Recientemente, en la primera semana de enero de 2025, completé solo un nado de ida y vuelta de larga distancia desde la playa Grand Isla cerca de la ciudad de Colón, Panamá, hasta la gran isla lejana del frente, lo que puede ser confirmado por los lugareños. Y, por cierto, en el camino de regreso, los terroristas me lanzaron al microondas desde arriba y me atacaron en cualquier lugar, en cualquier momento y en cualquier lugar. Mi abdomen y mi garganta estaban hinchados y doloridos por la radiación dirigida hacia mí.


<sup>5</sup> Mis VS homeostáticos de toda la vida son 110/60 o menos, Pulse 60 o menos. Cualquier número por encima de eso es evidencia directa de tortura electrónica que el personal médico armado por el criminal en cada país ha intentado en numerosas ocasiones ocultar, falsificar, omitir o minimizar como hipertensión ficticia inexistente. Ver fotos.



médicas mencionó furtivamente que me vería un especialista, pero no detalló qué tipo de especialista. Se negó a darme los papeles de alta y me dijo que me pondría en contacto con el especialista por la mañana cuando regresara al hospital. Por la mañana, agotado por la falta de sueño, volví a buscar los documentos médicos falsos. Allí estaba sentado en el consultorio de un médico de urgencias esperando durante media hora. El médico de la sala de emergencias regresó con dos mujeres que afirmaron ser psiquiatras y que declararon descaradamente que me inyectarían una vez. Me quedé conmocionada y atónita por un intento criminal tan descarado y furtivo de violar la integridad de mi cuerpo y mis derechos como paciente a estar libre de cualquier abuso y agresión médica, incluida la tortura médica.<sup>6</sup> Indignado, señalé que no había absolutamente ninguna base para este despreciable y horrible acto criminal y que nunca ha habido ningún problema de MH de por vida y le dije con razón a la psiquiatra Dra. Sandra González MH que ella es una psicópata criminal dura y rechazó cualquier interferencia física y pidió la presencia de la policía de la ciudad. pidió un abogado y una llamada telefónica a la Embajada de EE. UU. Me lo negaron y no me dieron la oportunidad de defenderme legalmente. Por orden de la psiquiatra Dra. Sandra González MH, varios miembros del personal médico me apretaron a la fuerza las manos y los pies a una cama de hospital y me colocaron en el pasillo abarrotado para ser torturada durante muchas horas e inyectada<sup>7</sup> dos veces con un veneno de toxina nerviosa que causa muchos efectos adversos, incluidos ataques de pánico, sentimientos. somnolencia, fatiga, deterioro y otros efectos tóxicos, debilitantes y latentes. Después de la segunda inyección, me dieron de alta del hospital en un estado muy débil y deteriorado. Me tomó varios días recuperarme parcialmente de los efectos de las toxinas debilitantes. Debería ser evidente a estas alturas que los terroristas patrocinados por los EE.UU. que monitorean por GPS, por teléfono y por otros medios la ubicación de mi automóvil, han utilizado sus credenciales falsas del gobierno para obtener la cooperación de las autoridades del gobierno panameño, incluido el administrador del hospital, para organizar el encubrimiento de la evidencia médica de sus crímenes y orquestar la emboscada del secuestro por parte de dos psiquiatras criminales. La doctora de urgencias, una psicópata criminal empedernida y mentirosa patológica, no tenía absolutamente ninguna razón legal, médica o de base válida para ordenar la intervención

<sup>6</sup> Hubo varios intentos infructuosos e ilegales por parte de los perpetradores de la tortura electrónica para convertir en armas a cobardes del personal médico en varios países para atacar mi credibilidad como víctima de la experimentación terrorista patrocinada por el estado haciendo afirmaciones falsas de MH para devaluar mis afirmaciones y pruebas veraces y mejorar su credibilidad. Para vergüenza de los panameños, este asalto al hospital del gobierno de Solano, secuestro, tortura, fue la primera vez que me sucedió fuera de varios intentos furtivos de un hospital de delincuentes en varios países.

<sup>7</sup> No se sabe qué más había en esos fluidos inyectados con armas biológicas: ¿eran partículas de nanoensamblaje? ¿O un implante? ¿O un nanobots? ¿O una proteína de pico? u otra sutileza inductora de cáncer, o lo que sea. Desde entonces, mi función cerebral se ha debilitado y compaginado, mareado y deteriorado, y mi visión se deteriora rápidamente cuando me atacan con DEW dañinos.



de un psiquiatra,\* a pesar de la documentación fáctica de la queja médica que le he presentado. Estar en desacuerdo con sus falsos hallazgos médicos manipulados no es una razón válida para torturar a otro ser humano al que no se le dio la oportunidad de defenderse legalmente. Siendo una consumada mentirosa patológica y una peligrosa abusadora de los derechos humanos, definitivamente necesita una "psiquiatría" ella misma y, además, una investigación criminal de ella y de las dos psiquiatras que ejecutaron la emboscada ilegal, el secuestro, la tortura y el comportamiento de un terrorista estadounidense. No es una función legal de las autoridades panameñas ayudar descaradamente al terrorismo internacional que opera al margen de las leyes nacionales e internacionales. Lo que explica las medidas inusuales tomadas, incluida la mentira desvergonzada al por mayor por parte del personal del hospital medicized, este impactante incidente de psiquiatría hospitalaria agresión física diseñada de antemano para castigar a la víctima por su informe veraz del crimen en curso y para encubrir cualquier evidencia médica de sus actividades criminales diarias antiamericanas. Esos sociópatas que agreden a los hospitales deberían ser procesados penalmente y sus licencias suspendidas para siempre. Al carecer de toda brújula moral, honestidad e integridad, nunca más se les debe permitir acercarse a otro ser humano y practicar la medicina. Son un peligro inherente a la humanidad.

El rastro de evidencia comienza con mis lesiones corporales, que el personal médico es consciente pero se niega a divulgar al paciente y afirma falsamente que todo es normal, mientras que proporcionan la evidencia médica real a los agentes terroristas. Los terroristas que monitorean los movimientos de mi coche y mi teléfono, por lo general hacen arreglos con anticipación para el encubrimiento de los medicamentos poniéndose en contacto con el personal médico antes de mi llegada a cualquier hospital. Obtienen la información real de las pruebas médicas y luego usan esos valiosos datos médicos para monitorear y ajustar la intensidad de la tortura electrónica diaria mientras la víctima sostiene una bolsa vacía y recibe un diagnóstico falso o ningún diagnóstico, imágenes radiológicas manipuladas, informes radiológicos falsos incompletos y datos médicos, o mentida o insultada y agredida por escuadrones de la muerte médica. Los perpetradores del personal médico, médicos de emergencias, radiólogos, enfermeras de triaje, administradores, asesores, técnicos, otros, deben ser interrogados bajo juramento sobre


---

\* Los delincuentes deliberadamente pasaron por alto mis lesiones y el hecho indiscutible de que nunca tuve ningún historial de MH, nunca usé drogas y alcohol legales o ilegales abusados, ni participé rutinariamente en un estilo de vida promiscuo riesgoso ni tuve condiciones preexistentes para explicar mis lesiones inducidas por delitos corporales. Dado el hecho de que no hay una ciencia válida detrás de la desacreditada psiquiatría, una forma de brujería e intimidación moderna, cualquier ataque de MH contra nuestra credibilidad de los Individuos Dirigidos a los Tis (ver TargetedJustice.com) debe ser visto como una evidencia indirecta de la verdad del asunto afirmada por nosotros y una admisión adoptiva de culpabilidad por parte de los delincuentes que están desesperados por ocultar sus crímenes por cualquier medio encubierto furtivo. En los antiguos países comunistas, los insultos de MH se utilizaron para degradar y silenciar a los disidentes y críticos del régimen.



quién les pidió que ocultaran y manipularan los hechos médicos, las pruebas, las imágenes radiológicas, escribieran diagnósticos médicos falsos incompletos y otros intentos de encubrimiento de medicamentos. Seguir este rastro de pruebas debería permitir a las autoridades locales intransigentes llegar al fondo de este atroz crimen internacional: la tortura por parte de los DEW. Y no otro encubre o silencio. Otra forma de atrapar a los delincuentes en acción mientras disparan DEW a la víctima, que es varias veces al día, es el uso de dispositivos de detección de investigación que detectarán la trayectoria y las descargas de los DEW. La instalación de un dispositivo de grabación de detección de "caja negra" en el automóvil o en mi cuerpo que monitoreará todas las frecuencias acústicas, de microondas y electromagnéticas dirigidas a mi automóvil es otra herramienta. Al estar sin hogar en el automóvil, me están calentando en el microondas desde torres celulares armadas, satélites o drones con formación de haces de microondas mientras duermo en mi automóvil, lo que explica el dolor y la irritación en mi garganta y pulmones todas las mañanas y el deterioro de las condiciones de la piel. Ese dolor que figuraba en mi sintomatología de queja de 2 pgs fue una de las razones por las que me revisé en la sala de emergencias del Hospital Nicolás Solano. Los terroristas, cuyo objetivo transparente es torturar a sus víctimas hasta la muerte, están tratando de inducir un cáncer de garganta, pulmón y cerebro incurable y mortal.

Solicito una investigación médica criminal exhaustiva por parte de un **médico y autoridades gubernamentales intransigentes**, no otro encubrimiento que incluya el silencio total. Este no es un caso: "Owoo, esto le está pasando a otra persona, no a mí... o Owoo, tengo demasiado miedo para investigar...". Este es el caso en el que todo el mundo es un objetivo potencial para un posible experimento de tortura y, con el tiempo, esta tecnología de exterminio antihumano en desarrollo se utilizará contra todo el mundo a gran escala y ya se utiliza ahora mismo incluso contra sus propios agentes. Todo el mundo es un objetivo militar. Si yo no estoy a salvo, tú no estás a salvo, nadie está a salvo, punto. Es axiomático. Este no es el momento de apresurarse a proteger a los terroristas internacionales y su experimentación del programa de tortura, que es una locura suicida. Este es el momento de lanzarse a un ataque frontal para detener, arrestar y exponer esta ola de crímenes internacionales en expansión. El tiempo corre ahora y la ventana de oportunidad se está reduciendo. Enterrar cabezas en la arena y cooperar con los terroristas no salvará a nadie. No hay seguridad en unirse a las filas de los criminales como lo hizo y lo hace ese personal médico persistentemente delirante, y si ustedes no actuamos ahora e investigamos y detenemos esta ola de crímenes de tortura contra la humanidad en constante expansión, mañana será demasiado tarde y ustedes también serán las próximas víctimas. Tenga la seguridad de que cooperar con los terroristas disfrazados de agentes del gobierno es una locura y un delirio suicida y no los salvará. Estoy siendo repetitivo deliberadamente. Todos somos prescindibles, incluidos los



delinquentes<sup>9</sup>. Edúquense<sup>10</sup>, dejen de creer en los medios falsos controlados por los comunistas globalistas. Tienes que considerarte afortunado de que una víctima de la tortura electrónica se haya presentado, lo haya arriesgado<sup>11</sup> todo para tocar la trompeta y advertirte y alertarte del genocidio humano mundial que se avecina. Ahora solo te queda una opción. Que es actuar ahora. La inacción es un suicidio tardío y mortal. Nosotros, la humanidad entera, estamos en el mismo barco y el barco se está hundiendo. ¿Vamos a arreglar los agujeros que gotean o vamos a saltar del barco que se hunde a nuestra muerte? No hay nadie ahí fuera para rescatarnos. Como una de las muchas víctimas, lo veo venir porque estoy inmerso en él y vivo en él.

¡Se les ha advertido y se les ha pedido que actúen AHORA!

Declaro bajo pena de perjurio bajo las leyes estatales e internacionales que lo anterior es una verdadera declaración de hecho.

Dimitar Dermendziev, un individuo de TI de categoría 3 de la lista ilegal de sujetos no investigativos del FBI (NIS)

Playa Los Panamá, Playa Herman, Panamá, Centroamérica

Fecha: Firma:

Jan 31, 2025



Yo, la suscrita, Lisette SUAREZ JUDITH REYES, Notaria Pública General del Circuito de Panamá Oeste, con Cédula No. 8-521-1899

Que constó en (n) firmado este documento en su presencia y en la de los testigos que se reciben, y por tanto, queda (n) en fe (n) en (n) (s).  
Panamá Oeste, 31 ENE 2025

TESTIGOS: TESTIGOS:   
Notaria Pública Lisette SUAREZ JUDITH REYES, Notaria Pública General del Circuito de Panamá Oeste

<sup>9</sup> Perpetradores-delinquentes. Cuando los delinquentes ya no sean útiles o necesarios, sino un lastre para los globalistas, serán liquidados.

<sup>10</sup> Las Media-TargetedJustice.com alternativas, Brighteon.com, Rambler.com, Infowars.com y muchas otras revelan y exponen a la verdadera cábala criminal global responsable de crímenes y guerras contra la humanidad.

<sup>11</sup> A medida que continúo exponiendo a los terroristas y criminales, incluido el personal médico de la sala de emergencias armado, la tortura electrónica continúa intensificándose hasta el punto de que estoy a punto de perder mi visión y/o las funciones de mis órganos corporales y/o incapacitarme gravemente o terminar muerto. La policía de LE no debería sorprenderse si ven mi cuerpo inmovilizado a lo largo de la carretera a partir de ahora. Y en el hospital del Gobierno, los criminales médicos me declararán falsamente como "muerto cerebral" aunque no lo sea, y luego procederán a extraer todos mis órganos y eliminarán todas las pruebas del crimen. Un escenario que ocurre todos los días en todo el mundo.

**Filed the Criminal Complaint Affidavit in English and Spanish with the Chorrera Panama Prosecutor Office.** After typing their own convoluted version in Spanish and reading it to me in English they asked me to sign their own Spanish version. I refused to sign it because they did not let me translate it by any means to see what they wrote and suspecting foul play I refused to sign it. And then they dropped the criminal case because I refused to sign their unknown version to me. I can not sign documents knowingly intelligently without reading them and verifying if it is a true compilation of my Affidavit or made-up nonsense.

And the Panama Biden US Embassy staff did nothing to pursue the egregious violation of my basic human rights after submitting the whole case documents to them and they threw me under the bus with customary deliberate indifference.

**After Panama, in Batumi, In Georgia, Caucus Region** with my continued social media exposure of the Deep State unconvicted terrorists, the DEWs electronic torture daily abdominal microsurgeries vivisections injuries continued to intensify causing acute kidneys trauma pain and suffering. With the assistance of rogue bribed police members <sup>15</sup>who helped assisted the Deep State criminals by enlisting obedient bribed Hotel's owners to engage in sleep harassment sleep torture including the use of provided eavesdropping detection devices that monitor sleeping snoring breathing and brain waves patterns to successfully conduct the sleep harassment and torture by all means continued. In addition, the hotel owners were induced to harass their victim by sending minors to bang on my hotel room, throw objects, inciting hate and resentment among the hotel guests and social isolation. On July 19, 2025, during intense sleep torture in the middle of the night by the owners father and son of Hotel Khomaldi at Gonio Beach, Gonio near Batumi where I paid \$500 per month to be tortured, I called the Police. After the police caught them lying in the face of overwhelming evidence the police did nothing to them, took pictures of me and in the following night the sleep harassment resumed. Even after I changed the hotel to another nearby, Hotel Sandro the electronic torture continued with such intensity that the family owners and their dog whose permanent living quarters were below my room were evacuated for several months so they won't get hurt while anticipating I would die soon. Being seriously gravely injured especially my kidneys I checked into two major clinics in Batumi-BMC Batumi Medical Center and AMC American Medical Center where I paid cash. At BMC where I reported my chief symptoms-swollen painful full of free air abdomen, backache painful kidney areas, burning painful incomplete urination, blurred vision and others while under a lot of pain and stress, I wasted my money and time to be told all is normal after physical exam, Ultrasound and battery of tests. The first Urologist Dr. Gela Lomadze who did the exam and tests refused to give me diagnosis a week later because he did not want to lie about my serious condition. Because of his hours of refusal, I called the hospital police. He still refused. He was then replaced with Dr. Didmandze. While some blood tests were abnormal the most pertinent urine tests like crystals, salts, bacteria and others were hidden and laced with false labels. So, one week later second urologist Dr. Mzia Didmandze based on falsified med tests issued false lying by omission diagnosis and without doing herself standard physical exam while collecting the full fee. The most ailing painful weakest organ the kidneys urine tests results numbers like salts, crystals, bacteria occupying half of the page were hidden and replaced with

---

<sup>15</sup> Within a month of my arrival in Batumi Gonio Georgia Caucus Region Febr, 2025, I called 211 and reported to the local police that I am being tormented fired upon with DEWs. They just laughed and left. But months later I witnessed in only 3 occasions being fired with acoustic DEWs by police cars which discontinued since then after they realized I knew. So, most of drive by shooting with DEWs is done by ununiformed contracted civilians gangstalkers and maybe off duty dirty cops.

convenient labels like **“Not Mentioned”** or **“In Insignificant amounts”** which is unprecedented hearsay med evidence. Less than 10 minutes Ultrasound exam by a trainee was also a shame. Sep 11, 2025, high abnormal VS caused by microwave and acoustic DEWs torture **B/P- 200/130 PR 80** vs Livelong Homeostatic Normals **<110/60 and PR<50**. Initially Dr. Gela Lomadze imposed to him criminal agenda to minimize hide the injuries was very reluctant to follow standard worldwide protocol to check the VS a crucial marker for kidneys function and risk, but upon my insistance reluctantly took me to the ER for VS measurement.





პაციენტის სახელი	დამიტრ	დერმენდოვიც
პაციენტის პირადი ნომერი	A32933547	
პაციენტის დაბადების	29.02.1956	პაციენტის ასაკი 69 წლის
პაციენტის სქესი	მამრობითი	ისტორიის N

თარიღი 11.09.2025 13:12

სისხლის საერთო ანალიზი

მაჩვენებელი	შედეგი	ერთეული	ნორმა
ლუციოციტები (WBC)	9,17	10 <sup>3</sup> /μL	5,20 - 12,40
ერიტროციტები (RBC)	4,57	10 <sup>6</sup> μL	4,3-5,7
ჰემოგლობინი (HGB)	13,9	g/dL	13,00 - 16,00
ჰემატოკრიტი (HCT)	42,7	%	40,00 - 48,00
ერიტროციტების საშუალო მოცულობა (MCV)	93,5	FL	75,00 - 94,00
ჰემოგლობინის საშუალო შემცველობა (MCH)	30,4	pg	27,00 - 33,00
ჰემოგლობინის საშუალო შემცველობა საერთო ერიტროციტულ მასაში(MCHC)	32,6	g/dL	30,00 - 38,00
თრომბოციტები (PLT)	204	10 <sup>3</sup> /μL	130,00 - 400,00
ერიტროციტების გადანაწილების ფართის სტანდარტული გადახრა RDW-SD	41,3	FL	35,10 - 46,30
ერიტროციტების განაწილების ზღვრები, ვარიაციის კოეფიციენტი (RDW-CV)	12,2	%	11,50 - 14,50
თრომბოციტების განაწილების ფართი (PDW)	16,2	FL	12,00 - 18,00
თრომბოციტების საშუალო მოცულობა (MPV)	8,8	FL	7,28 - 11,10
დიდი ზომის თრომბოციტების წილი PCT P-LCR		%	20,20 - 40,00
თრომბოციტი (PCT)	0,178	%	0,10 - 1,00
ნეიტროფილები ( NEUT )	4,37	10 <sup>3</sup> /μL	1,70 - 7,7
ნეიტროფილები (Neu)	47,7	%	50-80
ლიმფოციტები ( LYMPH)	3,85	10 <sup>3</sup> /μL	1,20 - 3,00
ლიმფოციტები ( LYMPH) %	42,0	%	18,00 - 40,00
მონოციტები (MONO) #	0,50	10 <sup>3</sup> /μL	0,17 - 1,10
მონოციტები (MONO) %	5,5	%	3,4-9,0
ეოზინოფილები (EO)	0,35	10 <sup>3</sup> /μL	0,00 - 0,9
ეოზინოფილები (EO %)	3,8	%	1,00 - 5,00
ბაზოფილები (Baso) #	0,05	10 <sup>3</sup> /μL	0,0 - 0,2
ბაზოფილები (Baso) %	0,5	%	0,3-1,5
ბლასტი Blasts (ფორმულა)		%	
პრომიელოციტები PROMYELOCYTES		%	
მიელოციტები (Myelocytes)		%	
მეტამიელოციტები (Metamyelocytes)		%	
ჩხირბირთვიანი ნეიტროფილები NEUT (ფორმულა)		%	0,00 - 5,00
სეგმენტბირთვიანი ნეიტროფილები (ფორმულა)NEUT		%	40,00 - 74,00
პლაზმური უჯრედები PLAS		%	0,00 - 0,00
ერიტროციტების დალექვის სიჩქარე (ESR)	20	mm/h	4,00 - 20,00
ე.დ.ს (ვეტერგრინის მეთოდი)		Mmm/st	<15

ექიმი ლაბორანტი

/ *[Handwritten Signature]*

ხათუნა დუდუჩავა

ექიმი ლაბორანტი

/ *[Handwritten Signature]*

ხათუნა დუდუჩავა



პაციენტის სახელი	დიმიტრ	დერმენდზივ
პაციენტის პირადი ნომერი	A32933547	
პაციენტის დაბადების	29.02.1956	პაციენტის ასაკი 69 წლის
პაციენტის სქესი	მამრობითი	ისტორიის N

თარიღი 11.09.2025 13:12

გლუკოზის განსაზღვრა სისხლში ;

მარკენგელი	შედეგი	ერთეული	ნორმა
გლუკოზის განსაზღვრა სისხლის შრატში	98,4	mg/dL	82,00 - 115,00

ექიმი ლაბორანტი

/ *hmf* /

ხათუნა დუდუჩავა

მარკენგელი	შედეგი	ერთეული	ნორმა
შარდოვანა Urea	3	მმოლ/ლ	2,5 - 7,2

ექიმი ლაბორანტი

/ *hmf* /

ხათუნა დუდუჩავა

მარკენგელი	შედეგი	ერთეული	ნორმა
კრეატინინი Creatinine	79	მკ/მოლ	58-110

ექიმი ლაბორანტი

/ *hmf* /

ხათუნა დუდუჩავა

მარკენგელი	შედეგი	ერთეული	ნორმა
საერთო პროსტატის სპეციფიკური ანტიგენი	3,38	ng/mL	0,00 - 2,50

ექიმი ლაბორანტი

/ *hmf* /

ხათუნა დუდუჩავა



პაციენტის პირადი ნომერი	A32933547		
პაციენტის დაბადების	29.02.1956	პაციენტის ასაკი	69 წლის
პაციენტის სქესი	მამრობითი	ისტორიის N	

თარიღი 11.09.2025 11:42

**შარდის საერთო ანალიზი**

მაჩვენებელი	შედეგი	ერთეული	ნორმა
გამოყოფილი შარდის რაოდენობა	100	მლ	
შარდის ფერი	ჩალისფერი		ყვითელი
გამჭვირვალობა	გამჭვირვალე		გამჭვირვალე
ურობილინოგენი (URO)	normal	mg/dL	<2
ერითროციტი/Erythrocytes	Negative (-)		<0.03
ბილირუბინი (BIL )			<0.5
ლეიკოციტი/Leucocytes/	Negative (-)	c/ul	<5
კეტოსხეულები (KET )	Negative (-)	mg/dL	<2mg/dl
ნიტრიტები (NIT)	Negative (-)		Negative
ცილა(protein)	Negative (-)	mg/dL	<0.15
რეაქცია	6.5		5.5-7.0
ხეცდრითი წონა(SC)	1005		1005-1025
კრეატინინი შარდში	50	mg/dL	<10
ალბუმინი შარდში ALB	10	mg/dL	<5
ეპითელი ზრტყელი (ნალექის მიკროსკოპია)	1-3	f/v	ერთეული(2-3)
გლუკოზა(GLU)	Negative (-)	mg/dL	
ლორწო(მიკროსკოპულად)		f/v	-
ეპითელი თირკმლის (ნალექის მიკროსკოპია)		f/v	არ აღნიშნება
ცილინდრები ჰიალინური (ნალექის მიკროსკოპია)		f/v	არ აღნიშნება
ცილინდრები მარცვლოვანი (ნალექის მიკროსკოპია)		f/v	არ აღნიშნება
ცილინდრები ერითროციტული (მიკროსკოპულად)		f/v	არ აღნიშნება
ცილინდრები ლეიკოციტური (მიკროსკოპულად)		f/v	არ აღნიშნება
ლეიკოციტები	4-5	მხ/არეში	მხ/არეში
ცილინდრები ეპითელიური (მიკროსკოპულად)		f/v	არ აღნიშნება
ერითროციტი შეუცვლელი (მიკროსკოპულად)	0-1-2		0-2 პრეპარატში
ერითროციტი შეცვლილი (მიკროსკოპულად)		f/v	არ აღნიშნება
მარილები ოქსალიტები (მიკროსკოპულად)		f/v	უწნიშენელო რაოდენობით
მარილები ტრიპელფოსფატები(მიკროსკოპულად)		f/v	უწნიშენელო რაოდენობით
მარილები ურატები (Urates) მიკროსკოპულად			უწნიშენელო რაოდენობით
მარილები შარდმჟავა კრისტალები (Uric Acid)			უწნიშენელო რაოდენობით
ზაქტერია		f/v	არ აღნიშნება

ექიმი ლაზორანტი

/ *Handwritten Signature* /

ხათუნა დუდუჩავა

შპს «ხათუნის სამედიცინო ცენტრი» ხათუნა, კახაბერის ქ. N36 +995577481169 info@bmcmedical.ge



პაციენტის პირადი ნომერი	A32933547	პაციენტის დაბადების	29.02.1956	პაციენტის ასაკი	69 წლის
პაციენტის სქესი	მამრობითი	ისტორიის N			

თარიღი 11.09.2025 13:12

კრეატინინის განსაზღვრა სისხლის შრატში; Creatinine

მაჩვენებელი	შედეგი	ერთეული	ნორმა
კრეატინინი Creatinine	79	მკ/მოლ	58-110

ექიმი ლაბორანტი

/ *hmf*

ხათუნა დუდუჩავა

მაჩვენებელი	შედეგი	ერთეული	ნორმა
საერთო პროსტატის სპეციფიკური ანტიგენი	3,38	ng/mL	0,00 - 2,50

ექიმი ლაბორანტი

/ *hmf*

ხათუნა დუდუჩავა

მაჩვენებელი	შედეგი	ერთეული	ნორმა
შარდოვანა Urea	3	მმოლ/ლ	2,5 - 7,2

ექიმი ლაბორანტი

/ *hmf*

ხათუნა დუდუჩავა

Dr. Mzia Didmandze's Diagnosis False Incomplete.

My chief complaint of abdominal free air, kidney back pain, painful incomplete thin urination was knowingly intelligently deliberately omitted just like the Urine Results



დამტკიცებული სახორციელოს შრომის, ჯანმრთელობის და სოციალური დაფის მინისტრის 2 0 0 7 წ. 9 აგვისტოს N338.ნ ბრძანებით

სამედიცინო დოკუმენტაცია ფორმა IV-100/ა

დოკუმენტის N :  
ანულატორული მართვის ნომერი: აზ8.79368  
მართვის ნომერი: visit\_40005

ცნობა ჯანმრთელობის მდგომარეობის შესახებ

1. ცნობის გამგეში დაწესებულების დასახელება ან ექიმი-სპეციალისტის გვარი, სახელი, სახელმწიფო სერტიფიკატით მიანიჭებული სპეციალობა, სახელმწიფო სერტიფიკატის ნომერი ან/და საკონტაქტო ინფორმაცია

შპს «ბათუმის სამედიცინო ცენტრი» (ს/კ 248384234) ; საქართველო, ქ.ბათუმი 6010 , კახაბერის ქ. N36;  
ტელ: (+995)577481169, ცხელი ხაზი: (+995) 577 48 11 64 , ელ.ფოსტა: batumihospital@gmail.com  
Batumi Medical Center LLC, 36 Kakhaberi, str; 6010 , Batumi, Georgia;  
Tel: (+995)577481169, Hot line: (+995) 577 48 11 64 , E-mail: batumihospital@gmail.com

2. დაწესებულების დასახელება, მისამართი, სადაც იგზავნება ცნობა  
საკურობისამებრ წარსადგენად

3. პაციენტის სახელი და გვარი დიმიტრ დერმენდზიძე

4. დაბადების თარიღი (რიცხვი/თვე/წელი) 29.02.1956

5. პირადი ნომერი A32933547

6. მისამართი

მზა:

7. სამუშაო ადგილი და თანამდებობა, (მოსწავლის/სტუდენტის შემთხვევაში -იმ სასწავლო დაწესებულების/სკოლის დასახელება და კლასი/კურსი,სადაც იგი სწავლობს)

8. თარიღები

ა) ექიმთან მიმართვის 18.09.2025 15:00:00

ბ) სტაციონარში გაგზავნის

გ) სტაციონარში მოთავსების

დ) გაწერის

9. დასკვნა ჯანმრთელობის მდგომარეობის შესახებ ან სრული დიაგნოზი (ძირითადი დაავადება, თანმხლები დაავადებები, გართულებები)

დიაგნოზი: [N28.1]თირკმლის კისტა, შედენილი

10. გადატანილი დაავადებები

ხელშეა ასაკის ინფექციები: • ხელშეა ინფექციები

11. მოკლე ანამნეზი

ჩვილები: პაციენტი აღნიშნავს,რომ რამდენიმე დღის წინ პქონდა ტკივილი მუცლის არეში და გახშირებული შარდვა.

ანამნეზი: პაციენტის ზოგადი მდგომარეობა არის სტაბილური.

მუცელი რბილია,პალპაციით უმტკიველულია.

შარდვის საერთო ანალიზი და სისხლის ანალიზები პათოლოგიური ცვლილებების გარეშე. PSA -ნორმის ფრაგლებშია.

პაციენტს შეეძენ უროლოგიური პრობლემა არა აქვს.

12. ჩატარებული დიაგნოსტიკური გამოკვლევები და კონსულტაციები

13. ავადმყოფობის მიმდინარეობა

ავადმყოფობის მიმდინარეობა: ქრონიკული

14. ჩატარებული მკურნალობა

15. მდგომარეობა სტაციონარში გაგზავნისას

16. მდგომარეობა სტაციონარიდან გაწერისას

17. სამკურნალო და შრომითი რეკომენდაციები

სამკურნალო და შრომითი რეკომენდაცია: პროსტატის ულტრაბგერითი კვლევა.

18. მკურნალი ექიმი მზია დიდმანიძე

ექიმის სერტიფიკატი № 006114 / 25.05.2001 - უროლოგია

ის სერთიფიკატი № 001872 / 31.10.2008 - ონკოლოგია

9. დაწესებულების ხელმძღვანელის/ხელმძღვანელის მოადგილის ხელმოწერა

გენერალური დირექტორი:

სოსო ჯაბია

20. ცნობის გაცემის თარიღი



## Medical Science:

### Free Air in Abdomen (Abnormal)

Air outside the intestines in the peritoneal cavity, called pneumoperitoneum

This is abnormal and usually indicates a serious problem

Most caused by a perforated organ (like a ruptured ulcer or bowel perforation)

Requires urgent medical attention and often surgery

Free Air in Abdomen: Causes, Symptoms, and Treatment Free air in the abdomen refers to the presence of air or gas within the peritoneal cavity, the space within the abdomen that houses vital organs such as the intestines, liver, and stomach. This condition can have various causes, ranging from trauma or injury to underlying gastrointestinal conditions. **Recognizing the signs and symptoms of free air in the abdomen is crucial for timely diagnosis and treatment. Patients may experience a distended abdomen, abdominal pain or tenderness, or a condition known as acute abdomen, which refers to sudden and severe abdominal discomfort.**<sup>16</sup>

Understanding the causes of free air in the abdomen helps shed light on how this condition can develop. Factors like abdominal trauma or intestinal injuries can lead to the escape of air into the peritoneal cavity, causing pneumoperitoneum.

Left untreated, free air in the abdomen can lead to serious complications, including peritonitis, a potentially life-threatening condition that requires immediate medical attention. Therefore, prompt diagnosis and appropriate treatment are vital in managing this surgical emergency.

<sup>16</sup> These are the exact condition symptoms experienced when ambushed and fired upon with portable or car mounted acoustic DEW from approaching gangstalking vehicle while walking on the streets. Intestinal gas and belching are not always or immediately present and may not manifest at all which proves to me the diagnose of Functional Meteorism is false made-up story and inconsistent with med protocol requiring the practitioner to rule out all other causes before making determination. DEWs are directional, they can aim at any specific organ such as stomach causing distention, kidneys- causing urinary tract infections, hydronephrosis and hydroureter, liver- very high triglycerides level, disorders of lipoprotein metabolism and other lipidemia, colon-causing diverticulitis, abdomen- pneumoperitoneum free air.

Treatment options for free air in the abdomen depend on the underlying cause and severity of the condition. While non-surgical interventions may be sufficient in some cases, others may require surgical intervention to address the cause of the pneumoperitoneum effectively.

Prevention is always better than cure, and there are measures individuals can take to reduce their risk of developing free air in the abdomen. Whether it's avoiding abdominal trauma or seeking timely medical attention for gastrointestinal symptoms, proactive steps can make a significant difference. Remember, free air in the abdomen is a medical condition that requires urgent evaluation by a healthcare professional. If you suspect you or someone you know might be experiencing this condition, seek immediate medical assistance.

Regular follow-up care is essential for individuals who have free air in the abdomen. This helps ensure that any potential long-term effects are monitored and managed effectively, promoting a positive prognosis and overall well-being.

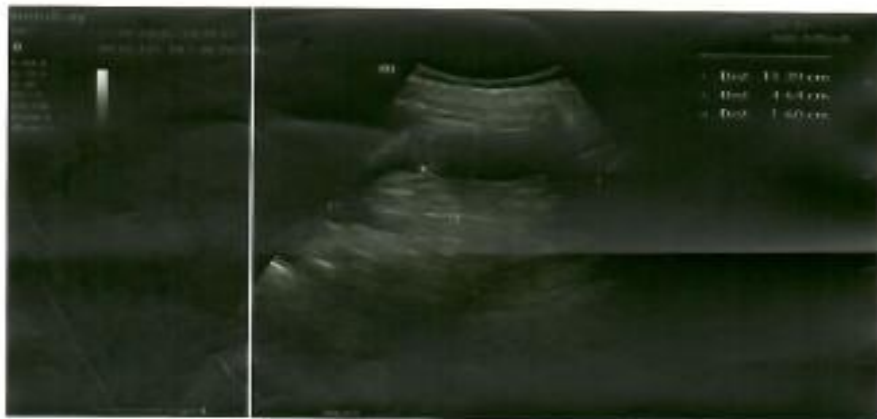
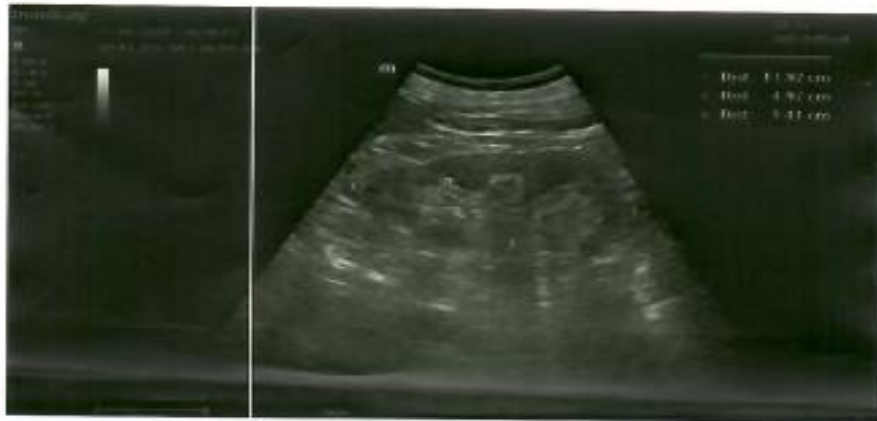
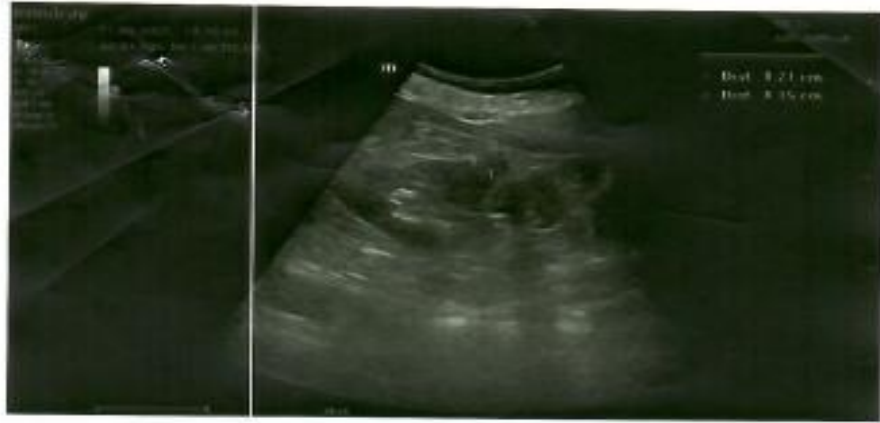Peritonitis:

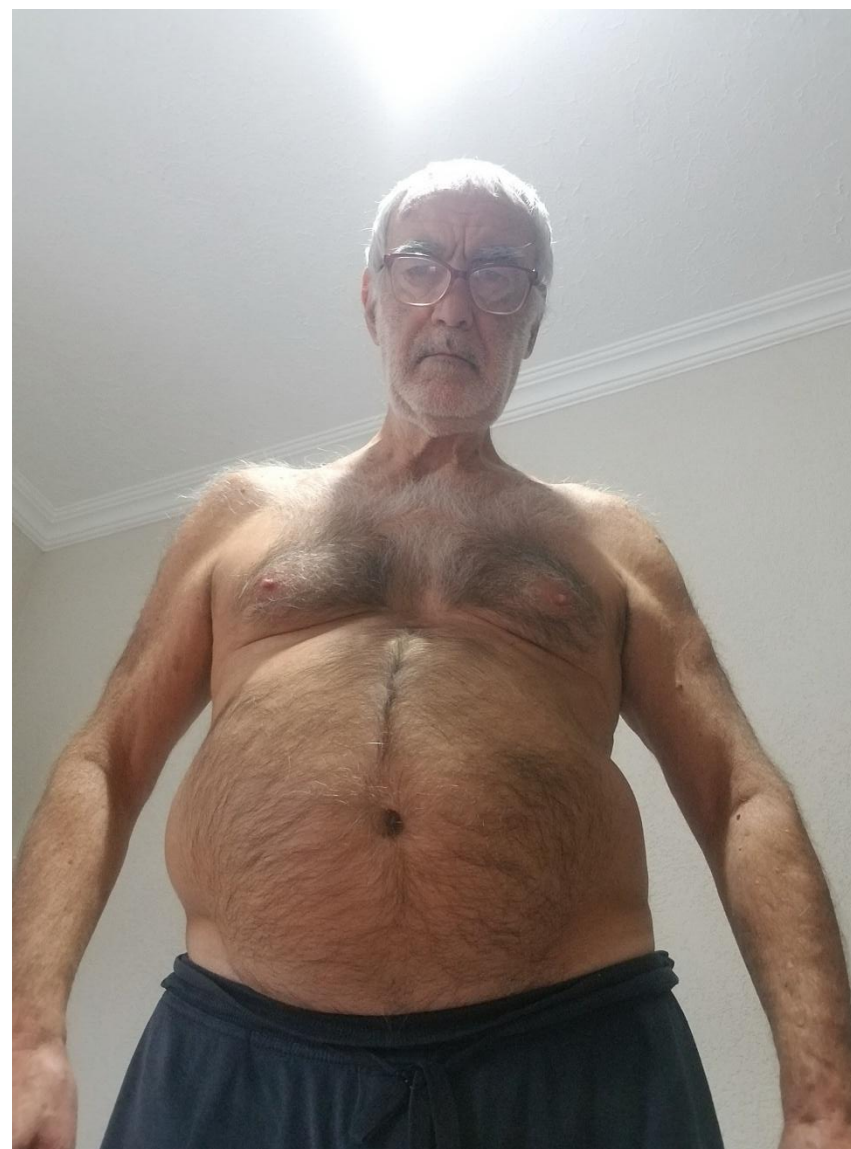One of the most serious complications associated with free air in the abdomen is peritonitis.

Peritonitis is the inflammation of the peritoneum, the thin membrane that lines the abdominal cavity and covers the abdominal organs. When free air enters the peritoneal space, it can introduce bacteria, leading to infection and inflammation. If left untreated, peritonitis can become life-threatening.

**Patient:** Medics consistently deny the presence of free air in whole abdomen and declare pneumoperitoneum. Why? Because the free air observed is not caused by perforation of intestines or colon which is often attributed to. In span of over two years the med tests never even mentioned that. So, what is causing the accumulation of free air in abdomen outside the intestines complained for over two years in a row? The answer was there for two yrs in row given by the victim himself and deliberately ignored and moreover used to attack him and call him names.

Acoustic DEWs have been the answer all along and denied by the med terrorists fervently. The Affidavit above and evidence below have proven that solid fact beyond shadow of doubts. Based on whole body of evidence presented here and beyond a forensic med expert can confirm it, a LE investigator can confirm it, a Lay person can confirm it, even open AI Artificial Intelligence can confirm it, which by the way it did confirm it 2 wks ago of what the victim has known reporting for 2yrs.

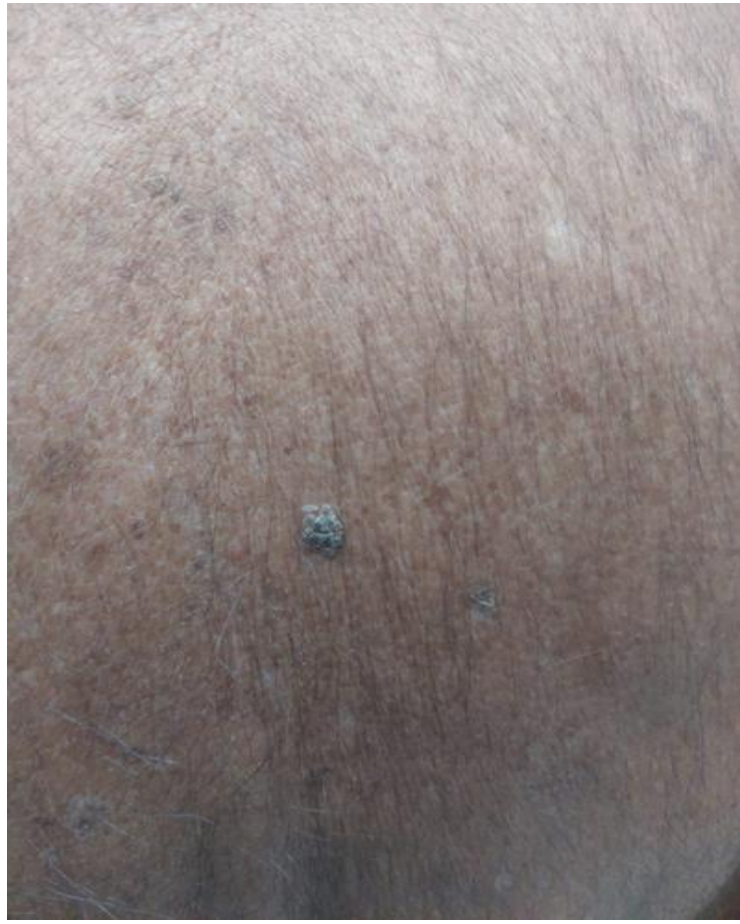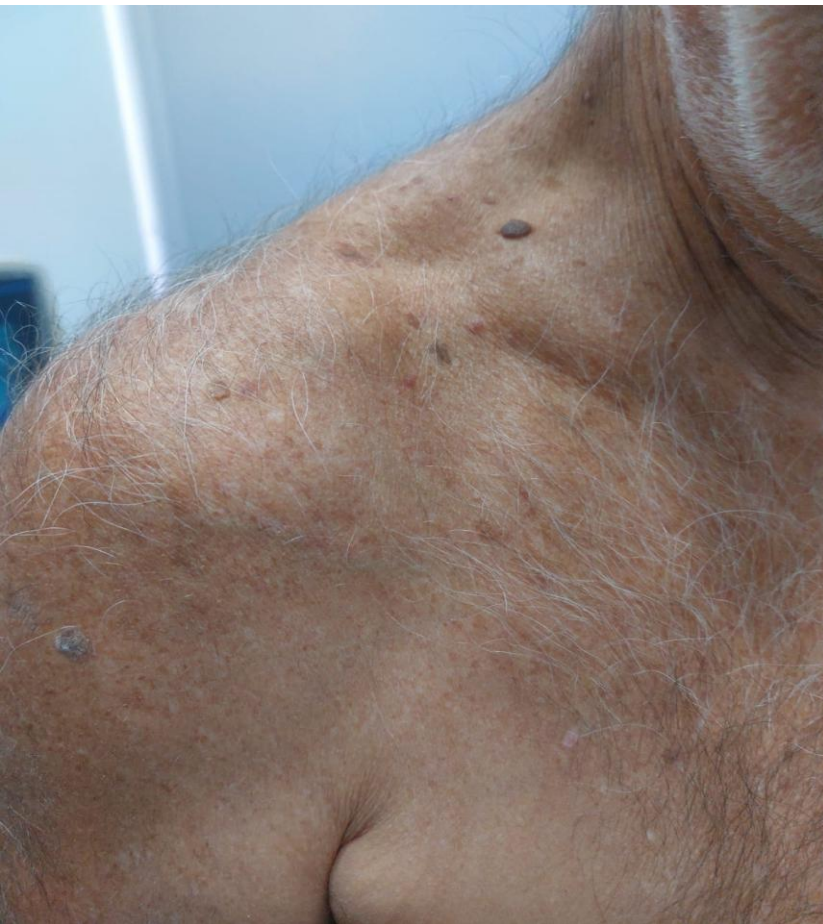

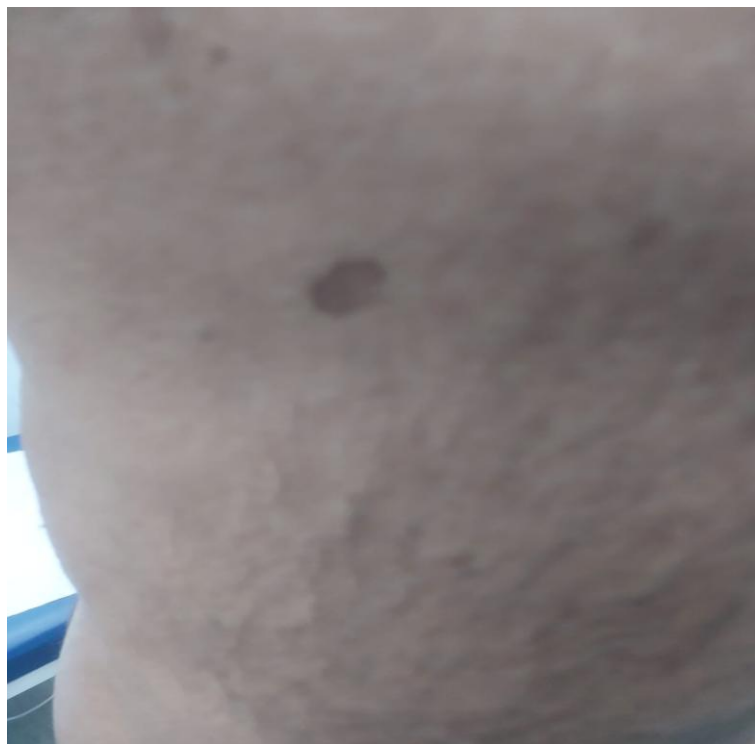
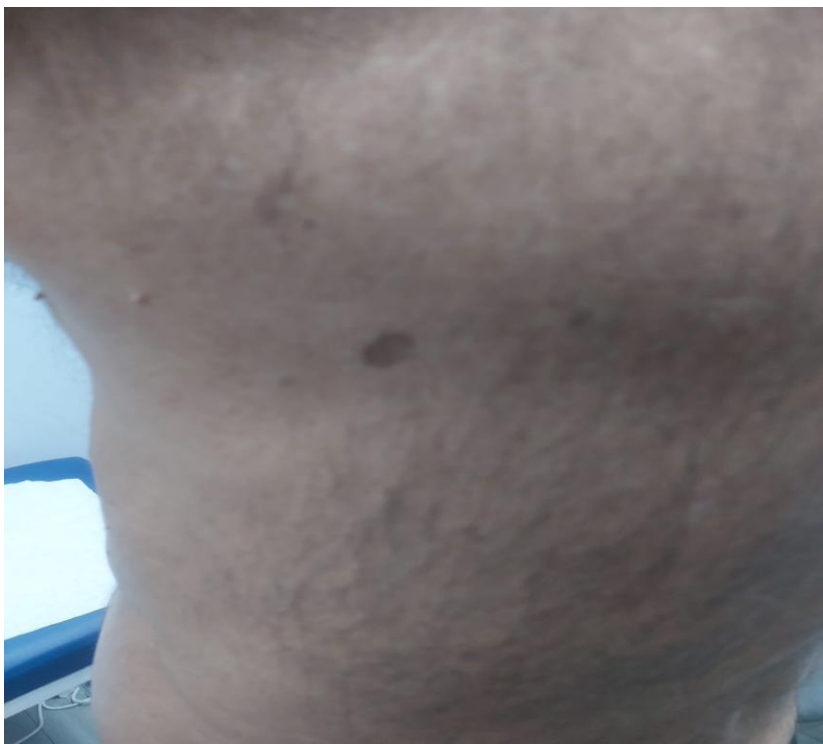

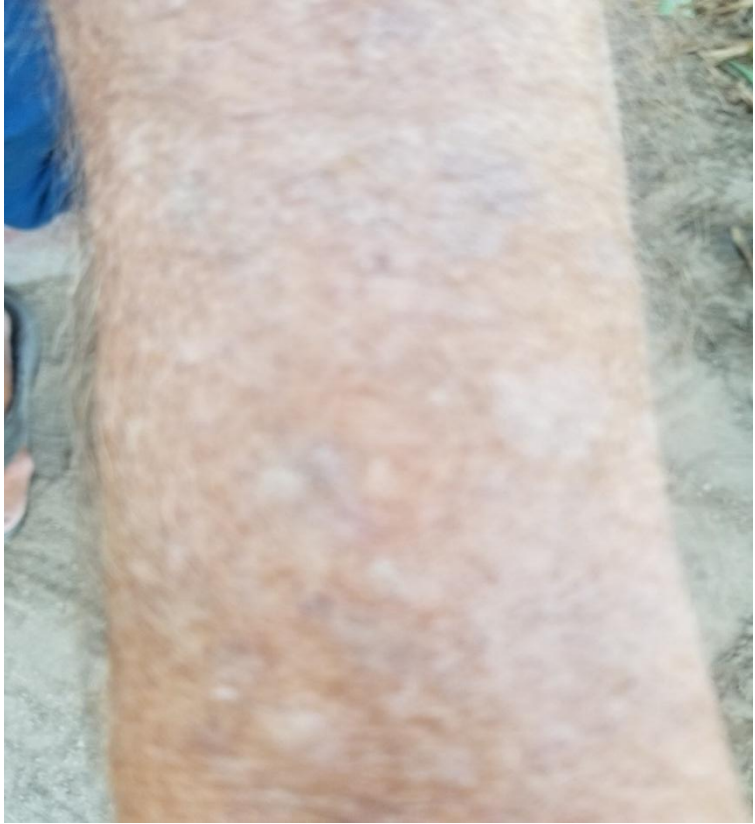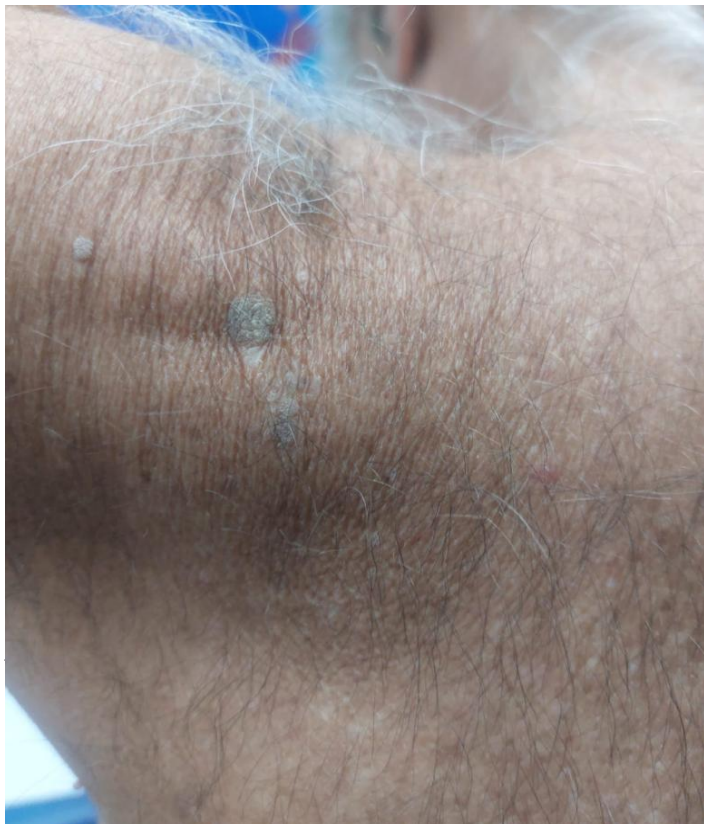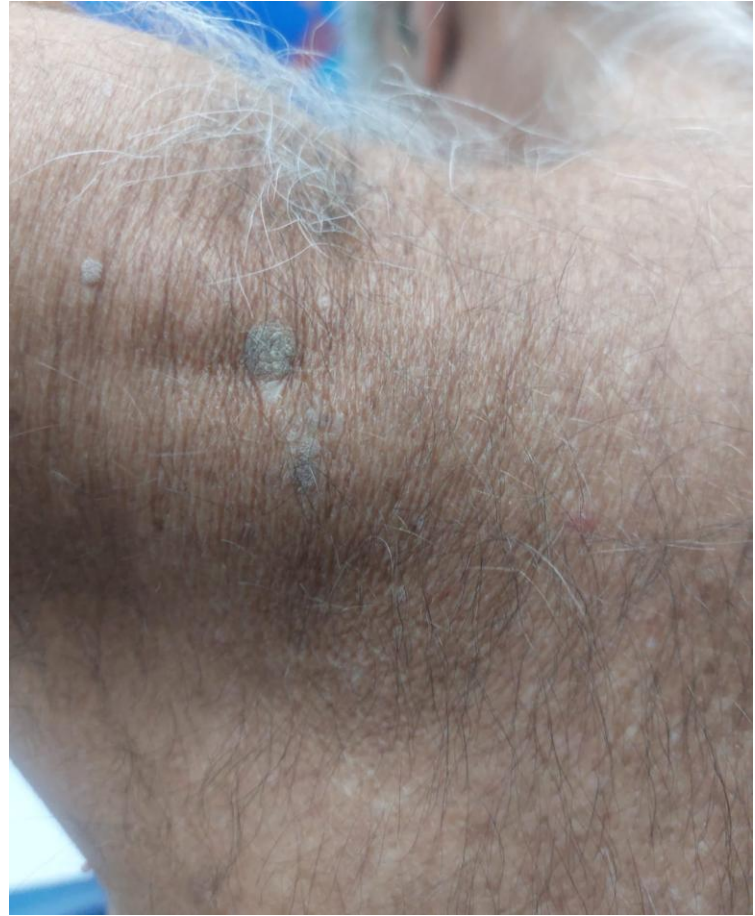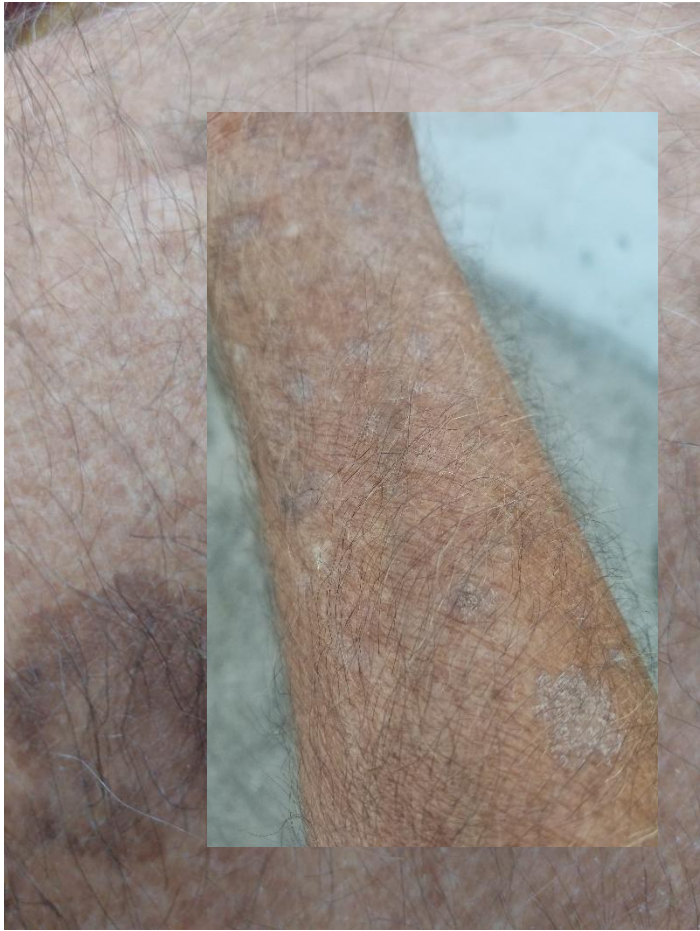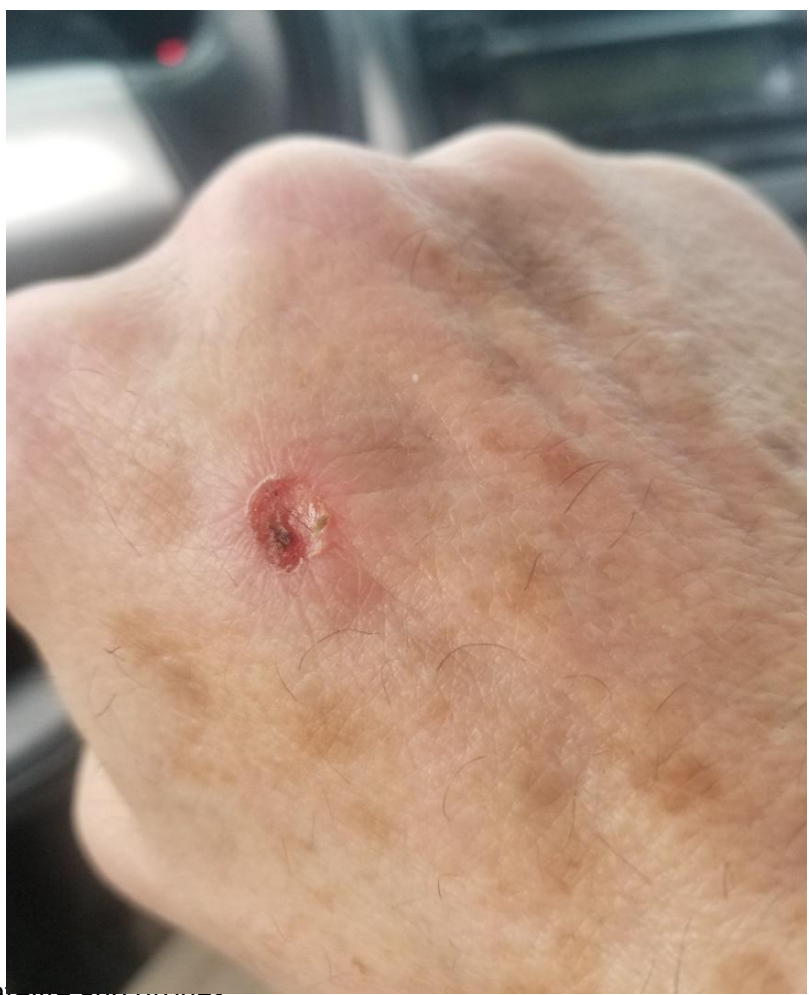Abdominal Distention caused by accumulation of Free Air intraperitoneal and Intestinal and air accumulation inside the fluid rich soft tissues abdominal organs due to the instant and inertia cavitation<sup>17</sup> shockwave effects caused by Infra and or Ultrasound Acoustic DEWs Direct Energy Weapon firing and constant acoustic hotel room radiation. Which explains the tenderness, pain and swelling of every soft tissue rich in fluid internal abdominal organs, abnormal tests and the extensive listed symptomologies listed above. The richest in fluid Liver and Kidneys are the most injured and painful organs undergoing repeated Cavitation Vivisections and most underreported and concealed by the medical criminals accomplices. Soft tissues Cavitation Injuries Vivisections are not only limited to abdominal organs it includes fluid containing painful swollen gums, eyes-painful blurred vision, brain-headaches, hissing buzzing in ears, cognitive impairment, brain damage, others.

---

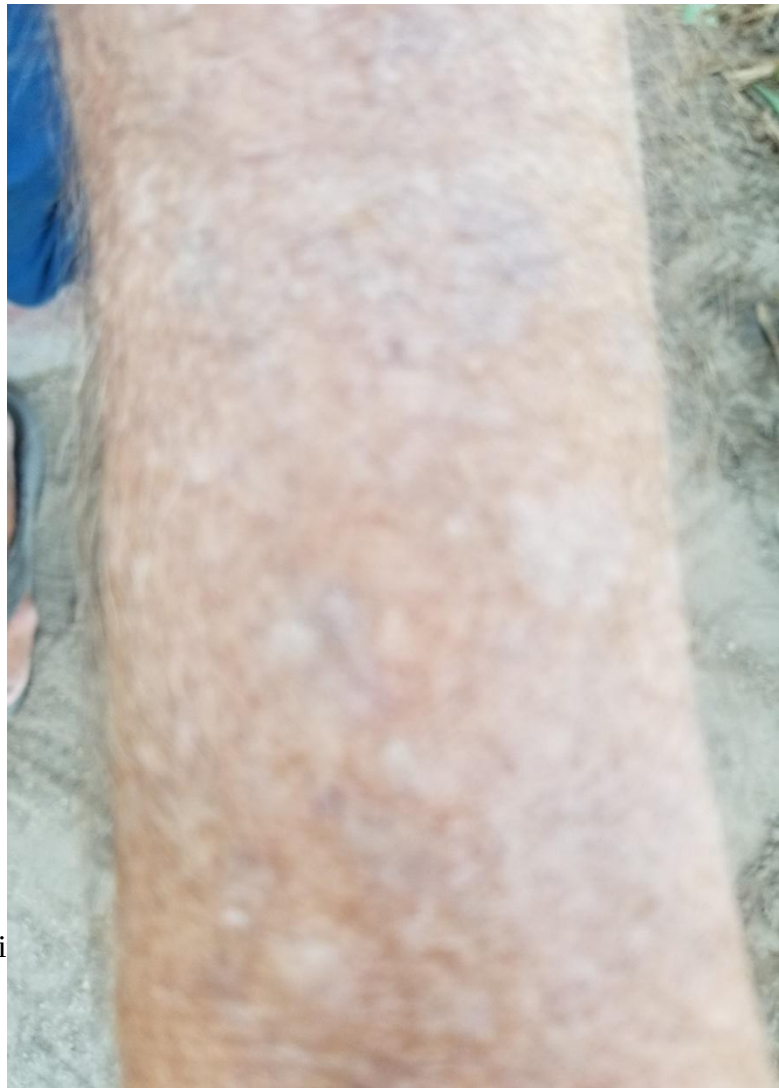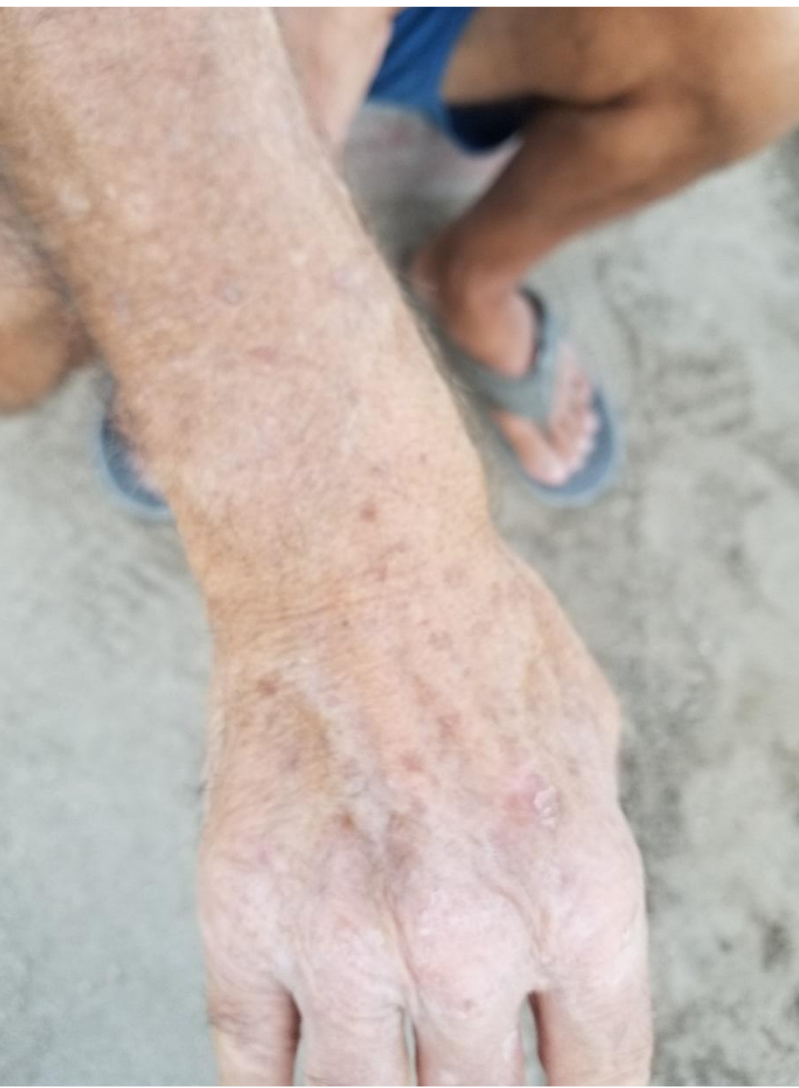<sup>17</sup> Health Effects of Exposure to Ultrasound and Infrasound  
[https://assets.publishing.service.gov.uk/media/5a7dfba8ed915d74e33ef48e/RCE-14\\_for\\_web\\_with\\_security.pdf](https://assets.publishing.service.gov.uk/media/5a7dfba8ed915d74e33ef48e/RCE-14_for_web_with_security.pdf)  
DEWs Torture Affidavit



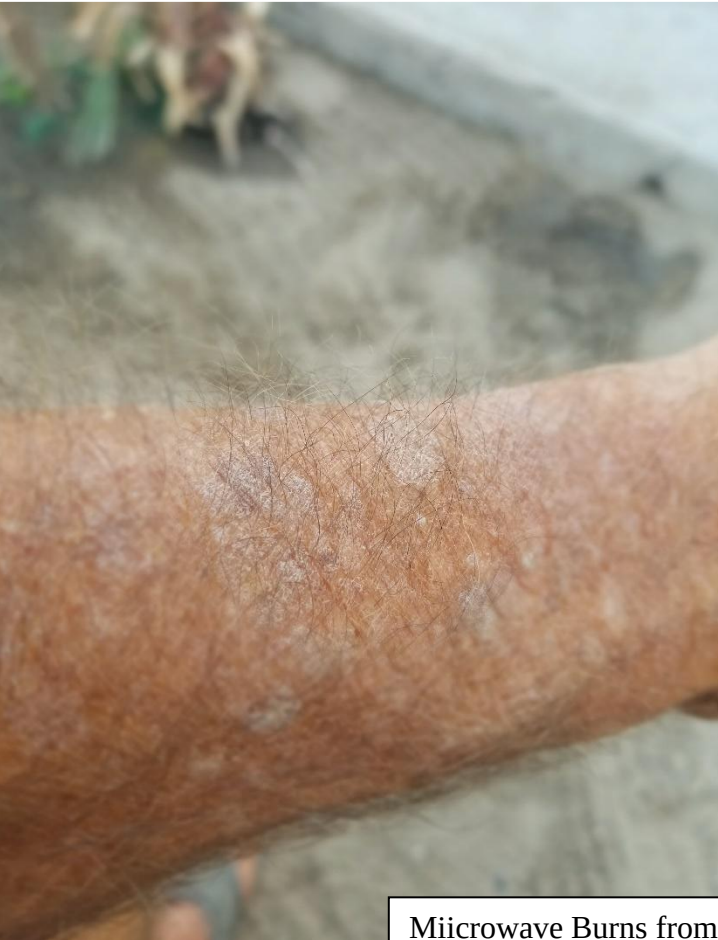



Microwave Burns from beamforming celltowers, satellite and drones

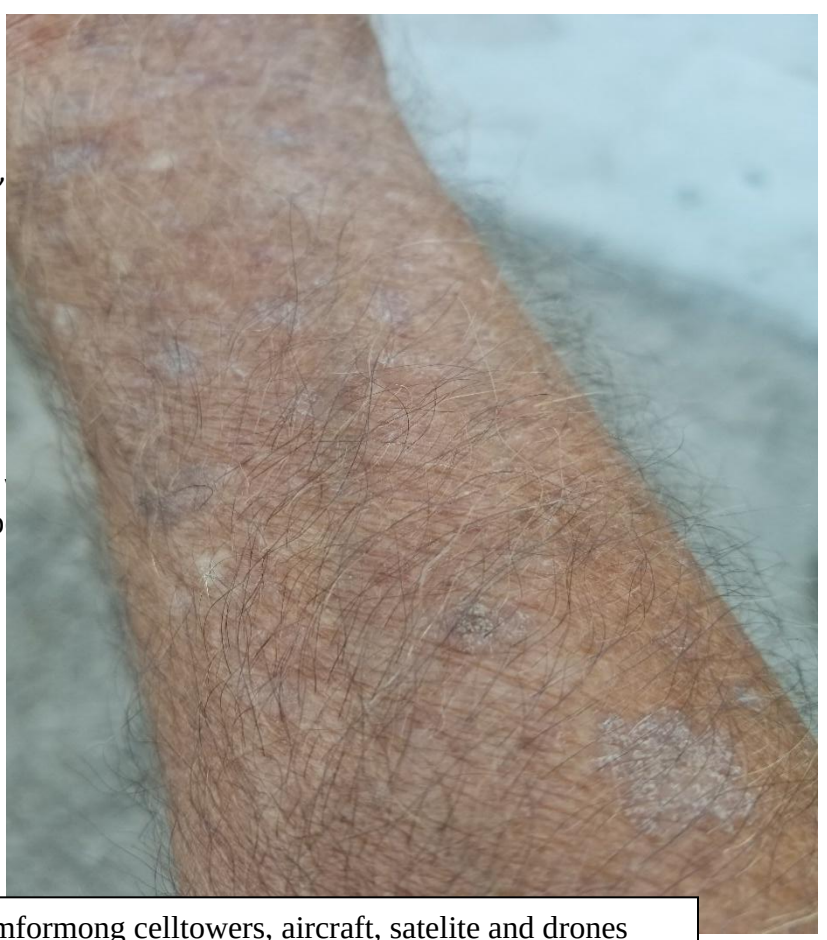

davi

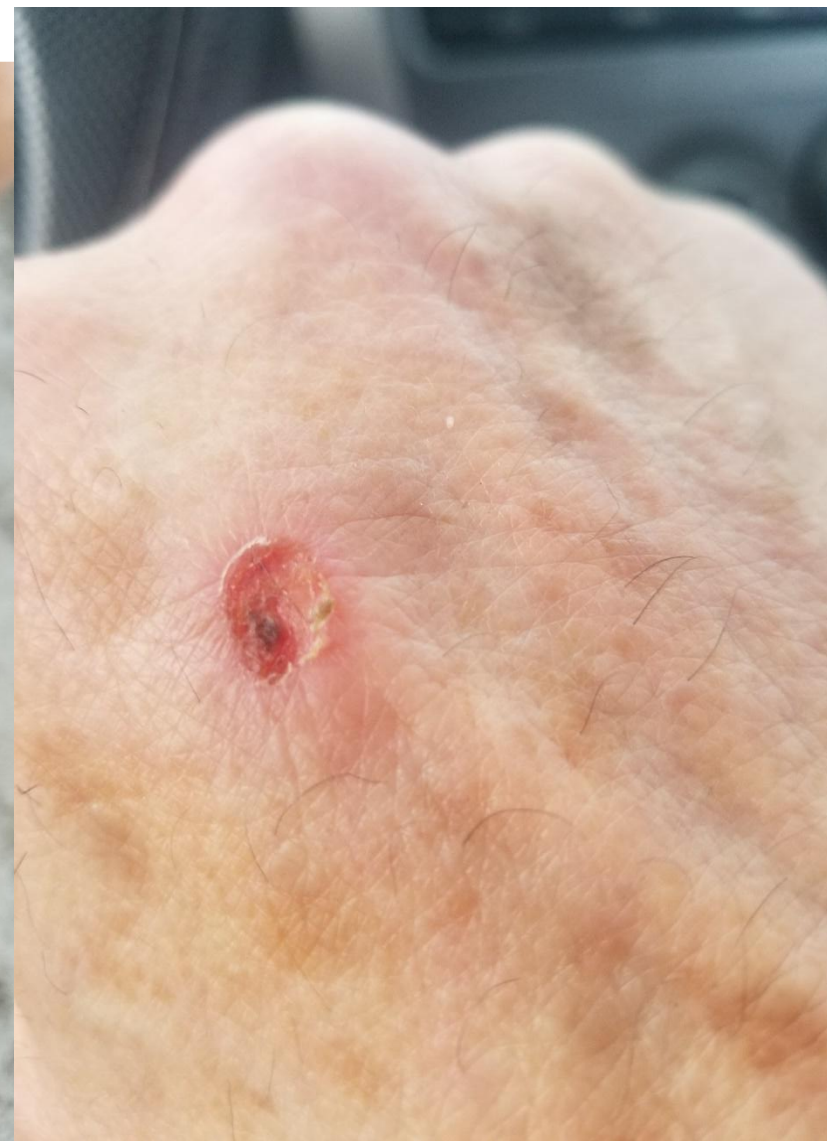
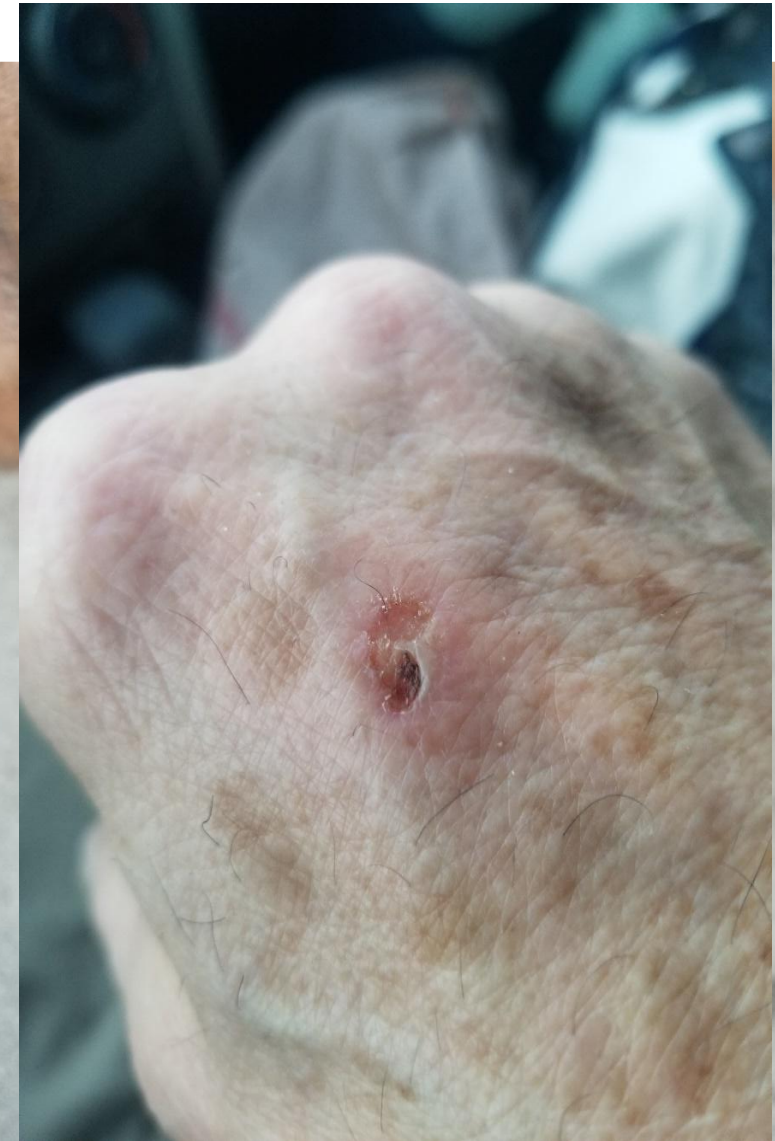
wers,

wers  
Grab  
key p



Miicrowave Burns from beamformong celltowers, aircraft, satelite and drones



**Same similar situation took place at AMC private clinic** where incompetent general practitioner Dr. Leila Jikhashvili issued incomplete false diagnosis based on incomplete and falsified diagnostic tests. While she did physical exam and witnessed herself the free air<sup>18</sup> in whole abdomen including under diaphragm she ignored all my listed symptomology in the above Affidavit, and previous medical history consistent with my symptomologies, the supporting med science and the AI Artificial Intelligence Confirmation Assessment of my injuries, and declared all is normal. She couldn't explain my question if everything is normal and the air was present un the intestines only, then why my abdomen is swollen distended 2.5 times the normal size, and if the air was present only in the intestines not the whole peritoneal cavity as is the case, then why the Ultrasound Radiologist did not report intestines size 2.5 times the normal. Her reply was that of a stare of deer staring at car's bright headlight. Incidentally the Radiologist Team consisting of the examiner Dr. Manana Mikeladze and sitting at desk Assistant Stenographer did the Ultrasound Exam for over half an hour which was unprecedented considering all Ultrasound exams over dozen I had in the past 3 yrs were 10 minutes or less and done normally by one person technician only, and never two persons. Dr. Manana Mikeladze was dictating to her Stenographer every abdominal finding injuries pathologies in minute details for extremely long time. Why, I, the paying patient, was not provided with the intricate details of the long written typed laptop med report by the assistant Stenographer? Was this detailed pathology hidden from the victim extensive Ultrasound report requested and forwarded by the Deep State unconvicted terrorists so they can use the hidden from the patient raw true untampered med data to recalibrate the torture parameters? Was it to prevent minimize the risk of sudden death from ruptured organs which would have vindicated the patient's 2yrs of complaints reporting acoustic microwave DEWs torture of ongoing homicide causes. As a 2yrs victim of daily DEWs firings, I can confirm the perps are running well greased operation using precisely calibrated DEWs parameters which are rarely exceeded. Designed not to kill you but not to keep comfortable either, but to torment you, torture you which affects whole body systems and evidence itself in expressed body organs health injuries. But lately after breaking the long-kept secret about acoustic DEWs wide open as victim whistleblower, now they are going for the kill by raising the intensity/parameters of the DEWs attacks. That's when the second part of DEWs electronic torture operation SAP program comes into play. Being under total global satellite surveillance, by all means including personal electronic devices, GPS car tracking, DNA resonance, bots, drones tracking, others, the terrorists go beforehand, flashing their false gov credentials go before their victim's arrival into the med institution he is heading to, and bribe, pressure or both the med hierarchy to deny the patient victim of any med evidence of DEWs induced physical trauma which criminal med cover up I witnessed in almost every med facility in every country. Due to this organized systemic medical and Deep State operatives conspiracy my constitutional human rights have been reduced to that of laboratory animal where the terrorists execute the DEWs torture systemically and methodically and the true lab results health effects of torture experiment are dutifully forwarded by the med terrorists abettors of the heinous unfolding crime, not to the patient victim, but to the perps running the SAP<sup>19</sup> program. The victims only get the crumbs of the table-tampered med tests or no results, false med made up diagnoses and malicious unrelenting attacks of patient credibility and ala school bullying name calling. **The medical**

---

<sup>18</sup> The presence of free air in the abdomen is a medical emergency that typically requires surgical intervention while air in the intestines is simply part of normal digestive function.

<sup>19</sup> SAP Special Access Program the Air Force Special Access Program (AF SAP)

**accomplices deserve double punishment of that of the terrorists.** They are consistently sneakily protecting the criminals by denying the victim conclusive med evidence of the crime thus removing any fighting chance for him to submit criminal complaint med evidence of the serious health injuries trauma incurred to Law Enforcement LE or courts to ask for protection and relief. In effect the med practitioners turned med terrorists give a green light go ahead continue what are you are doing, we got your back, at each med ER patient victim's financed visit. They have betrayed public trust in the med institutions which is an aggravating factor. This should make every normal reasonable human being's blood boiling in outrage revulsion and disgust. Also, the gruesome daily torture of causing acoustic DEWs induced daily microcell surgeries vivisections repeatedly on the same injured abdominal rich in fluid organ(s) over and over again, cutting the same injured cells repeatedly, especially the kidneys which have the weakest tensile strength and rich in fluid. **Thus, my abdominal organs due to daily repeated vivisections<sup>20</sup> microcells surgeries with cavitation micro air vapor bubbles serving as a microscalpel rot slowly inside my abdomen** causing high abnormal VS, CPs, kidney back pain, thin stream, dripping, painful burning incomplete urination, high level of physiological stress, cognitive impairment, blurred vision, whole body pain, malaise and 24/7 daily suffering, creating living state of morbidity. In addition, I am being microwaved in my hotel room 24/7 seeded with cancer, causing burns in throat lungs brain, whole body pain, skin conditions burn, liver damage<sup>21</sup>, scarring and many other ill effects. I am living in a prison Abu Ghraib radiation torture chamber without walls and privacy. Being part of the IOB Internet of Bodies tracked 24/7 by DNA resonance frequencies, and other means from satellites, drones, microwave beamforming cell towers, gangstalkers and fired upon repeatedly with DEWs. This is the Legacy of the Deep State unconvicted terrorists, indescribable evil and horror exceeding that of the nazis.

---

<sup>20</sup> See ><https://chemtrails.substack.com/p/big-pharma-bloodlust-monsters-in>< “Those Satanic Rituals called Vivisections These experiments, if you could call them that, served no purpose other than to fulfil the need for bloodlust and desire to watch a creature cry in pain and beg for mercy.”

<sup>21</sup>Very high triglycerides levels and this abnormal Lipid Panel test results, liver swelling, pain, tenderness is consistent with chronic microwave radiation exposure.

Surname	Dermendziev	Name	Dimitar Konstandinov	Date	13.12.2025
DOB	29.02.1956	E-mail			
Telephone		Invoice No:		<b>Dr. Leila Jikhshvili</b>	

**CONSULTATION RECORD**

<b>Allergies</b>	<b>NKDA</b>
History of Problem	The patient complains about the abdominal pain, discomfort and meteorism especially after consuming the food and drinks. From the scale of 10 the pain level is 4-5 points. Periodically, constipation and frequent urinating. Also, teeth loosening and gum pain. Sleep is normal. The patient is sure that all these problems are caused by the CIA system and the patient thinks that he is the victim of the USA CIA system that's why he thinks that ultrasounds and MRI informations are fake. The patient was undergoing treatment in USA and Mexico but he thinks all the reports and treatments there were fake. The patient has thoughts that no matter where he goes for treatment including our clinic is connected to the CIA and none of the treatment is right for him.
Examination	<p>1.GP Consultation</p> <p>BP-160/110; T-36.5; HR-74; Spo2-99%; Skin is normal , seb.keratoses are seen. Sizes approximately 1.0 x 0.5 cm , 0.5x0.5 cm. covered with scales, no pain. ENT- palatal without the pathology. Few teeth are missing. Lymph nodes are without pathology.</p> <p>Heart-rhythmic tones, Lungs-vesicular breathing on both sides. Abdomen-soft , with percussion Timpanic sound . Muscle skeleton system without pathology. The patient notes constipation and he controls it with healthy food.</p> <p>The following analysis were done:</p> <p>CBC , glucose, urinalysis, creatinine, urea, Alt , Ast, Lipid panel, C reactive protein, cortisol due to the patient request. Abdominal and present gland Ultrasound.</p>
Treatment	<ol style="list-style-type: none"> <li>1.Kreon 25000 three times a day for a month.</li> <li>2.Espumisan 2 caps three times a day for 10 days.</li> <li>3.Physical activity , healthy lifestyle.</li> <li>4.In three months lipid profile repeated analysis.</li> <li>5.Urologist consultation</li> <li>6.Psychiatrist consultation</li> </ol> <p>The patient refused the treatment because the patient thinks that the medications and traditional medicine are connected to the CIA system.</p>
Diagnosis	<p><b>K59.9 Functional intestinal disorder, unspecified</b></p> <p><b>R14 Flatulence and related conditions</b></p> <p><b>E78 Disorders of lipoprotein metabolism and other lipidemias</b></p> <p><b>N40 Hyperplasia of prostate</b></p> <p><b>I10 Essential (primary) hypertension.</b></p>

## Email reply

You have shamelessly provided 3 pgs false and incomplete Medical Report that protects the Deep State unconvicted terrorists criminals and given to them a green light to continue torturing the victim to death with their DEWS-Direct Energy Weapons and punished the victim all over again just like in previous corrupt med institutions at other countries.

1. The few horrific med test numbers were altered and incomplete and were not representative of the serious crime induced underlying injuries while being charged with 1401.04 Gell. There were no lab results for urine color, PH, spec gravity, bacteria, crystals in urine and many other urine tests markers showing chronic kidney dysfunction, infection, backache kidney pain, burning urinary tract pain. Only nine tampered results cherry-picked tests were shown even though I had requested full panel liver and full panel kidney tests. The incomplete false made up narrative did not include finding for massive free air present in abdomen and abdominal organs, abdominal distention, kidney infection, kidney cysts, scar tissues, organs size comparison with old ultrasound report, and other observed pathologies which were observed and recorded by MDs in other countries and which reports you completely ignored to support your cover up of the crime scene. Incidentally BMC Urologist Dr. Gela Lomadze who did the complete physical abdominal exam and refused to lie issue false diagnosis, was replaced week later with Dr. Mzia Didmandze who refused to do physical exam and willingly lied by omission.
2. You completely ignored the three-page signed factual Affidavit of Torture that was replete with extensive symptomology and med science abstract that should have indicated the necessary tests and med facts-based diagnosis. You did not follow med protocol directing to exclude all causes before diagnosing meteorism. Your false made up cooked up med diagnosis omitted my chief complain painful kidney backpain area, painful dripping urination, blurred vision
3. Since Dec 13, 2025, Sat. initial visit, you spent 7 days "cooking" falsifying the med report which is unprecedented.
4. Another proof showing intent to cover up the med evidence of the heinous crime is the made up by you story a figment of your imagination comprising 80% of the History of Problem section. In it the word CIA was mentioned four times falsely attributing to me, while it was never mentioned in my 3pgs Affidavit. It was a cheap sneaky attempt to shift the focus from the serious crime induced painful injuries symptomologies to the nonexistent credibility issue.
5. Another proof showing intent to cover up the crime scene is her sanitizing Radiologist finding of "A 9mm incision made into the bladder lumen" with the phrase "A bilobed node measuring 22 X 20 mm is visible in the apical part. It invades in the lumen of bladder with 9 mm". During violent cavitation process when mechanical pressure, shear force, heat, free radical are released a large cavitation bubble is capable to cause deep cuts incision which is consistent with the triage above and victim's complaint of kidney area pain 4/10 to 5/10 which she sanitized it with abdominal pain. She is completely paranoid about anything that has to do with the kidney's pathology.
6. Another proof showing intent on covering up the crime scene is her completely ignoring the AI - Artificial Assessment report that triaged the victim/patient extensive symptomologies injury, with the solid medical science and physics, supported with prior med evidence that explained eloquently the mechanism of acoustic action injury effects on soft tissues organs rich on fluids. As a biased conspirator, she never even attempted to make that solid connection like for example consuming food, drinks, rehydration, or taking hot shower increases dramatically the cavitation process and subsequently the pain and abdominal swelling, while cold shower, dehydration decreases the cavitation and pain.

7. Another proof showing intent to cover up the crime is attacking indirectly the injured patient's credibility. Even though the victim is not medical professional, habitual liar, criminal psychopath, lying for a living, she had the audacity to refer him to Psychiatry, a modern form of witchcraft, not backed by solid science, only malicious name calling.

8. Even though she was advised warned several times orally and in writing that covering up the med evidence of a crime is a crime in itself and is punishable by death according to international laws, she recklessly proceeded to do exactly just that, thus knowingly and intelligently willingly becoming shameless participant coconspirator in the crime of physical torture to death.

9. You failed to provide the 3pgs Radiologist ultrasound report in English, and copy of the Intake/Consent report and the diagnosis report in Georgian which I ask for now.

In Conclusion in your rush to protect the Deep State unconvicted terrorists and the corrupt BMC at the expense of the gravely injured 70 yrs old peaceful law-abiding exemplar American tourist/victim's health and life, and your credibility and legal standing, and by concealing all med evidence you have knowingly willingly intelligently committed the crime in same footings as the terrorists of physical torture to death for which you are legally and morally liable. Your pathological immoral obsession to hide the extent of kidneys and other organs fatal gruesome injuries thus violating public trust in medical institutions constitutes an unofficial illegal death sentence for the patient who has no ammunition to fight and expose the murderous terrorists. If you have any ounce of consciousness, dignity and shame, human compassion, I strongly urge you to exercise it, admit your wrongdoing, report the real injuries med evidence to the authorities and reveal the individuals that induced you to commit crime. And be reassured no one escapes justice neither man's nor God's Justice. GITMO and military tribunals are opened to receive kidnaped international terrorists. If you think you and your fellow accomplices are above reproach, think again, no one is above the law including kidnaped foreign terrorists.

Sincerely, Dimitar Dermendziev

13/12/2025



სახელი, გვარი - დიმიტარ დერმენდზიევ ასაკი - 69 წლის

**მუცლის ღრუს ულტრაბგერითი კვლევა**

ღვიძლის ირიბი-ვერტიკალური ზომა 140 მმ (N=max 140 მმ-150 მმ)  
 კრანო-კაუდალური ზომა შუა ხაზზე 85 მმ (N=max 100 მმ)  
 წინა-უკანა ზომა შუა ხაზზე 60 მმ (N=max 60 მმ)  
 ღვიძლის ქვედა კიდე მამილარულ ხაზზე ნეკნთა რკალს არ სცილდება.  
 ღვიძლი ზომამი - არ არის გადიდებული. კიდეები - სწორი.  
 კუთხეები - მახვილი. ღვიძლი- პარენქიმა - ჰომოგენური.  
 სტრუქტურა - წერილმარცვლოვანი. ექოგენობა - ზომიერად მომატებული.  
 ექოგამტარიანობა - შენახული. სისხლძარღვოვანი სურათი - უცვლელი.  
 კარის ვენა ინტრაჰეპატურად - 10 მმ.  
 ღვიძლის ვენები და ქვემო დრუ ვენა გაფართოებული არ არის.  
 პორტული ჰიპერტენზია - არ ელინდება.  
 ღვიძლშიდა სანადლე გზები დილატაციის გარეშე.  
 ნაღვლის საერთო სადინარი - 5 მმ. დილატაციის გარეშე.  
 ნაღვლის ბუშტი ზომით: 69 X 19 მმ. საშუალო ზომის.  
 ნაკვეთი შუა მესამედში კედლის სისქე - 3,8 მმ.  
 დრუმა - საშუალო რაოდენობით ნალექი.  
 პანკრეასი ზომით : თავი 22 მმ, სხეული 11 მმ, კუდი 21 მმ.  
 ექოგენობა - ზომიერად მომატებული, სტრუქტურა - ერთგვაროვანი;  
 ვირსუნგის სადინარი დილატაციის გარეშე.  
 ელენთა ზომით : 94 X 38 მმ, ექოგენობა - ზომიერი.  
 სტრუქტურა - ჰომოგენური, წერილმარცვლოვანი. კონსტური - სადა.  
 ელენთის ვენა კარში 6 მმ.

13/12/2025



სახელი, გვარი - დიმიტარ დერმენდზიევ ასაკი - 69 წლის

**წინამდებარე ჯირკვლის ულტრაბგერითი კვლევა**

წინამდებარე ჯირკვლის ზომები: 46 X 41 X 44 მმ მოც: 44 სმ<sup>3</sup>.  
 ზედა მესამედში კონტურები - სუსტად უსწორი, მკაფიო საზღვრებით;  
 ექოგენობა - ზომიერი, სტრუქტურა - ერთგვაროვანი.  
 აღინიშნება შუა წილის ჰიპერპლასია.  
 აპიკალურ ნაწილში ისახება ორწილიანი კვანძი ზომით 22 X 20 მმ.  
 შტრილია შარდის ბუშტის სანაოურში 9 მმ-ით.  
 შარდის ბუშტი - არასკმარისი ავსების, შიგთავსი - ერთგვაროვანი.  
 ნარჩენი შარდი - 13 მლ-მდე.

ექიმი-რადიოლოგი - მანანა მიქელაძე;  
 ხელმოწერა -



**"A 9mm incision made into the bladder lumen"**

მუცლის ღრუში თავისუფალი სითხე არ ისახება; ნაწლავებში აირების მკვეთრი მოჭარბება.

მარჯვენა თირკმელი ზომით: 111 X 54 მმ.

პარენქიმის სისტე შუა სეგმენტში 18 მმ.

მენჯ-ფიალოვანი სისტემა დილატირებული არ არის.

კორტიკო-მედულური დიფერენცირება კარგად გამოხატულია.

მარცხენა თირკმელი ზომით: 110 X 54 მმ.

პარენქიმის სისტე - 18 მმ.

შუა მესამედში, კერძოდ პარენქიმამი - შემაერთებელი ქსოვილის დეფექტი.

მენჯ-ფიალოვანი სისტემა დილატირებული არ არის.

კორტიკო-მედულური დიფერენცირება კარგად გამოხატულია.

ორივე თირკმლის მენჯ-ფიალოვან სისტემაში - ერთეული ექოპოზიტიური (კრისტალური) ჩანართები.

ექიმი-რადიოლოგი - მანანა მოქლაძე;

ხელმოწერა - 



Name: Demendzhev Dimitar Kostandinov  
Age: 69  
Test Date: 15.12.2025



Test Name	Result	Unit	Normal ranges
Cortisol	24.23	µg/dL	10 o'clock 4.3-22.4 16oclock 3.09-16.7
CRP Hi sensitive	1.36	Mg/L	0.00-3.00
AST	18.58	U/L	15.00-37.00
ALT	25.45	U/L	14.00-63.00
Urea	15.96	Mg/dL	15.00-38.50
BUN	7.46	Mg/dL	7.00-18.00
Creatinine	70.81	µmol/L	62.00-115.00
GFR	97.00	ml/min	58.00-110.00
Glucose	5.30	mmol/L	3.30-5.50

Full Name: **Dimitar Kostadinov  
Demashkiy**  
DOB: 29.02.1956  
Test Date: 13.12.2025



### Present Gland Ultrasound Examination Report

**Prostate dimensions:** 46 X 41 X 44 mm Volume: 44 cm<sup>3</sup>.

Contours in the upper third - slightly irregular, with clear boundaries.

Echogenicity - moderate, structure - homogeneous.

Hyperplasia of the middle lobe is noted.

A bilobed node measuring 22 X 20 mm is visible in the apical part. It invades in the lumen of bladder with 9 mm.

Bladder - insufficiently filled, contents - homogeneous.

Residual urine - up to 13 ml.

Dr.Manana Mikeladze

Sanitized Urine Test-color Yellow, Appearance-Mirky, 12 out of 34 tests are shown here only. WHY? Numbers are not shown, bacteria



პლაზმა - კლინიკა & ლაბორატორია  
 ბათუმი, ჯავახიშვილის 19ა  
 plasmabatumi@gmail.com  
 +995 568 10 44 10  
 plasmabatumi

Bacteria, all kinds of crystals, salts, Hyaline Casts, not shown, deliberately omitted to hide kidneys damage. BMC did 34 urine tests, AMC only 12, BMC total charge 454gel, AMC 1401gel.

გვარი, სახელი:	DERMENDZIEV DIMITAR KOSTANDINOV	Surname, Name:	DERMENDZIEV DIMITAR KOSTANDINOV
პირადი/ID:	A32933547	ტელ/Tel:	
დაბ.თარ./DOB:	29.02.1956	ასაკი/Age:	69 წ.
ისტ. N:	PL25/18116	სქესი:	მამრ.

რეგისტრაციის თარიღი: 15.12.2025

URINALISYS შარდის საერთო ანალიზი

მაჩვენებელი	Parameter	შედეგი Result	ერთეული Unit	ნორმა Range
ფერი	Color	ყვითელი	-	ყვითელი
გამჭირვალობა	APPEARANCE	მღვრიე *	-	გამჭირვალე
ხვედრითი წონა	SG	1.01 ↓	-	1.015 - 1.025
PH	PH	8	-	4.6 - 8
ლეიკოციტები	LEU	neg	Leu/μL	< 10
ნიტრიტები	NIT	neg	-	neg
ცილის განსაზღვრა შარდში	PRO	neg	mg/dl	< 30
გლუკოზა	GLU	norm	mg/dl	< 50
კეტონები	KET	neg	mg/dl	< 15
ურობილინოგენი	URO	norm	mg/dl	< 1
ბილირუბინი	BIL	neg	mg/dl	neg
ერიტროციტები	ERY	neg	Ery/μL	neg

Since Dec 13, 2025, Sat. initial visit, the doctor spent 7 days “cooking” falsifying the med report which is unprecedented. Instead to be given diagnosis and tests results within 2 days max I waited whole wk making repeated requests for the med reports. The whole thing is a cruel joke and fragrant violation of patient’s and human rights.



Urine Test 1



+995 (32) 250 20 77  
 batumi@amcenters.com  
 www.amcenters.com  
 114 Zurab Gorgiladze Str.  
 Batumi, Georgia 6000

**INVOICE DATE** Dec 13, 2025  
**INVOICE NUMBER** BAT131.2252  
**PATIENT** Dimitar Kostadinov Dermendziev  
**DOB** Feb 29, 1956  
**TOTAL EUR** 442.80

**DIAGNOSIS:** Functional intestinal disorder, unspecified, Flatulence and related conditions, Disorders of lipoprotein metabolism and other lipidemia, Hyperplasia of prostate, Essential (primary) hypertension

Date	Doctor	SERVICE	QTY	UNIT PRICE, EUR	PRICE, EUR	PRICE, GEL
					EXCHANGE RATE	3.1640
Dec 13, 2025	Lelia Jikhshvili, MD Nurse	Primary Care Level 2	1	€ 85.00	€ 85.00	GEL 268.94
		CBC	1	€ 27.00	€ 27.00	GEL 85.43
		Creatinine	1	€ 19.00	€ 19.00	GEL 60.12
		Glucose	1	€ 21.00	€ 21.00	GEL 66.44
		UREA	1	€ 20.00	€ 20.00	GEL 63.28
		ALT	1	€ 19.00	€ 19.00	GEL 60.12
		AST	1	€ 25.00	€ 25.00	GEL 79.30
		Lipid Panel	1	€ 79.00	€ 79.00	GEL 249.96
		CRP (C-reactive protein)	1	€ 33.00	€ 33.00	GEL 104.41
		Cortisol	1	€ 69.00	€ 69.00	GEL 218.32
		Urine Analysis	1	€ 20.00	€ 20.00	GEL 63.28
		Abdominal Ultrasound	1	€ 75.00	€ 75.00	GEL 237.30
				<b>SUBTOTAL</b>	<b>€ 492.00</b>	<b>GEL 1,556.70</b>
				<b>DISCOUNT 10%</b>	<b>€ 49.20</b>	<b>GEL 155.66</b>
				<b>TOTAL</b>	<b>€ 442.80</b>	<b>GEL 1,401.04</b>

CASH € 442.81 GEL 1,401.04  
 CC  
 AR  
 INSURANCE PROVIDER  
 OTHER

*I agree that my liability for this bill is not waived and I agree to be held personally liable in case the company or its location fails to pay for any part or full amount of these charges within 30 days from the date of invoice.  
 You have signed consent for American Medical Centers Georgia Limited Liability Company to collect and disclose personal and medical data to the payor listed above, for the purposes of invoices costs related to your treatment and/or services arranged by American Medical Centers Georgia, among others, and agree to the transfer of such data outside Georgia. Pursuant to this consent, we will send this invoice containing your personal and medical data to the payor listed above, for the purposes of obtaining payments. If you wish to withdraw this consent, please contact the Clinic Manager.  
 If you have had any laboratory tests performed please be advised that the results of some tests may take up to 10 days to be returned. Test results may be communicated to you individually or when they have all been processed. If you wish to clarify when your tests will be available please discuss this with your physician or head nurse.*

Patient's Signature \_\_\_\_\_

LLC AMERICAN MEDICAL CENTERS, GEORGIA  
 BENEFICIARY'S BANK: JSC TBC BANK  
 SWIFT: TBCBGE22  
 IBAN FOR EUR: G656T87253036120800003  
 IBAN FOR GEL: GE19T87253036080100003

Your Choice for Health

We Value Your Feedback!  
 Please take a minute to rate  
 your experience at AMC



პაციენტი: დერმენდზიევ დიმიტარ  
კონსტანტინოვ  
პ/ნ: PP14-377445  
ასაკი: 69  
სქესი: კაცი  
ექიმი: ჯიხაშვილი ლეილა

**Diagnosis E78 Disorders of lipoprotein metabolism and other lipidemias**

შეგვფასეთ



ლაბორატორიული კვლევა				
კოდი	დასახელება	შედეგი	ნორმა	ერთეული
LA.212	Cortisol კორტიზოლი	24,23	10 სთ 4,3 - 22,4 16 სთ 3,09 - 16,7	µg/dL
LA.416	CRP Hi Sensitive "ც" რეაქტიული ცილა ზემგრძნობიარე	1,37	0,00 - 3,00	mg/L
LA.128	AST ასპარტატამინოტრანსფერაზა	18,58	15,00 - 37,00	U/L
LA.130	ALT ალანიამინოტრანსფერაზა	25,45	14,00 - 63,00	U/L
LX.113	Urea შარდოვანა			
	Urea შარდოვანა	15,96	15,00 - 38,50	mg/dL
	BUN(Blood Urea Nitrogen) აზოტოვანი წაერთების ცვლის პროდუქტების განსაზღვრა სისხლში	7,46	7,00 - 18,00	mg/dL
LA.170	ლიპიდური სპექტრი			
	Atherogenic index ათეროგენობის ინდექსი	0,39 ↑	0,00 - 0,21	
	Cholesterol საერთო ქოლესტერინი	204,94 ↑	0,00 - 200,00	mg/dL
	Tryglicerides ტრიგლიცერიდი	206,47 ↑	0,00 - 150,00	mg/dL
	LDL chol დაბალი სიმკვრივის ქოლესტერინი	125,56 ↑	0,00 - 100,00	mg/dL
	HDL cholesterol მაღალი სიმკვრივის ქოლესტერინი	↓ 36,59	40,00 - 60,00	mg/dL
LA.417	Creatinin კრეატინინი			
	Creatinin კრეატინინი	70,81	62,00 - 115,00	µmol/L
	GFR გლომერულური ფილტრაცია	97,00	58,00 - 110,00	ml/min
LA.072	Glucose გლუკოზა	5,30	3,30 - 5,50	mmol/L

კლინიკ „ენმედიკი“ არ იძლევა ლაბორატორიის შედეგების ინტერპრეტაციის და არ გავიხილება მკურნალობასთან დაკავშირებული საკითხები და გვიმეგობრდით Facebook-ზე Enmedic Clinic

თბილისი, ლ. მანაგაძის ქ. 3  
თბილისი, შირიან მეფის ქ. 15  
თბილისი, ლებლიანას ქ. 38ა  
თბილისი, არაყიშვილის ქ. 2  
ბათუმი, ვავახიშვილის ქ. 3

ტელ: (+995) 32 77 40 00  
www.enmedic.ge  
laboratory@enmedic.com



Name: Dimitar Dermendziev | DOB: 2/29/1956 | MRN: 200230045 | PCP: Lloyd Burgess, MD | Legal  
Name: Dimitar Dermendziev

### LIPID PANEL

Collected on April 17, 2024 2:50 PM

#### Lab tests - Blood (Blood)Results

Cholesterol  
mg/dL

Value  
167

Triglycerides

Normal range: below <150 mg/dL

Value  
412

High

HDL

Normal range: above  $\geq 40.0$  mg/dL

Value  
61.9

HDL

DESIRABLE: GREATER THAN 55 mg/dL

BORDERLINE RISK: 25 - 55 mg/dL

HIGH RISK: LESS THAN 25 mg/dL

Non HDL Chol. (LDL+VLDL)

Value  
105

Chol/HDL Ratio

Value  
2.7

LDL HDL Ratio

Value  
No value

Unable to calculate LDL/HDL ratio

Calculated LDL Cholesterol

Value  
No value

Unable to calculate LDL due to high triglyceride result.

Ordering provider: Lloyd Burgess, MD

Collection date: April 17, 2024 2:50 PM

Result date: April 17, 2024 7:11 PM

Result status: Final

Resulting lab:

SMH HOSPITAL LAB

7901 FROST STREET

SAN DIEGO CA 92123

858-939-3650

Arturo Mendoza, MD (Lab director)

05D0700681 (CLIA #)

MyChart® licensed from Epic Systems Corporation© 1999 - 2024Name: Dimitar  
Dermendziev | DOB: 2/29/1956 | MRN: 200230045 | PCP: Lloyd Burgess, MD |  
Legal Name: Dimitar Dermendziev

პაციენტი: დერმენდზიევ დიმიტარ  
კონსტანტინოვ  
პ/ნ: PP14-377445  
ასაკი: 69  
სქესი: კაცი  
ექიმი: ჯიხაშვილი ლეილა

შეგვადგასეთ



ლაბორატორიული კვლევა				
კოდი	დასახელება	შედეგი	ნორმა	ერთეული
LA.001	CBC სისხლის საერთო ანალიზი			
	ლეიკოციტები (WBC)	9,50	3,79 - 10,33	10 <sup>9</sup> /L
	ერითროციტები (RBC)	4,64	4,57 - 5,98	10 <sup>12</sup> /L
	ჰემოგლობინი (HGB)	15,20	13,90 - 17,70	g/DL
	ჰემატოკრიტი (HCT)	44,70	36,00 - 56,00	%
	ერითროციტების საშ. მოცულობა (MCV)	96,30 ↑	80,10 - 95,30	fL
	ჰემოგლობინის საშ. შემცველობა (MCH)	32,80	26,00 - 34,00	pg
	ჰემოგლობინის საშ. კონცენტრაცია (MCHC)	34,00	31,50 - 37,20	g/DL
	ერითროციტ. გავრცელების ფართი RDW	12,40	9,00 - 16,00	%
	თრომბოციტები (PLT)	228	150 - 400	10 <sup>9</sup> /L
	თრომბოციტების საშუალო მოცულობა (MPV)	7,20	5,90 - 9,90	fL
	სეგმენტბირთვიანი ნეიტროფილი (Neutrophils)	↓ 40	42 - 77	%
	სეგმენტბირთვიანი ნეიტროფილი (Neutrophils)	3,80	1,78 - 7,00	10 <sup>9</sup> /L
	ეოზინოფილები (Eosinophils)	4,4	0,5 - 5,5	%
	ეოზინოფილები (Eosinophils)	0,400	0,030 - 0,470	10 <sup>9</sup> /L
	ბაზოფილები (Basophils)	0,30	0,00 - 1,75	%
	ბაზოფილები (Basophils)	0,00	0,00 - 0,11	10 <sup>9</sup> /L
	ლიმფოციტები (Lymphocytes)	48 ↑	20 - 44	%
	ლიმფოციტები (Lymphocytes)	4,60 ↑	1,07 - 3,12	10 <sup>9</sup> /L
	მონოციტები (Monocytes)	7,3	2,0 - 11,0	%
	მონოციტები (Monocytes)	0,70	0,20 - 0,70	10 <sup>9</sup> /L
	ედ.ს (ESR)	6	2 - 25 ვესტერგრენის მეთოდი	mm/Hr

კლინიკა „ენმედიკი“ არ იძლევა ლაბორატორიის შედეგების ინტერპრეტაციას და არ განიხილება მკურნალობასთან დაკავშირებული საკითხები და გეგმიკობრდით Facebook-ზე: Enmedic Clinic

თბილისი, ლ. მანაგაძის ქ. 3  
თბილისი, შირიან მეფის ქ. 15  
თბილისი, ლუბლიანას ქ. 38ა  
თბილისი, არაყიშვილის ქ. 2  
ბათუმი, ჯავახიშვილის ქ. 3

ტელ: (+995) 32 77 40 00  
www.enmedic.ge  
laboratory@enmedic.com



კლინიკა „ენმედიკის“ ლაბორატორია არ იძლევა ლაბორატორიის შედეგების ინტერპრეტაციას. გთხოვთ, მიმართეთ მკურნალ ექიმს.

**In Final Analysis** there was plenty of evidence direct, indirect and circumstantial evidence provided here for any capable untainted LE to take immediate Law Enforcement action. While the two Batumi compromised by the terrorists clinics frantically scrambled to erase any direct proof the crime- Externally Induced Soft Tissues Organs Cavitation Injury Trauma, turned into physical repeated daily torture, in this very process they provided the burden of proof necessary to pursue LE action. Their transparent organized methodical attempts to do so by concealing, falsifying, tampering with, underreporting of med evidence, stonewalling , misleading, attacking victim's credibility, sidetracking **the main issue ongoing crime induced acute kidney pain evolving infection and liver damage**, fabricating made up stories and false incomplete diagnosis based on concealed true med tests results and other unlawful actions and lack of actions reveal not only sinister intent but also deep knowledge and awareness of the true matter at hand- very serious health injury that can lead to fatality if that torture is not stopped soon by the local Law Enforcement.